

## PAPER DETAILS

TITLE: A cutaneous angiosarcoma arising from the rhinophyma

AUTHORS: Serdar DÜZGÜN, İlhan PEKDEMİR, Sedat YILANCI, Yagmur Yaprak BALI, Sinem SINGİN, Mehmet TAPAN

PAGES: 344-347

ORIGINAL PDF URL: <https://dergipark.org.tr/tr/download/article-file/2156108>

# A cutaneous angiosarcoma arising from the rhinophyma

## Rinofima kökenli kütanöz anjiyosarkom

Serdar Düzgün, M.D., İlhan Pekdemir, M.D., Sedat Yılandı, M.D., Yağmur Yaprak Balı, M.D.,  
Sinem Sıngın, M.D., Mehmet Tapan, M.D.

Department of Plastic and Reconstructive Surgery, Ankara Numune Training and Research Hospital, Ankara, Turkey

In this article, we report a 66-year-old male case of rhinophyma who had a persistent lesion on his nose for two-years. Despite steroid therapy, the lesion continued to grow. Histopathological and immunohistochemical findings were consistent with cutaneous angiosarcoma. Rhinophyma-like features should be considered as an unusual clinical manifestation of cutaneous angiosarcoma.

**Key Words:** Angiosarcoma; cutaneous angiosarcoma; rhinophyma.

Bu yazıda burnunda iki yıldır inatçı bir lezyon olan 66 yaşında erkek bir rinofima olgusu sunuldu. Steroid tedavisine rağmen, lezyon büyümeye devam etti. Histopatolojik ve immünohistokimyasal bulgular, kütanöz anjiyosarkom ile uyumluydu. Rinofima benzeri özellikler, kütanöz anjiyosarkomun nadir klinik belirtileri olarak akla getirilmelidir.

**Anahtar Sözcükler:** Anjiyosarkom; kütanöz anjiyosarkom; rinofima.

Rhinophyma is a kind of rosacea that occurs most often in men with thick sebaceous skin.<sup>[1]</sup> It is characterized by patulous follicular orifices, thickened skin and large nodulocystic lesions clustered over the distal half of the nose.<sup>[2]</sup> Patients with rosacea may have complaints about increased sensitivity of the facial skin<sup>[3]</sup> and may have dry, flaking facial dermatitis, edema of the upper face<sup>[4]</sup> or persistent granulomatous papulonodules.<sup>[5]</sup> A rhinophyma lesion can mask the existence of coexisting occult skin cancers and many types of tumors can mimic a rhinophyma.<sup>[6]</sup>

Angiosarcoma is a rare vascular tumor accounting for 2% of soft tissue sarcomas, which together represent less than 1% of all cancers.<sup>[7]</sup> In 60% of cases it arises in skin or superficial soft tissue.<sup>[8]</sup>

Cutaneous angiosarcomas are aggressive neoplasms that mostly arise in three clinical settings: (i) sporadic (involving upper face, scalp and neck of elderly patients (ii) following chronic, persistent lymphedema and (iii) areas previously treated with radiotherapy.<sup>[9-12]</sup> They are clinically characterized by erythematous plaques, macules,



Available online at  
www.kbbihtisas.org  
doi: 10.5606/kbbihtisas.2013.35556  
QR (Quick Response) Code

Received / *Geliş tarihi:* May 14, 2012 Accepted / *Kabul tarihi:* December 13, 2012

*Correspondence / İletişim adresi:* Serdar Düzgün, M.D. Ankara Numune Eğitim ve Araştırma Hastanesi Plastik ve Rekonstrüktif Cerrahi Kliniği, 06100 Altındağ, Ankara, Turkey.

Tel: +90 532 - 643 54 46 e-mail (*e-posta*): serdarduzgun@gmail.com

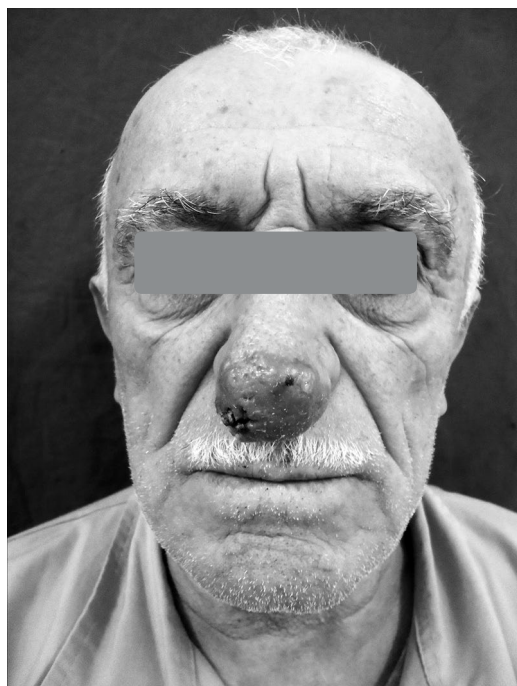


Figure 1. Preoperative image.

nodules and rarely by chronic edema of the face.<sup>[13]</sup> This study is a report of an unusual presentation of facial angiosarcoma arising on rhinophyma.

#### CASE REPORT

A 66-year-old man was referred to our department with a lesion on the nose that had been bleeding and itching for a period of three months (Figure 1). The patient was repeatedly treated for rhinophyma with steroids for three years without improvement. On physical examination, papulonodules and nodulocystic lesions were

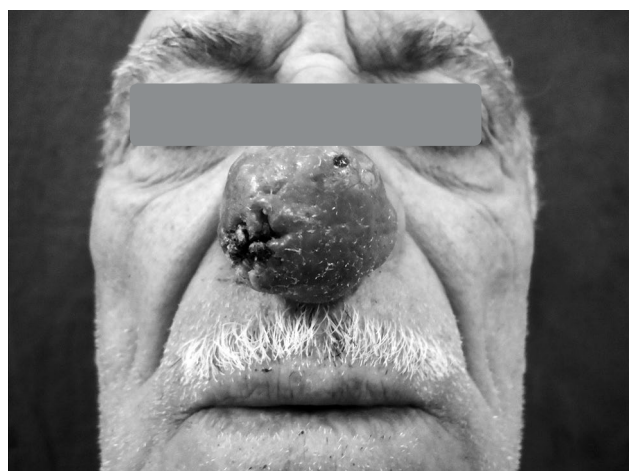


Figure 2. Papulonodules and nodulocystic lesions.

seen on the alar area and dorsal surface of the nose, with a tumoral lesion localized to the tip of the nose and the columella (Figure 2). The patient was operated on under general anesthesia and the tumoral lesion was excised with a 1 cm margin of normal skin. The post-excisional nasal defect was reconstructed with a full thickness skin graft from the supraclavicular area (Figure 3).

Histopathological examination of the lesion showed sebaceous hyperplasia, dilatation of the lymphatic vessels in the upper dermis and atypical proliferation of the endothelial cells in the dermis. Immunohistological studies showed that the tumor cells were positive for CD 34 and CD 31. The diagnosis of cutaneous angiosarcoma was made based on these clinical and histopathological findings. No enlarged regional lymph nodes were detected and there was no sign of extracutaneous illness. Radiation treatment was administered to the lesion site (28 Gy in 10 treatments over 15 days). At the present time, 12 months later, the patient is asymptomatic.

#### DISCUSSION

In 1964 Wilson Jones reported a rare, malignant vascular neoplasm arising in the scalp or face of elderly patients and named it "malignant angioendothelioma." The different variants

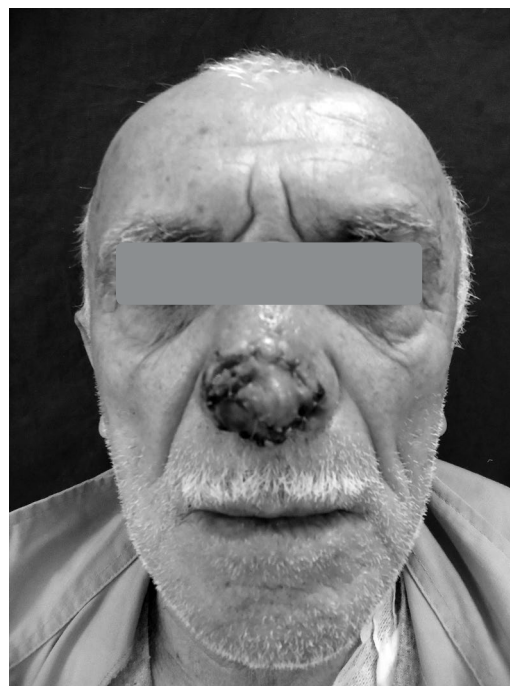


Figure 3. Reconstruction with full thickness skin graft.

of angiosarcoma are classic, associated to lymphedema, and secondary to radiation. The classic cutaneous angiosarcoma of the head and neck region occurs more frequently in elderly male patients (average age: 69 years). It is difficult to implicate solar damage as a cause, although many patients are Caucasians with a long history of solar exposure.<sup>[14]</sup>

About 50% of the lesions are seen in the skin of the head or neck area. Etiology is unknown but some cases are associated with irradiation and chronic lymphedema. Clinical presentation of cutaneous angiosarcoma is mostly enlarging erythematous plaque, colored nodule or non-healing ulceration, rarely unexplained facial edema may be a sign of angiosarcoma.<sup>[15]</sup>

The tumor often mimics different diseases like arteriovenous malformations, lymphoma, nodular melanoma, sarcoidosis or facial granuloma.<sup>[14]</sup>

With regards to prognosis, it should be remembered that angiosarcomas of the face and scalp are aggressive and proliferate easily, having a low survival rate and a five-year mortality higher than 70%.<sup>[16]</sup> They can disseminate locally, recur, or metastasize to the viscera via the lymph vessels or the blood stream, with pulmonary metastases being the most common and the leading cause of death in these patients,<sup>[12]</sup> followed in frequency by metastases to the lymph nodes, soft tissue, bone, and liver. It is important to remember that a sudden onset of marked thrombocytopenia may suggest the rapid growth of the primary tumor or herald the development of metastatic disease. Prognosis bears no relation with sex, localization, histological variety, or mitotic activity, although those lesions of less than 5 cm diameter and those with a prominent lymphocytic infiltrate seem to have a more favorable prognosis. Early diagnosis resulting from clinical suspicion and confirmed by biopsy is of great value. The case reported herein highlights the importance of the histological study of any erythematous enlargement of the skin on the nose, especially when it adopts tumor characteristics.<sup>[17]</sup>

Surgical excision is the first treatment option if it can be performed. For larger tumors, radiotherapy and chemotherapy are the other treatment options. Doxorubicin is the standard chemotherapy agent.<sup>[18,19]</sup>

Similar cases are reported in the literature by Traaholt and Eeg Larsen<sup>[20]</sup> Gallardo et al.,<sup>[17]</sup> Aguila and Sánchez<sup>[14]</sup> and Lo Presti et al.<sup>[13]</sup>

The treatment of choice is wide, local surgical removal<sup>[21]</sup> (although this is only possible in small tumors), combined with electron accelerator radiotherapy. High doses and wide fields are required, as the degree of microscopic invasion of the tumor always spreads beyond what is clinically apparent and recurrences at the periphery of the treated zone are common. Some authors have suggested the possibility of local control of the tumor margins by means of multiple peripheral biopsies or with Mohs' technique, but always followed by electron beam and radiotherapy.<sup>[16]</sup> These considerations make an early diagnosis all the more important in order to improve the poor survival rate of these patients.

In conclusion, this case shows that cutaneous angiosarcoma is a rare but a severe malignancy that can arise on rhinophyma, and should be a considered as a potential diagnosis when we are approaching these patients.

#### Declaration of conflicting interests

The authors declared no conflicts of interest with respect to the authorship and/or publication of this article.

#### Funding

The authors received no financial support for the research and/or authorship of this article.

#### REFERENCES

1. James WD, Berger TG, Elston DM. *Andrews' diseases of the skin: clinical dermatology*. 10th ed. Philadelphia: Saunders Elsevier; 2006. p. 245-8.
2. Pelle MT. Rosacea. In: Wolff K, Goldsmith LA, Katz SI, Gilchrist BA, Paller AS, Leffell DJ, editors. *Fitzpatrick's dermatology in general medicine*. 7th ed. New York: McGraw-Hill; 2008. p. 703-8.
3. Lonne-Rahm SB, Fischer T, Berg M. Stinging and rosacea. *Acta Derm Venereol* 1999;79:460-1.
4. Crawford GH, Pelle MT, James WD. Rosacea: I. Etiology, pathogenesis, and subtype classification. *J Am Acad Dermatol* 2004;51:327-41.
5. Helm KF, Menz J, Gibson LE, Dicken CH. A clinical and histopathologic study of granulomatous rosacea. *J Am Acad Dermatol* 1991;25:1038-43.
6. Powell FC. Clinical practice. Rosacea. *N Engl J Med* 2005;352:793-803.
7. Rich AL, Berman P. Cutaneous angiosarcoma presenting as an unusual facial bruise. *Age Ageing* 2004;33:512-4.

8. Gkalpakiotis S, Arenberger P, Vohradnikova O, Arenbergerova M. Successful radiotherapy of facial angiosarcoma. *Int J Dermatol* 2008;47:1190-2.
9. Leake J, Sheehan MP, Rampling D, Ramani P, Atherton DJ. Angiosarcoma complicating xeroderma pigmentosum. *Histopathology* 1992;21:179-81.
10. De Silva BD, Nawroz I, Doherty VR. Angiosarcoma of the head and neck associated with xeroderma pigmentosum variant. *Br J Dermatol* 1999;141:166-7.
11. Ludolph-Hauser D, Thoma-Greber E, Sander C, Sommerhoff CP, Röcken M. Mast cells in an angiosarcoma complicating xeroderma pigmentosum in a 13-year-old girl. *J Am Acad Dermatol* 2000;43:900-2.
12. Marcon I, Collini P, Casanova M, Meazza C, Ferrari A. Cutaneous angiosarcoma in a patient with xeroderma pigmentosum. *Pediatr Hematol Oncol* 2004;21:23-6.
13. Lo Presti M, Mazzella C, Monfrecola A, Falletti J. Angiosarcoma mimicking rhinophyma. *Dermatol Res Pract* 2010;2010:365173.
14. Aguila LI, Sánchez JL. Angiosarcoma of the face resembling rhinophyma. *J Am Acad Dermatol* 2003;49:530-1.
15. Mentzel T, Kutzner H, Wollina U. Cutaneous angiosarcoma of the face: clinicopathologic and immunohistochemical study of a case resembling rosacea clinically. *J Am Acad Dermatol* 1998;38:837-40.
16. Holden CA, Spittle MF, Wilson Jones E. Angiosarcoma of the face and scalp, prognosis and treatment. *Cancer* 1987;59:1046-57.
17. Gallardo MA, Bosch RJ, Vidal L, Cabra B, Rodrigo AB, De Galvez MV, et al. Angiosarcoma arising on rhinophyma. *Eur J Dermatol* 2000;10:555-8.
18. Verweij J, Mouridsen HT, Nielssen OS, Woll PJ, Somers R, van Oosterom AT, et al. The present state of the art in chemotherapy for soft tissue sarcomas in adults: the EORTC point of view. *Crit Rev Oncol Hematol* 1995;20:193-201.
19. Santoro A, Tursz T, Mouridsen H, Verweij J, Steward W, Somers R, et al. Doxorubicin versus CYVADIC versus doxorubicin plus ifosfamide in first-line treatment of advanced soft tissue sarcomas: a randomized study of the European Organization for Research and Treatment of Cancer Soft Tissue and Bone Sarcoma Group. *J Clin Oncol* 1995;13:1537-45.
20. Traaholt L, Eeg Larsen T. Rhinophyma and angiosarcoma of the nose. A case report. *Scand J Plast Reconstr Surg* 1978;12:81-3.
21. Bullen R, Larson PO, Landeck AE, Nychay S, Snow SN, Hazen P, et al. Angiosarcoma of the head and neck managed by a combination of multiple biopsies to determine tumor margin and radiation therapy. Report of three cases and review of the literature. *Dermatol Surg* 1998;24:1105-10.