

PAPER DETAILS

TITLE: LARGE DENTIGEROUS AND RADICULAR CYSTS OF THE MANDIBLE(CASE REPORT)

AUTHORS: Muzaffer ASLAN,Mutan Hamdi ARAS,Göksel SIMSEK,Ertunç DAYI

PAGES: 54-58

ORIGINAL PDF URL: <https://dergipark.org.tr/tr/download/article-file/27560>

**LARGE DENTIGEROUS AND RADICULAR CYSTS OF THE MANDIBLE
(CASE REPORT)
MANDİBULADA GENİŞ HACİMLİ RADİKÜLER VE DENTİGERÖZ KİST
(VAKA RAPORU)**

Yrd. Doç. Dr. Muzaffer ASLAN*
Yrd. Doç. Dr. Göksel ŞİMŞEK*

Dt. Mutan Hamdi ARAS*
Prof. Dr. Ertuğ DAYI*

SUMMARY

Radicular cysts are inflammatory jaw cysts at the apices of teeth with infected and necrotic pulps. A radicular cyst arises from the epithelial residues in the periodontal ligament as a result of inflammation, usually following death of the pulp. The dentigerous cyst is caused by fluid accumulation between the epithelium and the crown of an unerupted tooth. It grows by expansion of the follicle and is attached to the neck of the tooth. Radicular cyst heals spontaneously after root canal treatment or extraction. Some authors propose that radicular cyst must be totally enucleated surgically to remove all epithelial remnants. The treatment choice for dentigerous and inflammatory follicular cysts is marsupialization, but most reports agree that enucleation of the cyst followed by extraction of involved third molar is recommended. In this article, a case report of radicular and dentigerous cysts and their treatment, and classification of the lesions were discussed in regard to current literature.

Key Words: Radicular cyst, dentigerous cyst, surgical cyst management, cyst/pathology.

ÖZET

Radiküler kistler genellikle nekrotik ve enfekte pulpalı dişlerin apikalinde yer alan inflamatuvar kemik kistleridir. Radiküler kist, pulpa ölümünü takiben oluşan inflamasyonun sonucu olarak gelişen bir kisttir. Dentigeröz kist ise sürmemiş bir dişin kronu ile epiteli arasında sıvı birikmesi sonucu oluşur. Kist dişin boyun kısmına yapışık ve diş folikülünü genişleterek büyür. Radiküler kistler non-vital dişin kanal terapisini veya çekimini takiben kendiliğinden düzelebilir. Bazı otörler kist epitelinin cerrahi olarak tamamen enükleasyonunu ve epitelyal kalıntıların çıkarılmasını önermektedirler. Dentijeröz ve inflamtuvar foliküler kistlerin bir tedavi seçeneği de marsupyalizasyondur, fakat birçok yayında üçüncü molar dişlerin çekimini takiben kistlerin enükleasyonu önerilmektedir. Bu makalede aynı anda radiküler ve dentijeröz kist vakaları bulunan hasta takdim edildi ve bunların tedavi yaklaşımı ile lezyonun sınıflandırılması literatür desteği ile tartışıldı.

Anahtar Kelimeler: Radiküler kist, Dentigeröz kist, Cerrahi kist tedavisi, Kist/patoloji

INTRODUCTION

Odontogenic cysts are probably the most common tissue degrading lesions of the maxillofacial skeleton. These cysts can be broadly divided into developmental and inflammatory types based on their aetiology. The developmental cysts include the primordial cyst, the dentigerous cyst, eruption and gingival cysts. On the other hand inflammatory odontogenic cysts include the radicular cysts and the lateral periodontal cysts.¹

According to the World Health Organization, the jaw cysts of inflammatory origin have one type is; the radicular cysts. Main and Craig proposed that, other variants of inflammatory jaw cyst: the inflammatory collateral cyst and the paradental cyst, respectively² Radicular cysts are inflammatory jaw cysts at the apices of teeth with infected and necrotic pulps.³⁻⁶ These cysts comprise about 52 to 68 % of all the cysts affecting the human jaw.³ It has been shown in recent studies that the radicular cysts comprise between 42 and 44 % of all apical lesions.⁷ Their incidence is highest amongst patients in their third decade of life and male prediction

* Atatürk Üniversitesi, Diş Hekimliği Fakültesi Ağız-Diş Çene Hastalıkları ve Cerrahisi Anabilim Dalı, ERZURUM

is higher than women. Anatomically the apical cysts occur in all tooth-bearing sites of the jaw but are more frequent in maxillary than mandibular teeth.^{3,4}

The dentigerous cyst is caused by fluid accumulation between the epithelium and the crown of an unerupted tooth.⁸⁻¹⁰ These cysts are the second most common odontogenic cysts after radicular cysts. Their frequency in the general population has been estimated at 1.44 cysts for every 100 unerupted teeth.¹⁰ It grows by expansion of the follicle and is attached to the neck of the tooth.⁸ Some of these lesions contain from proliferating of the cell rests of Malassez epithelial.^{3,11} It is believed that epithelial which is derived from the cell rests of Malassez lines the lumen of the dentigerous cysts.³ Dentigerous cysts may cause displacement of adjacent teeth and resorption of teeth roots.¹²

Radicular cysts can heal spontaneously after root canal treatment or extraction. However, some authors propose that suspected radicular cysts must be totally enucleated surgically to remove all epithelial remnants.⁵

The recommended treatment for dentigerous cysts is marsupialization to conserve the permanent tooth.^{2,8}

CASE

A 34 –year-old male was referred to our hospital with the complaint of severity pain at the mandible left molar region, discovered at The Erzurum Çakmak Military Hospital. The patient's medical history has shown that approximately 1 year ago, he had complained of pain from the same region then, he was referred a dental clinic but the treatment was not successful. Additionally there was no trauma history has been noted. Any missing tooth or decayed one has been inspected during the examination. Radiographic examination revealed that radiolucent lesion extended laterally from the distal root of the lower left first molar tooth to the mesial root of the lower left third molar (Figure 1,2,3). Radiographic examination also revealed that another radiolucent lesion associated with the crown of the mandibular left third molar and extended laterally to the incura or sigmoid notch (Figure 1). Both radiolucent lesions were surrounded by a radiopaque margin. The lower left first and second molars showed no response to sensitivity tests carried out with an electric pulp tester. The infected cyst fluid was aspirated. However, no aspiration could be performed from inside the periapical sites of the lower

left first and second molars, since the cortical bone was very thick at this region. Then, the patient underwent surgical treatment at the Department of Oral and Maxillofacial Surgery in Faculty of Dentistry at Ataturk University. Under local anaesthesia, the lesion was totally enucleated with its capsule and wound margins were primary closed (Figure 4). After the operation, histopathological examination revealed that these specimens conformed to cyst epithelial. During one week postoperative period, the patient was advised to have antibiotic and analgesic. On the 7th day sutures were removed. The patient was rescheduled for control. After 4 months the patient was asymptomatic and it was completed that implant and prosthetic treatment at the 6th months (Figure 5-6).

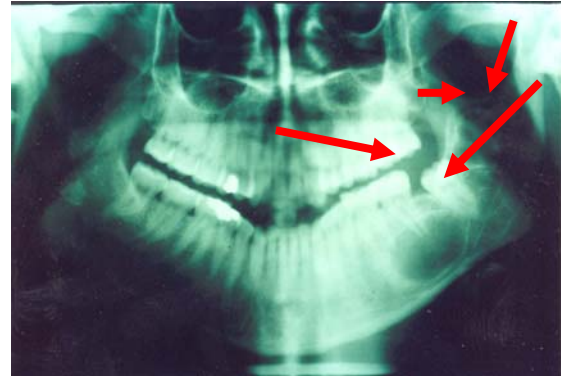


Figure 1

Figure 1: Panoramic radiography of the lesions.

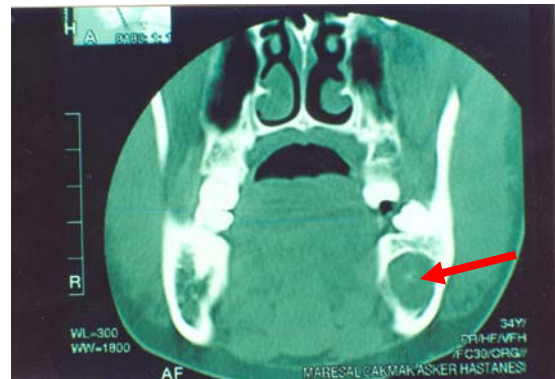


Figure 2: Cross-sectional CT of the mandible.

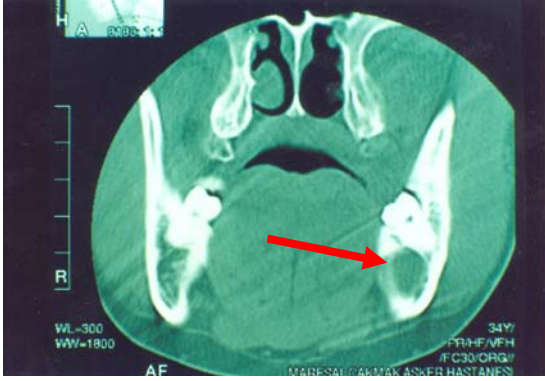

Figure 3: Cross-sectional CT of the mandible.

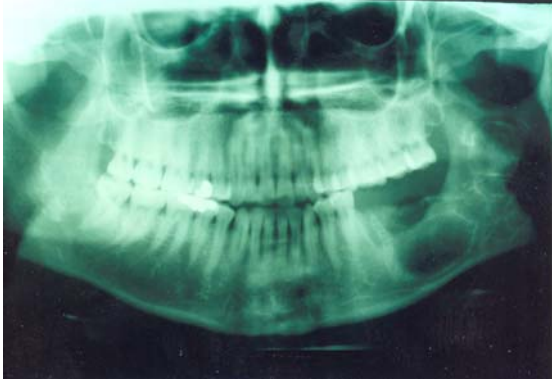


Figure 4: Postoperative panoramic radiography of the site, immediately.

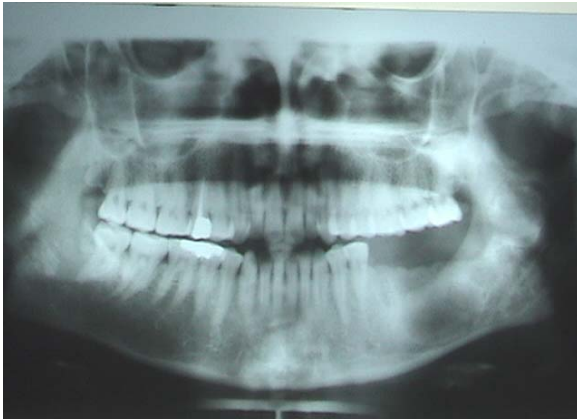

Figure 5: Postoperative panoramic radiography of the site, 4th months.

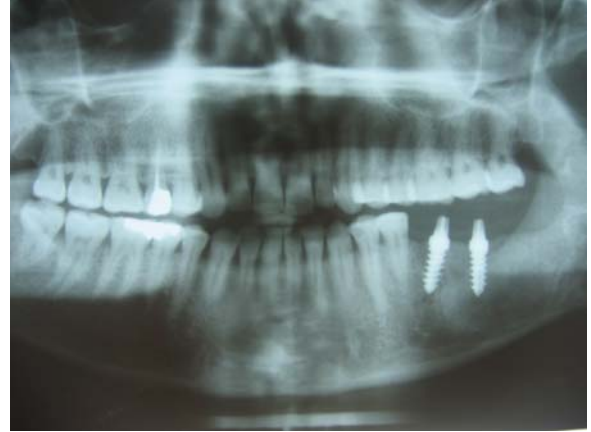

Figure 6: Postoperative panoramic radiography of the site, 6th months.

DISCUSSION

Both radicular cyst and dentigerous cyst are the most common of all jaw cysts.^{4,10,13} On rare occasion, however, both of them were seen on same patient at the same time. We reviewed literature; we could found only one case which both radicular cyst and dentigerous cyst were synchronous seen on same patient.¹⁴

Simon discovered two distinct types of radicular cysts, namely those containing cavities completely enclosed in epithelial lining or true cysts, and those containing epithelium-lined cavities that are open to the root canals.^{3,6,11,15} In our case, because of the cyst associated with lower left first and second molars, the cavity can categorized as apical pocket cyst. The result of histopathological examination was performed after operation was founded that conformed to radicular cyst.

Most radicular cysts develop slowly and do not become very large cavities. Patients do not experience pain unless acute inflammatory exacerbation is present. Large cysts may reason to mobility and not respond to electrical pulp test in affected tooth.¹⁶ In our case, while mobility hadn't been in lower left first and second molars which associated radicular cyst, these teeth couldn't respond to electrical pulp test.

Many clinicians are of the opinion that a great majority of cysts heal after conventional root-filling-therapy.^{3,11,15} A 'success rate' of 85-90% has been recorded by many practitioners.^{3,4,7,11,15} However, the histological status of any apical radiolucent lesion at the time of treatment is known to the clinician and he/she is

unaware of the differential diagnostic status of the 'successful' and 'failed' cases.^{3,11} With small lesions than approximately 1cm in diameter most clinicians would probably opt for conventional endodontics; with larger lesions the debate is more polarized. Moreover, these clinicians suggest that following conventional endodontics it is advisable to wait for 1 year to assess healing, then resort to surgical means if there is little or no resolution.⁴ However, some authors advise that small cyst (<3cm) are usually enucleated, whereas large cysts (>3cm) are often marsupialized.^{6,17} In our case the cyst was enucleated with its capsule and teeth were removed, because the cyst cavity in which our case was infected and it responded to severity pain in this region. Radicular cysts are usually lined with non-keratinizing stratified squamous epithelium.^{7,18,19} The result of histopathological analysis of our case was reported that cyst capsule was lined with squamous epithelium, too.

Dentigerous cysts radiographically show a unilocular, radiolucent lesion characterized by well-defined sclerotic margins and associated with the crown of an unerupted tooth.^{10,19} Benn and Altini reported that 2 types of dentigerous cysts occur. The first is developmental in origin and occurs in mature teeth usually as a result of impaction. These cysts usually occur in the late second and third decades, and predominantly involve mandibular third molars. The second type is inflammatory in origin and occurs in immature teeth as a result of inflammation from a nonvital deciduous tooth follicle. These are diagnosed in the first and early part of the second decade.¹² Our patient was 34-year-old and the cyst was associated with lower left unerupted third molar. So, our case belongs to first group. Dentigerous cysts also part to 2 types as circumferential follicular cyst and lateral follicular cyst. If crown of tooth totally surrounding by cyst, its circumferential; if lateral of crown of tooth surrounding by cyst, its lateral follicular cyst.¹⁹ Our lesion is diagnosed as follicular cyst, because its only status at lateral of the crown of tooth.

Dentigerous cysts are usually detected incidentally during a routine radiographic survey.^{10,19} Shapira et al. reported that in routine full-mouth radiographs of patients over 20 years of age it was found that 37% of impacted mandibular third molars and 15% of impacted maxillary molars exhibited signs of radiolucency around the crowns, 10% of these cases could be classified as cysts.¹⁹

There is usually no pain or discomfort associated with the cyst unless it becomes secondarily infected.¹⁰ But the cyst was infected in presented case. Pain was which thought arising from the cyst and extended laterally toward to ear. The thought that pain rising from this infection.

The recommended treatment for dentigerous cysts is marsupialization, because it is the best way to conserve the permanent tooth.⁸ Marsupialization also must first indicate when there is no likelihood of damaging anatomic structures.¹² However, most reports agree that the treatment of choice is enucleating of the cyst followed by extraction of the associated tooth if the tooth involved is particularly a third molar.² In addition to, must not be forgotten that the major disadvantage of marsupialization is that pathologic tissue is left in situ, without thorough histological examination.¹² Although dentigerous cyst is considered a benign lesion, its epithelial lining has the potential to undergo neoplastic change and development of a squamous cell carcinoma is possible. The tooth was removed, since the cyst was associated with lower left third molar and the patient was over 30-year old.

REFERENCES

1. Chindia ML. Pathogenesis of odontogenic cysts: an update. *East African Medical Journal* 1991; 68(4): 276-282.
2. Lim AA, Peck RH. Bilateral mandibular cyst: Lateral mandibular cyst, paradental cyst, or mandibular infected buccal cyst? Report of a case. *J Oral maxillofac Surg.* 2002; 60 (7): 825-827.
3. Nair P.N.R. Review New perspectives on radicular cysts: do they heal? *International Endodontic Journal* 1998; 31:155-160.
4. Rees JS. Conservative management of a large maxillary cyst. *International Endodontic Journal* 1997; 30: 64-67.
5. Walton RE. The residual radicular cyst: does it exist? *Oral Surg Oral Med Oral Pathol Oral Radiol Endod.* 1996; 82 (5):471.
6. Aslan M, Şimşek G. Large residual dental cyst (A case report). *The Journal of the Dental Faculty of Atatürk University.* 2002; 12(3): 45-49.
7. Bhaskar SN. Nonsurgical resolution of radicular cysts. *Oral Surg.* 1972; 34: 458-468.

8. *Da Silva TA, De Sa AC, Zardo M, Consolaro A, Lara VS. Inflammatory follicular cyst associated with an endodontically treated primary molar: A case report. ASDC J Dent Child 2002; 69(3):271-274.*
9. *Shaw W, Smith M, Hill F. Inflammatory follicular cyst. ASDC J Dent Child 1980; 47(2):97-101.*
10. *Ko KSC, Dover DG, Jordan RCK, Bilateral Dentigerous Cysts - Report of an Unusual Case and Review of the Literature. J Can Dent Assoc 1999; 65: 49-51.*
11. *11.- Nair PNR, Pajarola G, Schroeder HE. Types and incidence of human periapical lesions obtained with extracted teeth. Oral Surg Oral Med Oral Pathol 1996; 81: 93-102.*
12. *Ertas Ü, Yavuz MS. Interesting eruption of 4 teeth associated with a large dentigerous cyst in mandible by only marsupialization J Oral Maxillofac. Surg. 2003; 61: 1-3.*
13. *Takiguchi M, Fujiwara T, Sobue S, Ooshima T. Radicular cyst associated with a primary molar following pulp therapy: A case report Int. J paediatr Dent. 2001; 11(6):452-455.*
14. *Barbieri GB. An unusual case of simultaneous follicular and radicular cysts in the maxilla. Riv Ital Stomatol. 1978; 47(5):24-5.*
15. *Nair PNR, Sjögren U, Schumacher E, Sundqvist G. Radicular cysts affecting a root-filled human tooth: a long term post-treatment follow-up. International Endodontic Journal 1993; 26: 225-233.*
16. *Delbem ACB, Cunha RF, Vieira AEM, Pugliesi DMC. Conservative treatment of a radicular cyst in a 5-year-old child: a case report. International Journal of Paediatric Dentistry 2003; 13: 447-450.*
17. *Bodner L. Spontaneous bone regeneration after enucleation of large mandibular cysts: A radiographic computed analysis of 27 consecutive cases J Oral Maxillofac. Surg. 2000; 58: 949.*
18. *Antoh M, Hasegawa H, Kawakami T, Kage T, Chino T, Eda S. Hyperkeratosis and atypical proliferation appearing in the lining epithelium of a radicular cyst. Report of a case Journal of Cranio-Maxillo-Facial Surgery 1993; 21: 210-213.*
19. *Ludwighausen MC, Schindler G, Matsuura M. Follicular or dentigerous (Tooth-Containing) cyst in the premaxilla of an otherwise edentulous 65-year-old man. Clinical Anatomy 2001; 14: 95-101.*

Yazışma Adresi

Yrd. Doç. Dr. Muzaffer ASLAN

Atatürk Üniversitesi,

Diş Hekimliği Fakültesi

Ağız-Diş Çene Hastalıkları ve Cerrahisi Anabilim Dalı

ERZURUM

Tel : 0.442.2313562

e-mail : drmaslan@yahoo.com