

PAPER DETAILS

TITLE: ROTHETIC AND PERIODONTAL REHABILITATION OF LATE ONSET VARIATION
PAPILLON-LEFEVRE SYNDROME (A CLINICAL REPORT)

AUTHORS: funda BAYINDIR,dtfahri KAVRUT

PAGES: 0-0

ORIGINAL PDF URL: <https://dergipark.org.tr/tr/download/article-file/27660>

ROTHETIC AND PERIODONTAL REHABILITATION OF LATE ONSET VARIATION PAPILLON-LEFEVRE SYNDROME (A CLINICAL REPORT)*

Yard. Doç. Dr. Funda BAYINDIR**

Araş. Gör. Dt Fahri KAVRUT***

GEÇ DÖNEMDEKİ PAPİLLON LEFEVRE SENDROMUNUN PROTETİK VE PERİODONTAL TEDAVİSİ (VAKA RAPORU)*

ÖZET

Papillon Lefevre Sendromu (PLS) otozomal resesif geçişli bir hastalık olarak değerlendirilmektedir. Görülme sıklığı milyonda 1-4 oranındadır. Rapor edilen vakaların 1/3'ünde anne ve baba arasında kan bağı olduğu rapor edilmiştir. Bu vakada Papillon Lefevre sendromlu bir hasta sunulmuştur. Hastanın anne ve babası bu hastalıktan etkilenmemiştir ve birinci derecede kuzen oldukları tespit edilmiştir. Teşhis; anamnez alınarak, klinik, laboratuvar ve radyografik inceleme ile konuldu. Ağız içlerinde, ayak tabanında hiperkeratozis ve ilerlemiş yıkıcı periodontitis varlığı gibi PLS'nin tipik klinik özelliklerini göstermekteydi.

Interdental plağın kaldırılması için profesyonel diş temizliği ve gingival masaj yapıldı. Protetik tedaviden önce hasta kooperasyonu ve periodontal tedavi tamamlandı. Hareketli bir parsiyel protez planlandı. Hastamız protezlerini 3 yıldır rahat bir şekilde kullanmaktadır.

Anahtar kelimeler: Papillon Lefevre sendromu, palmar plantar hiperkeratozis.

SUMMARY

Papillon Lefevre syndrome (PLS) is considered to be transmitted as an autosomal recessive trait. The syndrome is estimated to have frequency of 1 to 4 million. Consanguinity between parents was reported in one-third of cases studies. In this case a Papillon-Lefevre Syndrome (PLS) is presented. Patient is the product of a first cousin marriage their parents were not affected. Diagnosis was determined by history and clinical laboratory and radiographic examinations. Patient exhibited the typical clinical features of PLS: hyperkeratosis of the palms and soles and the presence of advanced destructive periodontitis.

Professional tooth cleaning for the removal of interdental plaque and gingival massage were made the patient cooperation and the periodontal therapy was completed before prosthetic rehabilitation. A removable partial denture was planned. She has been used denture comfortably for three years.

Key Words: Papillon Lefevre Syndrome: Palmar plantar hyperkeratosis.

INTRODUCTION

In 1924 Papillon and Lefevre first described a syndrome characterized by hyperkeratosis of the palms and soles combined with precocious periodontal destruction and shedding of the deciduous and permanent dentition.¹

The deciduous dentition is normal in development and age of eruption. As soon as the lost deciduous tooth has erupted, several features are seen; swollen gingiva, migration and mobility teeth, periodontal pockets, fetor exoris and exfoliation in a rather painless sequence.² With loss of the deciduous teeth, inflammation

*Presented at the 7 th Congress of The Balkan Stomatological Society (BaSS) Kuşadası /TURKEY, 28-30 March 2002.

**Atatürk Üniversitesi Diş Hekimliği fakültesi, Protetik diş tedavisi anabilim dalı

***Atatürk Üniversitesi Diş Hekimliği fakültesi, Periodontoloji anabilim dalı, ERZURUM

regresses and the gingival resume a normal appearance some of the features resemble Juvenile periodontitis. The eruption of the permanent teeth is enhanced and may even be completed by 5 years of age (except the third molars). The extracted teeth generally show few hard and soft deposits.²

Most of deciduous teeth are lost by the age of 4 years, and permanent teeth are lost by the age 16.³ Skin lesions tend to appear between the ages of 2 and 4 years. The soles are usually affected more severely than the palms. The durameter may be calcified as may the tentorium or choroid.³ Its etiology remains obscure, but it is accepted that it is transmitted through an autosomal recessive gene.⁴ Findings indicate a possible link between a genetic defect in chemotaxis of neutrophils and periodontal infection of variant microorganisms.⁵ Diagnosis is determined by history, clinical, laboratory, and radiological examination.⁵

The Papillon Lefevre Syndrome appears in child had and adolescence 5-24 however, a late one set variation of the disease has been reported. The present case of PLS exhibited the typical clinical feature of the condition hyperkeratosis of the palms and soles and periodontal lesions.

CLINICAL REPORT

33 years old women presented Atatürk University, Dentistry Faculty in February 1999 for comprehensive dental treatment. The patient has no history of any major illness of increased susceptibility to infection. Her mental abilities and intelligence were normal. Her parents, brother and sister have no general health

problems-her parents were blood relatives (first cousin). The heights (in cm) were 145 and the weights (in kg) were 49.

The 11, 13, 21, 41 teeth had been extracted when the patients presented to dental faculty. The other anterior teeth, 34 and 44 were extracted because of excess teeth mobility (Fig 1). The first clinical examination of the patient revealed extensive gingival inflammation, profound bleeding, deep periodontal pockets and extensive loss of periodontal tissue support. The hyperkeratosis arose on her palms, soles, knees and elbows (Fig 2-4). The skin lesions on the knees were well-demarcated plaques or patches, while the lesion on the palms were of a diffused pattern. She has mobile teeth and strong halitosis. Her oral hygiene was poor and the gingiva was generally red and swollen. Alkaline phosphate, T3, T4, levels, urine alysis, complete blood count, serum calcium phosphate values were normal. No ectopic intracoronal calcifications were detected radiographic examination (panoramic and periapical views) confirmed alveolar bone loss around all teeth (Fig. 5).

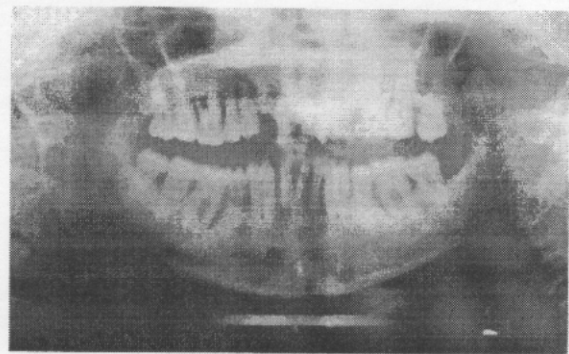


Figure 1. The first panoramic radiografi of patient.

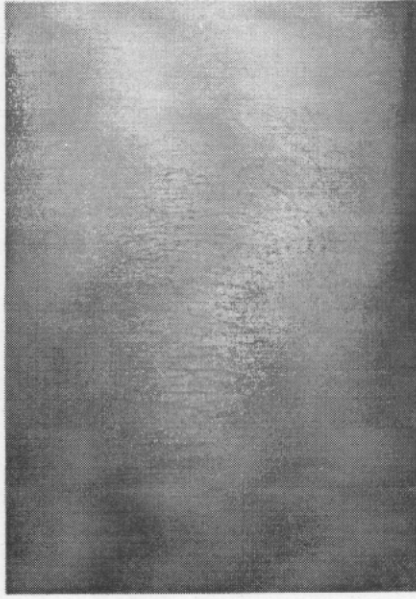

Figure 2. Hyperkerotic lesion over the skin of knees.

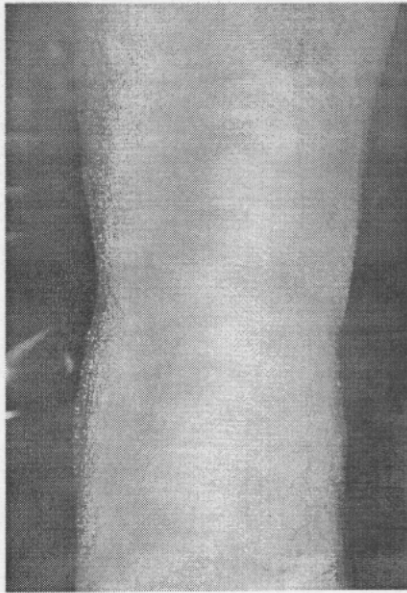


Figure 3. Hyperkerototic lesion the back side of knees.

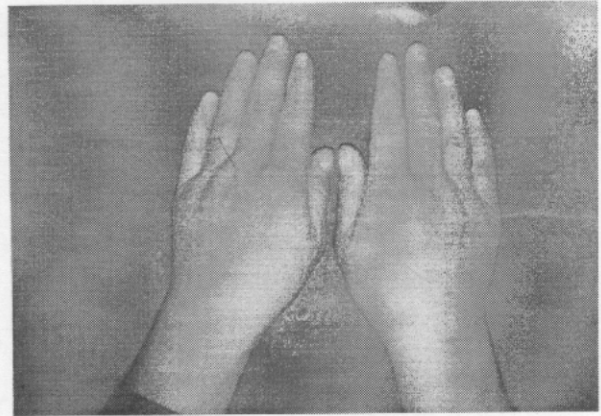


Figure 4. Diffuse hyperkeratotic lesion dorsal aspects of hands.

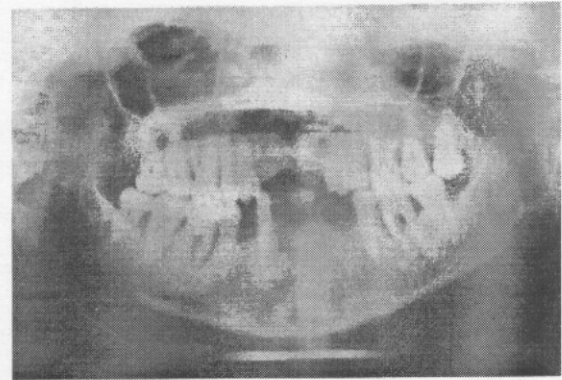


Figure 5. Intermediate panoramic radiografi of patient.

The microbial sampling revealed a mixed bacterial flora with predominance of *actinobacillus actinomycetemcomitans*, *capnocytophaga*, *F.nucleotum*, *streptococcus sangius*, *porphyromonas gingivalis* and *E.corodans* species.

Diagnosis was determined by history, clinical, laboratory and radiographic examination.

Periodontal therapy was started, clinical measurements were made such as supragingival plaque, probing depth and bleeding on probing.

Professional tooth cleaning aimed at the removal of interdental plaque and using gingival massage however we obtained good results in the preservation of the remain teeth.

The patient cooperation and the periodontal therapy were completed before prosthetic rehabilitation.

Preliminary impressions of a patient's mouth were obtained in stock impression trays. The resulting study casts were needed for planning treatment, including the designing of partial dentures and for the construction of individual trays, which were used to obtain the more accurate, working impressions required for the construction of the partial dentures.

She has a single edentulous area located anterior to remaining natural teeth both arches (Kennedy Class IV).

The planning of partial denture were used a surveyor for measure the extent of horizontal undercuts.

For the lower jaw connector the lingual plate and U shape palatal plate were made for the upper jaw connector (Fig. 6).

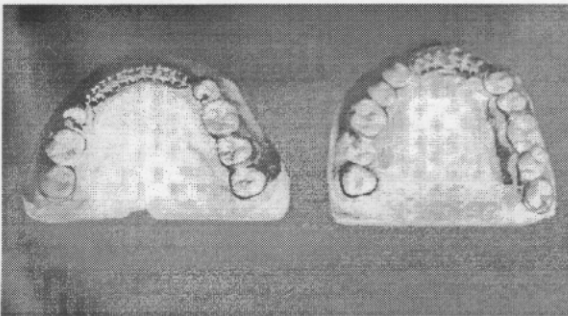


Figure 6. The lower and upper jaw frome works.

The retentive clasp were located with great core so that the benefits of indirect retention.

Indirect retention has been achieved by placing the rest on 18 and 28 as for posteriorly as possible. The patient have sufficient teeth may be present to enable the casts to be placed together accurately in a stable intercuspal position at the desired vertical and horizontal jaw relations. The anterior teeth arrangement were completed the positioning contour of papilla and gingival margins around the artificial teeth were harmonized with those of the adjacent naturally teeth before denture finishing. The completed denture were inserted her mouth and routine oral review appointments were performed (Fig 7).

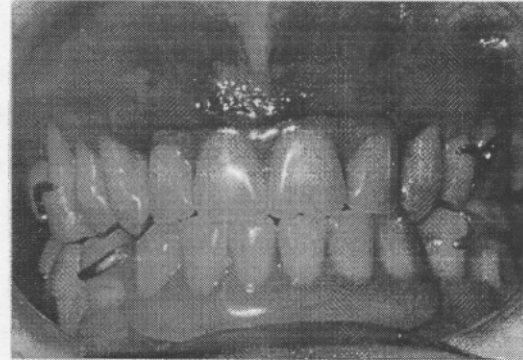


Figure 7. Oral view of completed removable partial denture.

DISCUSSION

In this case, a 33-year female with Papillon-Lefevre Syndrome was rehabilitated both periodontally and prosthodontically.

A prevalence of PLS in general population of 1 to 4 Per million, males and females are equally effected.¹⁵

A review of features of PLS show that the skin lesions appear when the child starts crawling and moving about, that is, when the skin is subjected to pressure. The periodontal destruction also occur soon after the teeth erupt. Once the teeth exfoliate and the occlusal forces are eliminated, the tissues return to normal. This suggests an adverse reaction to pressure, or a premature aging on the part of some structural component of the skin and the periodontium.⁷ The skin of the soles was more severally affected than that of the palms.⁹

A pathogenesis of PLS remains unclear. While further investigations of plaque flora and possible defects in host defences are indicated, additional studies of the developing gingival lesions are needed to determine whether any epithelial abnormality is present which may impair local resistance to dental plaque.⁴

PLS specific profile of the subgingival infection, since the bacterial composition of the sampled sites closely resembled that characterising deep pockets in adult periodontitis patients.⁶

Preus¹⁶ speculated that the hereditary defect in PLS is located at the epithelial surface barrier. An epithelial defect may lead to reduced defence against virulent periodontopathic organisms, resulting in severe periodontal destruction.

Actinobacillus actinomycetemcomitans has also been reported to be a major periodontal pathogen in PLS patients.¹⁶⁻¹⁹

In one case, a patient who had an aggressive form of marginal periodontitis with total tooth loss at the age of 41 presented. Since *A. actinomycetemcomitans* did not colonise the oral mucous membranes in denture wearing subjects and. Gingival to a minor extent, the oral

cavity of edentulous subjects may not be regarded.²⁰

Most of case reports conventional periodontal treatments for a patient with Papillon-Lefevre Syndrome do not succeed in the preservation of permanent teeth.^{8, 17, 21, 22}

Brown et al.⁵ presented three unusual cases of PLS. In one of their case, because of the severe periodontal disease the patient was treatment planned for full mouth extraction and complete denture.

However, Preus and Gjermo²³ reported successful treatment of periodontal components of the PLS in 2 siblings. In present case periodontal and prosthetic treatment had been completed successfully. Any periodontal disease did not develop over a three-year observation.

Kim et al.¹⁰ showed that regular professional tooth cleaning could preserve permanent teeth in a Papillon-Lefevre syndrome patient with little medication.

Dentist plays a significant role in the diagnosis and management of PLS patients.⁹

The pathogenesis of Papillon-Lefevre syndrome remains unclear while further investigations of plaque flora and possible defects in host defence are indicated. Additional studies of the developing, gingival lesions are needed to determine whether any epithelial abnormality is present which may impair local resistance to dental plaque.⁴

CONCLUSION

A Papillon-Lefevre Syndrome was presented which both the periodontal and palmar plantar lesions of late onset in this case; oral function, phonation and aesthetics were supplied

with prosthetic rehabilitation after the conventional periodontal treatment was completed.

The case has been followed, she has been used denture comfortably and she did not develop periodontal disease over a three-year observation period when improved oral hygiene and professional tooth cleaning were instituted.

REFERENCES

1. Papillon MM and Lefevre P. Deux cas de keratodermie palmaire et plantaire symétrique familiale (maladie de meleda) chez le frère et la sœur. Coexistence dans les deux cas d'altérations dentaires graves. Bull Soc Fr Dermatol Syphiligr 1924 31: 82.
2. Carvel RI. Palmo-plantar hyper keratosis and premature periodontal destruction. J Oral Med 1969 24: 73-82.
3. Scully C, Flint SR, Porter SR. Oral diseases. Second edition Martin Dunitz. 186.
4. Sloan P, Soames JV, Murray JJ, Jenkins MM. Histopathological and ultrastructural findings in a case of Papillon-Lefevre Syndrome. J Periodontol 1984; 482-484.
5. Brown RS, Hays GL, Flaitz CM, O'Neill AP, Abromowitchk White RR. A possible Late onset variation of Papillon-Lefevre Syndrome: Report of 3 cases. J Periodontol 1993 64: 379-386.
6. Lundgren T, Renverts S, Papapanou PN, Dahlen G. Subgingival microbial profile of papillon-Lefevre patients assessed by DNA-probes. J Clin Periodontol 1998 25: 624-629.
7. Paghdwala AF. Papillon-Lefevre Syndrome. A case report. J Clin Periodontol 1998 51: 594-598.
8. Glenwright HD, Rock WP. Papillon-Lefevre Syndrome. A discussion aetiology and case report. Br Dent J 1990 168: 27-29.
9. Hattab FN, Rawashdeh MA, Yassin OM, Almomani AS, Al-Ubasi MM. Papillon-Lefevre syndrome: A review of the literature and report of 4 cases. J Periodontol 1995 66: 413-420.
10. Kim JB, Marito M, Kusumoto M, Watanabe T, Takagi S, Nishijima K. Preservation of permanent teeth in a patient with Papillon-Lefevre Syndrome by professional tooth-cleaning. J Dent Child 1997 May-June: 222-226.
11. Fardal O, Drangsholt E, Olsen I. Palmar plantar keratosis and unusual periodontal findings. J Clin Periodontol 1998 25: 181-184.
12. Kellum RE. Papillon-Lefevre Syndrome in four siblings treated with etretinate a nine year evaluation. Int J Dermatol 1989 28(9): 605-608.
13. Joshi HN, Dogal PK, Kansagra PJ. Papillon-Lefevre Syndrome: report of case. J Dent Child 1985 Nov-Dec: 461-463.
14. Orbak Z, Orbak R, Tezel A, Çanakçı V. Papillon-Lefevre Syndrome (A case report). Atatürk Univ Dış Hek Fak Derg 1999 9: 74-77.
15. Hurwitz S. Clinical pediatric dermatology. 2nd ed, pp 164-191. Philadelphia: WB Saunders, 1993.
16. Preus HR. Rapidly destructive periodontitis of Papillon-Lefevre Syndrome result of treatment based on laboratory and clinical observations of 2 cases. J Clin Periodontol 1988 15: 639-643.

17. Bimstein E, Lustmann J, Sela MN et al. Periodontitis associated with Papillon-Lefevre Syndrome. J Periodontol 1990 61: 373-377.
18. Eronat N, Uçar F, Kılınc G. Papillon-Lefevre Syndrome: treatment of two cases with a clinical and microbiological investigation. J Clin Pediatric Dent 1993 17: 99-104.
19. Ishikawa I, Umeda M, Laorin N. Clinical bacteriological and immunological examinations and the treatment process of two Papillon-Lefevre Syndrome patients. J Periodontol 1994 65: 364-371.
20. Danser MM, Van Win Kelhoff AJ, de Groff J, Vander Velden U. Putative periodontal pathogens colonize oral mucous membranes in denture-wear subjects with a post history of periodontitis. J Clin Periodontol 1995 22: 854-859.
21. Hathway R. Papillon-Lefevre Syndrome. Br Dent J 1982 153: 370-371.
22. Rateitschak-Pluss EM, Schroeder HE. History of periodontitis in a child with Papillon-Lefevre Syndrome. A case report. J Periodontol 1983 55: 35-46.
23. Preus H, Gjermo P. Clinical management of prepubertal periodontitis in 2 siblings with Papillon-Lefevre syndrome. J Clin Periodontol 1987 14: 156-160
- Yazışma adresi:**
Dr. Funda BAYINDIR
Atatürk Üniversitesi
Diş Hekimliği Fakültesi
Protetik Diş Tedavisi Anabilim Dalı
Tel: 0 442 2311683
e- mail: ybay@atauni.edu.tr.