


PAPER DETAILS

TITLE: GENÇ ERİSKİNDE BİLATERAL KORONOID HİPERPLAZİSİNE BAĞLI TRİSMUS: VAKA RAPORU

AUTHORS: Fatih TASKESEN,Cem ÜNGÖR,Hamza DAYISOYLU,Figen ÇİZMECİ SENEL

PAGES: 93-97

ORIGINAL PDF URL: <https://dergipark.org.tr/tr/download/article-file/28054>



TRISMUS DUE TO BILATERAL CORONOID HYPERPLASIA IN AN ADOLESCENT: A CASE REPORT

GENÇ ERİŞKİNDE BİLATERAL KORONOID HİPERPLAZİSİNE BAĞLI TRİSMUS: VAKA RAPORU

Dt. Fatih TAŞKESEN*

Dr. Ezher Hamza DAYISOYLU**

Doç. Dr. Cem ÜNGÖR*

Prof. Dr. Figen CİZMECİ ŞENEL*

Makale Kodu/Article code: 1251

Makale Gönderilme tarihi: 01.08.2013

Kabul Tarihi: 21.10.2013

ABSTRACT

Hyperplasia of the bilateral coronoid processes causes limitation of mouth opening due to impingement of coronoid process with the temporal surface of the zygomatic bone, or with the medial surface of the zygomatic arch. The condition can be diagnosed by panoramic radiographs or with computerized tomography scans. In this case report, trismus due to bilateral coronoid process hyperplasia in a 15-year-old boy treated with intraoral coronoidectomy and physiotherapy was presented.

Keywords: Coronoid hyperplasia, trismus, coronoid process, coronoidectomy

ÖZET

Bilateral koronoid hiperplazisi, koronoid çıkıntılarının zigomatik kemiğin temporal yüzeyine uzanması ile birlikte ağız açıklığında kısıtlılığa neden olur. Bu durum, panoramik radyografiler ya da bilgisayarlı tomografi kesitlerinde tespit edilebilir. Bu vaka raporunda, bilateral koronoid hiperplazisi nedeniyle trismus bulunan 15 yaşındaki erkek çocuğun intraoral koronoidektomi ve fizyoterapi ile tedavisi sunulmaktadır.

Anahtar sözcükler: Koronoid hiperplazi, trismus, koronoid çıkıntı, koronoidektomi

INTRODUCTION

Coronoid process hyperplasia (CPH) is defined as an abnormal elongation of the mandibular coronoid process consisting of histologically normal bone.¹⁻³ Coronoid process enlargement was first described by Langenbeck in 1853 and since then, many new reports have been published about this subject.^{2,4,5} Hyperplasia of the bilateral coronoid processes causes painless, limited mouth opening as a result of the impingement of the enlarged coronoid process to temporal surface of the zygomatic bone or to the medial surface of zygomatic arch.^{2,4,6,7}

In CPH cases, the clinical symptoms often mimics the signs of temporomandibular joint disorders (TMD) hence it can be misdiagnosed as TMD.^{4,7} CPH can be detected on panoramic radiography however three-dimensional computerized tomography (3D-CT) demonstrates the relation of coronoid process and the zygomatic arch.⁷

Coronoidectomy is the primary treatment for coronoid hyperplasia. Postoperative physiotherapy is mandatory to achieve satisfactory long-term results.²

This report presents a case of bilateral coronoid process hyperplasia in a 15-year-old boy was treated by intraoral coronoidectomy and physiotherapy.

CASE REPORT

A 15-year-old boy was referred to Karadeniz Technical University Department of Oral and Maxillofacial Surgery Clinic by Department of Orthodontics with a history of limitation of mouth opening. His medical history presented multiple immature organs as liver and lungs. He was under observation of pediatriits since he was born. His family noticed the restricted mouth opening since he was 5 years old. They stated this situation to his doctors for several times and his pediatriits did not consultate him to any specialist. He was referred to our hospital

*Karadeniz Technical University, Faculty of Dentistry Department of Oral and Maxillofacial Surgery

**Baskent University Faculty of Dentistry, Department of Oral and Maxillofacial Surgery



by his dentist for orthodontic treatment. The patient had no history of maxillofacial trauma.

On physical examination, there was no evidence of facial asymmetry. The maximum mouth opening was calculated as only 21 mm (Figure-1). Left and right excursions of mandible were also limited and mandible presented no protrusive movement. The patient had a retrognathic mandible in cephalographic examination and his occlusion was Class II according to Angle Classification (Figure-2). On initial examination, this case was evaluated as a temporomandibular joint (TMJ) disorder. He had no pain or tenderness over TMJs and masticator muscles. The attempt to open his mouth by stretching TMJ under deep sedation was unsuccessful. Magnetic resonans imaging (MRI) and computed tomography (CT) scans were obtained to analyse TMJ. No disc dislocation or sign of other internal derangements were observed on MRI scan. On the CT scans, there was no evidence of bony or fibrous ankylosis of the TMJ. The previous panoramic radiograph was examined again and bilateral elongation of coronoid processes was noticed (Figure-3). 3D-CT scans were taken to confirm the diagnosis (Figure-4,5,6).

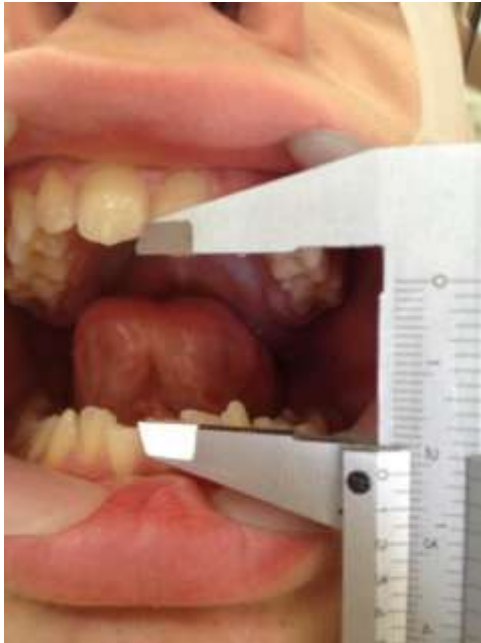

Figure 1. Preoperative maximum mouth opening.

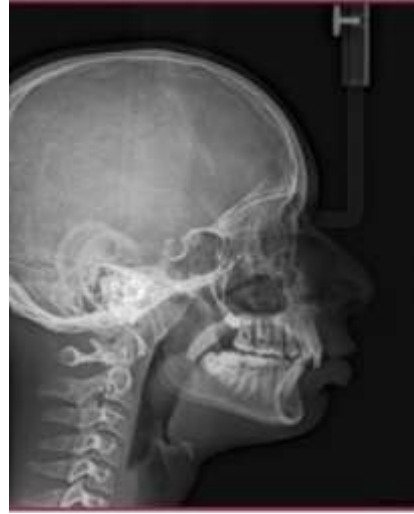

Figure 2. Cephalometric radiography

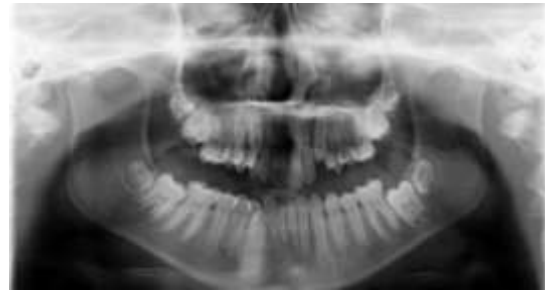


Figure 3. Preoperative panoramic radiography.

The patient underwent bilateral coronoidectomies under general anesthesia. He was taken to the operating room and anesthesia was induced following a nasotracheal intubation. Incision was made on the anterior aspect of ascending ramus and extended anteriorly to the second molar. Ascending ramus was exposed up to the top of the coronoid process. The temporalis muscle was then detached from the coronoid process, and a horizontal osteotomy was made with a Lindemann drill from the sigmoid notch to the anterior border of the ascending ramus. The coronoid process was excised. After right coronoidectomy was completed, the maximum mouth opening was 28 mm. The same procedure was performed on the left side afterwards. At the end of the operation the interincisal distance was 31 mm. Postoperatively the patient was examined by panoramic radiography (Figure-7). From the fifth postoperative day, the patient underwent physiotherapy using tongue blades 3 times a week for

three months. Follow up with mobilization exercises for 11 months postoperatively revealed an interincisal opening of 36 mm with 4mm and 5 mm left and right excursion, respectively without pain or lateral deviation (Figure-8). Protrusive movement was observed nearly 3 mm. Also mastication and phonation of the patient were improved.

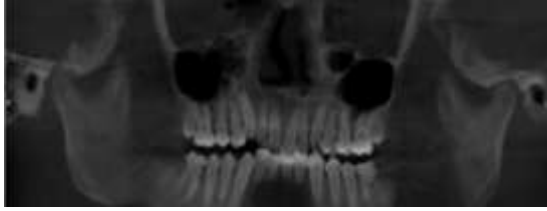

Figure 4. Panoramic view of CT scan.

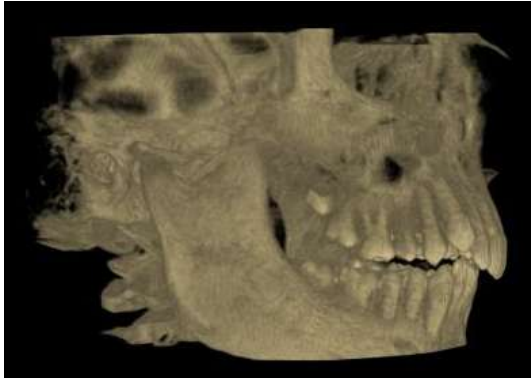


Figure 5. 3D-CT scan of right side.

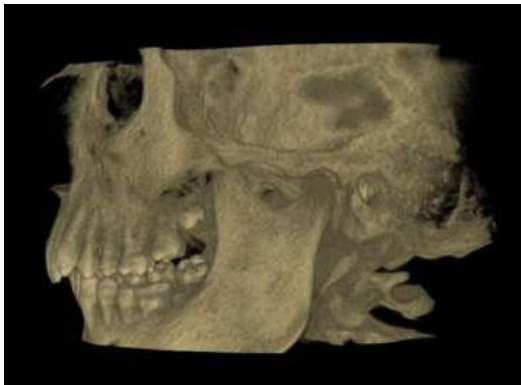


Figure 6. 3D-CT scan of left side.

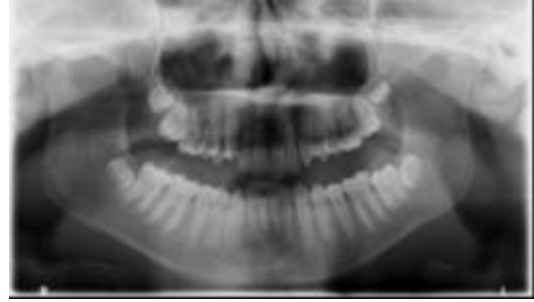

Figure 7. Postoperative panoramic radiography.

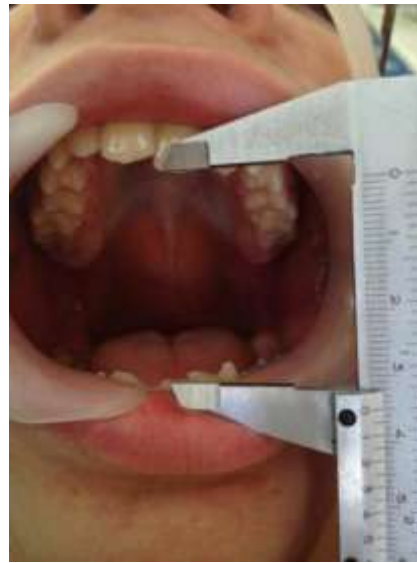

Figure 8. Postoperative maximum mouth opening

DISCUSSION

Mouth opening can be restricted by various factors. Oral cancer itself and surgery for oral cancer, irradiation therapy to head and neck, zygomatic bone fractures and infections and also TMJ disorders are the common causes.⁴

Bilateral hyperplasia of the coronoid processes presents progressive development and results in limited opening of the mouth due to mechanical impingement of an enlarged coronoid process on the posterior aspect of the zygomatic bone or on zygomatic arches.⁵ In many cases, patients don't complain of their restricted mouth opening since the limitation is not painful.⁸ Coronoid processes can elongate due to only a pure hyperplasia of the bony structure or can elongate by formation of a

osteochondroma. The term "Coronoid Hyperplasia" defines just hyperplastic enlargement of coronoid processes and was first described by Langenbeck in 1853.^{2,4} The joint formation between an osteochondroma of the coronoid process and the zygomatic arch was first described by JACOB in 1899 and was termed as Jacob disease in the literature.

According to McLoughlin³ and his co-workers review, bilateral coronoid hyperplasia predominantly affects men. Men/women incidence ratio was found 5/1. The average diagnosis age was 25. Another review reported by Mulder et al¹ including the cases after McLoughlin's work, from 1995 to 2011 states the male-female ratio: 3.3/1 and the mean diagnosis age as 23 similar with McLoughlin's results. In this case the patient was diagnosed as coronoid hyperplasia while he was 15 years old.

The cause of coronoid hyperplasia remains unclear. Various theories have been suggested for the aetiology of CPH including endocrine stimulus, increased temporalis muscle activity, genetic inheritance, trauma, mandibular hypomobility, TMJ disorders and recently ankylosing spondylitis (AS). Isberg et al⁹ proposed that mandibular hypomobility and temporalis muscle hyperactivity can be the cause of coronoid elongation from their animal study on monkeys. Similarly in another study the thick collagen fibers has been shown by electron microscopy in the temporalis muscle in patients with coronoid hyperplasia however Gerbino et al¹⁰ analyzed 5 patients with coronoid hyperplasia with normal temporalis electromyography findings. Though there are some cases supporting mandibular hypomobility theory the precise aetiologoy and pathophysiology of coronoid hyperplasia remains unclear. In this case, history of the patient revealed no obvious cause for the disorder.

Coronoid hyperplasia cases are commonly misdiagnosed as TMJ disorders. A history of progressive, painless restriction of mouth opening is crucial to differentiate the diagnosis of TMJ disorders. In clinical examination, a painless TMJ palpation can lead the clinican to exact diagnosis. In present case this patient was evaluated as TMJ disorder initially. Panoramic radiography can demonstrate the elongation of the coronoid process however a 3D-CT gives the precise information about the relationship with coronoid process and zygomatic bone or the arch

and the exact location of impingement while mouth is open. Moreover CT imaging is useful in differential diagnosis between CPH and other coronoid abnormalities such as osteochondroma.¹

The treatment of CPH to obtain the necessary mouth opening is surgical. Two types of surgical methods have been used: coronoidectomy or coronoidotomy.^{1,8} The intra-oral approach to remove the hyperplastic coronoid process is usually preferred. The intraoral approach eliminates skin scar, however fibrotic organisation of postoperative haematoma can be a risk for trismus and can cause limited succes in mouth opening.^{1,4} Gerbino et al¹⁰ performed coronoidotomy in 5 cases of CPH with satisfactory results and they stated that coronoidotomy can cause less fibrosis. Chen et al¹¹ used a modified technique as gap coronoidotomy. According to them in conventional coronoidotomy the displacement of coronoid process can not be enough therefore coronoid process may interfere with the ascending ramus. In a recent study, Robiony et al¹² introduced endoscopically assisted intraoral coronoidectomy. In this case, we prefered intraoral coronoidectomy to overcome this disorder.

Postoperative physiotherapy is mandatory to avoid unsatisfactory results.^{3,8} Immediate physical therapy is recommended to prevent fibrosis. Van Hoof and Bessling¹³ recommended physiotherapy at approximately 1 week postoperatively. However there were no guidelines on duration and frequency of the exercises. According to Gerbino et al physiotherapy must be continued for at least 12 months. In our case, mouth-opening exercises were initiated 5 days after surgery and continued for 6 months postoperatively.

The use of the computed tomography to diagnose a hyperplasia in the mandible is very essential. Tatlı et al¹⁴ were used cone-beam computed tomography to determine condylar hyperplasia in 2 cases. In this study, CT was applied to the patient for radiological examination and this procedure was helped in the diagnosis of the disease.

Unsatisfactory results after surgical treatment seem to be frequent so that commonly termed as 'disappointing' in the literature. The relaps in mouth opening after coronoidectomy may be caused by subsequent fibrosis in many cases however regrowth of coronoid process has been reported in literature.³ In our 12 months follow up period, no decrease in maximal mouth opening was observed. According to

the AAOMS impairment guidelines a MMO of 35 mm or more was considered to be an acceptable interincisal distance and we obtained a satisfactory result with 38 mm at the end of the 12 months follow up period.

In the presented case, the boy suffered from restricted mouth opening for at least 10 years. Although his family was aware of the restricted mouth opening for a long time, his pediatricists did not care about the situation and did not refer to any specialist. Our initial diagnosis was on TMJ disorder. After stretching the mandible did not lead success we evaluated the panoramic radiography again and noticed the elongated coronoid processes.

In conclusion, since elongated coronoid process is a rare cause of restricted mouth opening, clinicians must consider CPH in initial diagnosis at the limitation of interincisal distance cases. The knowledge about CPH will lead clinician to differentiate TMJ disorders from these cases and find the exact diagnosis.

REFERENCES

1. Mulder CH, Kalaykova SI, Gortzak RA. Coronoid process hyperplasia: a systematic review of the literature from 1995. *Int J Oral Maxillofac Surg* 2012;41: 1483-9.
2. Wenghoefer M, Martini M, Allam JP, Novak N, Reich R, Bergé SJ. Hyperplasia of the coronoid process in patients with ankylosing spondylitis (Bechterew disease). *J Craniofac Surg* 2008;19: 1114-8.
3. McLoughlin PM, Hopper C, Bowley NB. Hyperplasia of the mandibular coronoid process: an analysis of 31 cases and a review of the literature. *J Oral Maxillofac Surg* 1995;53: 250-5.
4. Tavassol F, Spalthoff S, Essig H, Bredt M, Gellrich NC, Kokemüller H. Elongated coronoid process: CT-based quantitative analysis of the coronoid process and review of literature. *Int J Oral Maxillofac Surg* 2012;41: 331-8.
5. Fabié L, Boutault F, Gas C, Paoli JR. Neonatal bilateral idiopathic hyperplasia of the coronoid processes: case report. *J Oral Maxillofac Surg* 2002;60: 459-62.
6. Mano T, Ueyama Y, Koyama T, Nishiyama A, Matsumura T. Trismus due to bilateral coronoid hyperplasia in a child: case report. *J Oral Maxillofac Surg* 2005;63: 399-401.
7. Zhong SC, Xu ZJ, Zhang ZG, Zheng YH, Li TX, Su K. Bilateral coronoid hyperplasia (Jacob disease on right and elongation on left): report of a case and literature review. *Oral Surg Oral Med Oral Pathol Oral Radiol Endod.* 2009;107: 64-7.
8. Satoh K, Ohno S, Aizawa T, Imamura M, Mizutani H. Bilateral coronoid hyperplasia in an adolescent: report of a case and review of the literature. *J Oral Maxillofac Surg* 2006;64: 334-8.
9. Isberg AM, McNamara Jr JA, Carlson DS, Isacsson G. Coronoid process elongation in rhesus monkeys (*Macaca mulatta*) after experimentally induced mandibular hypomobility. *Oral Surg Oral Med Oral Pathol* 1990;70: 704-10.
10. Gerbino G, Bianchi SD, Bernardi M. Hyperplasia of the mandibular coronoid process: Long-term follow-up after coronoidotomy. *J Craniomaxillofac Surg* 1997;25: 169.
11. Chen CM, Chen CM, Ho CM, Huang IY. Gap coronoidotomy for management of coronoid process hyperplasia of the mandible. *Oral Surg Oral Med Oral Pathol Oral Radiol Endod* 2011;112: 1-4.
12. Robiony M, Casadei M, Costa F. Minimally invasive surgery for coronoid hyperplasia: endoscopically assisted intraoral coronoidectomy. *J Craniofac Surg* 2012;23: 1838-40.
13. Van Hoof RF, Besling WFJ. Coronoid process enlargement. *Br J Oral Surg* 1973;10: 339.
14. Tatlı U, Keleş B, Esen B, Öztunç H. Evaluation of unilateral condyler hyperplasia by cone-beam computed tomography: A report of two cases and review of the literature. *J Dent Fac Atatürk Uni* 2010;20: 198-204.

Yazışma Adresi

Cem Üngör
Karadeniz Technical University Faculty of
Dentistry Department of Oral and Maxillofacial
Surgery, Trabzon, TURKEY
Tel00 0 532 2403191
Fax00 0 462 3773017
e-mail: cem_ungor@yahoo.com

