

## PAPER DETAILS

TITLE: A CASE OF RIGHT ATRIAL HYDATID CYST RELATED WITH TRICUSPID SEPTAL LEAFLET AND SEPTUM

AUTHORS: Senol GÜLMEN, Ilker KIRIS, Erkan KURALAY

PAGES: 98-100

ORIGINAL PDF URL: <https://dergipark.org.tr/tr/download/article-file/422301>

## A CASE OF RIGHT ATRIAL HYDATID CYST RELATED WITH TRICUSPID SEPTAL LEAFLET AND SEPTUM

SEPTUM VE TRİKUSPİD SEPTAL LEAFLET İLE İLİŞKİLİ SAĞ ATRIAL KİST HİDATİK OLGUSU

Şenol GÜLMEN, İlker KİRİŞ, Erkan KURALAY\*

\* Süleyman Demirel Üniversitesi Tıp Fakültesi Kalp ve Damar Cerrahisi Anabilim Dalı, Isparta.

### Abstract

Cardiac Hydatid cyst is uncommon, but life threatening. Cardiac involvement occurs in only 0.5-2% of all hydatid infestations. In this report, we present a case of hydatid cyst located in the right atrium adjacent to tricuspid annulus, which was excised surgically (Pam Med J 2008;2(2):98-100).

**Key words:** Hydatid cyst, intracardiac mass, right atrium, interatrial septum

### Özet

Kardiyak kist hidatik seyrek olmakla birlikte yaşamı tehdit eder. Kardiyak tutulum tüm hidatik enfeksiyonlarının sadece %0.5-2' sini oluşturur. Bu olgu sunumunda sağ atriumda tricuspid annulus komşuluğunda yerleşimli ve cerrahi ile çıkarılan bir kist hidatik olgusu sunuyoruz (Pam Tıp Derg 2009;2(2):98-100).

**Anahtar Kelimeler:** Kist Hidatik, intrakardiyak kitle, sağ atrium, interatrial septum

### Introduction

Hydatid Cyst, a parasitic infection caused by *Echinococcus granulosus* [1], still remains as an important health problem in Turkey. Hydatid cyst may occur in various organs such as liver, lung, brain and heart [1]. Cardiac hydatid cyst is rare and accounting for 0.5-2% of all hydatid infections [2]. Right atrium and right ventricle are very uncommon sites for cardiac involvement [1]. We present a case of hydatid cyst located in right atrium adjacent to tricuspid annulus.

### Case Report

A 21-year old male with the symptoms of palpitation and atypical chest pain was admitted to our institute. He underwent an operation due to cerebral cyst hydatid 4 years ago. Results of the physical examination were normal with exception of a minimal diastolic murmur on the tricuspid area. Transthoracic echocardiography (TTE) revealed a heterogeneous cystic mass with calcified margins and 2,5 x 1,8 cm in diameter located in the right atrium and right ventricle (Fig. 1). Cystic mass was adjacent to septal leaflet of tricuspid valve and appeared to be protruding from posterior septum. Transesophageal echocardiography (TEE) confirmed the findings of TTE. Computed tomography (CT) scan of brain clearly revealed multifocal cystic masses in the frontal lobe. Serologic tests for hydatidosis were not done due to positive history of cyst hydatid.

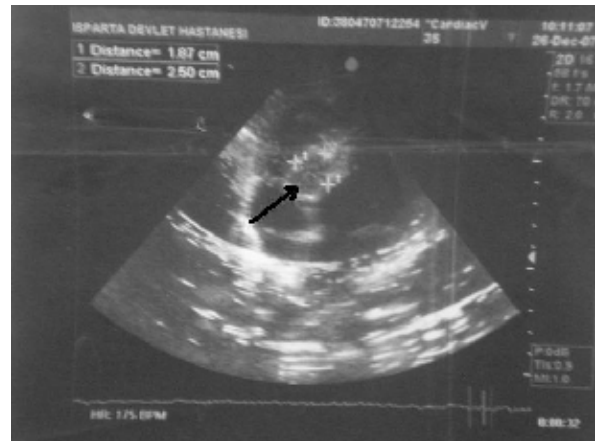

Figure 1. Preoperative TTE image

The patient was referred for surgery. Following median sternotomy, arterial cannulation via ascending aorta and bicaval venous cannulation were done. Cardiopulmonary bypass (CPB) was started and cardiac arrest was obtained by aortic cross clamp and cardioplegia. A right arteriotomy was done. A cystic mass located adjacent to septal leaflet of tricuspid annulus and protruding into posterior wall of the right atrium was noted (Fig. 2). To prevent contamination of the surrounding area, the cystic mass was sterilized with sodium chloride solution and its content was aspirated through a needle puncture before any manipulation. The cyst was opened and excised (Fig. 3). The germinative membrane was

Şenol GÜLMEN

Süleyman Demirel Üniversitesi Tıp Fakültesi Kalp ve Damar Cerrahisi Anabilim Dalı, Isparta  
e-posta: S.gulmen@mynet.com

removed in en block fashion. The cavity layered by fibrous membrane was not closed. After removal of the aortic cross clamp, cystectomy and capitonage was performed to the cystic mass. There was no any early postoperative complication. Albendazole was administrated after operation and the patient was discharged symptom free on the postoperative tenth day.

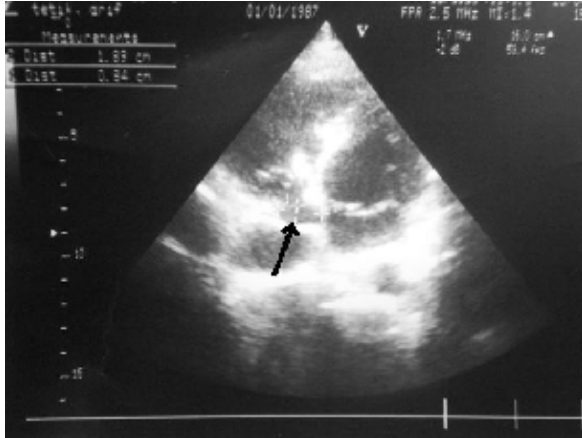

Figure 2. Operative image before cyst excised

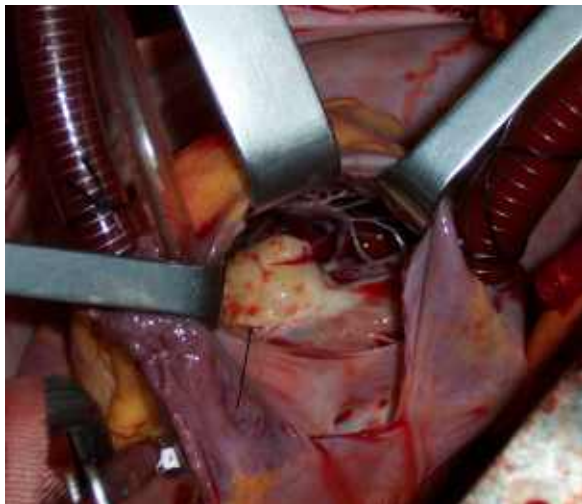


Figure 3. Operative image after cyst excised

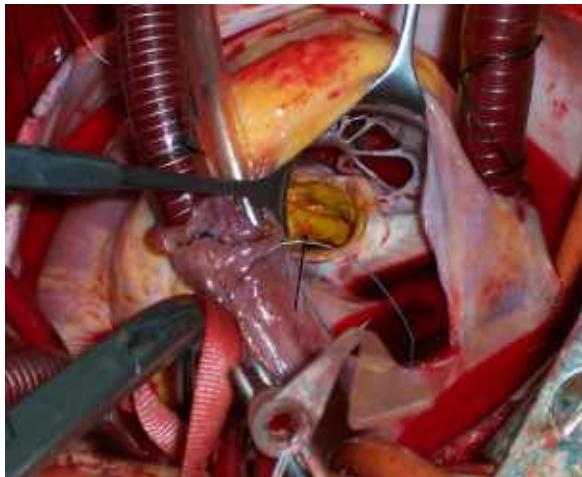


Figure 4. Postoperative TTE image on first month

#### Discussion

Cardiac hydatid cyst was first reported by Williams in 1936 [3]. Cardiac hydatid cysts are generally asymptomatic, although they may present with chest pain, palpitation, dyspnea, angina, arrhythmia, valvular dysfunction, pericardial reactions, pulmonary and systemic embolism, pulmonary hypertension and anaphylactic reactions [1,4]. Clinical picture of a cardiac hydatid cyst generally depends on size, number, and location of the cyst, and presence of complications [5]. Cardiac hydatid cyst may develop in left ventricle (55-71%), right ventricle (13-18 %), interventricular septum (5-13 %), right atrium ( 2,1-4%) and left atrium (8%) [6].

Patients with cardiac hydatid cyst must undergo surgery because of life-threatening complications that may develop when not operated. Operative mortality is very low and early postoperative period is usually uncomplicated [6], but surgical intervention may result in serious complications.

The most common complication of cardiac hydatid cyst is rupture of the cyst which occurs between 24-60 % [4]. The risk of rupture may be determined by the localization of involvement. Hydatid cyst of the left ventricle which rarely ruptures, is usually localized subepicardially due to the relatively high intracavitary pressure. On the other hand, hydatid cyst of the right side of the heart tend to be localized subendocardially. Therefore, intracavitary development is more frequent and the risk of intracavitary rupture is higher in patients with right ventricular hydatid cyst [5]. In several reports, CPB and cross clamping of both aorta and pulmonary artery are recommended to avoid rupture and pulmonary embolisation [4,6,7]. In our patient, the cyst was located on right heart with a high rupture risk. Therefore, we applied cross clamp to both aorta and pulmonary artery. We also paid attention not to rupture the cyst and contaminate right ventricle during venous cannulation.

It is important to consider the localization, number and size of the cyst while planning surgical treatment. When possible, total enucleation of the cyst is the most ideal technique [8]. However, fibrous capsule or cyst cavity may be interrelated with the adjacent myocardium and other cardiac tissues [9]. Thus, fibrous capsule may not be removed easily and the size of the cyst may preclude cyst removal due to disruption of ventricular or valve function, depending on the location [9]. Particularly, cysts localized to septum may cause conduction disturbances and complete atrioventricular block [5]. In this circumstance, decompression by drainage may be the most appropriate and judicious management [9]. Aggressive approach

for removal of the cyst cavity may cause myocardial damage such as bleeding and rupture from myocardial wall [9]. Tejada et al [10] has recommended that if total excision of the cyst wall is not feasible, the remaining cavity should be closed by obliteration, plication, or both. Otherwise, Maroto et al [11] has closed the cavity with polypropylene running suture. We preferred to leave the cavity open due to the risk of disruption of ventricular or valve function and atrioventricular conduction pathway. In the present case, cyst cavity was very large and calcified. In addition, turbulent blood stream that can develop in the cystic cavity which was left

open can lead to complications such as intracardiac thrombus and embolization. Therefore, we administered oral anticoagulation therapy in the postoperative period. We displayed the open cyst cavity with TEE on postoperative seventh day and first month (Fig. 4). There were no any symptoms and complications.

In conclusion, we think that the large cyst cavity interrelated with menacing cardiac structure may be left open in cardiac hydatid cyst patients that required open heart surgery.

## References

1. Celik T, Iyisoy A, Kursaklioglu H, Unlu M, Turhan H, Kose S. Intracavitary left ventricular hydatid cysts ruptured during cardiopulmonary resuscitation in a patient with acute myocardial infarction. *Int J Cardiol* 2006; 111: 155-7.
2. Gormus N, Yeniterzi M, Telli H, Solak H. The clinical and surgical features of right-sided intracardiac masses due to echinococcosis. *Heart Vessels* 2004; 19: 121-4.
3. Yaliniz H, Tokcan A, Salih O.K, Ulus T. Surgical treatment of cardiac hydatid disease. A report of 7 cases. *Texas Heart Inst J* 2006; 33: 333-9.
4. Karabay O, Onen A, Yildiz F, et al. The case of a cyst hydatid localized within the interatrial septum. *Jpn Heart J* 2004; 45: 703-7.
5. Kaplan M, Demirtas M, Cimen S, Ozler A. Cardiac hydatid cyst with intracavitary expansion. *Ann Thorac Surg* 2001; 71: 1587-90.
6. Abid A, Ben Omrane S, Kaouel K, et al. Intracavitary cardiac hydatid cyst. *Cardiovascular Surgery* 2003; 11: 521-5.
7. Erentuğ V, Bozbuğa N, Kırallı K et al. Cardiac hydatid cysts: Surgical treatment and results. *J Card Surg* 2004; 19: 358-60.
8. Parisi F, Gagliardotto P, Zattera G, et al. Complicated removal of a hydatid cyst of the interventricular septum. *J Cardiovasc Surg* 1995; 36: 269-71.
9. Curran R, Paterson S.H. Surgical treatment of intramyocardial foregut cysts. *Ann Thorac Surg* 2005; 80: 737-39.
10. Tejada L.G, Saadvedra J, Molina L, Forteza A, Gomez C. Hydatid disease of the interventricular septum causing pericardial effusion. *Ann Thorac Surg* 2001; 71: 2034-5.
11. Maroto L.C, Carrascal Y, López J.M, Forteza A, Pérez A, Zavanella C. Hydatid Cyst of the interventricular septum in a 3,5-year-old child. *Ann Thorac Surg* 1998; 66: 2110-1.