

## PAPER DETAILS

TITLE: Unusual cause of acute abdominal pain: Uterine torsion

AUTHORS: Hüseyin Gökhan YAVAS,Furkan UFUK

PAGES: 157-159

ORIGINAL PDF URL: <https://dergipark.org.tr/tr/download/article-file/628548>

## Unusual cause of acute abdominal pain: Uterine torsion

### *Nadir bir akut batın nedeni: Uterus torsiyonu*

Hüseyin Gökhan Yavaş, Furkan Ufuk

Gönderilme tarihi:26.02.2018

Kabul tarihi:02.07.2018

#### Abstract

Uterine torsion is an unusual cause of acute abdominal pain and it can be seen in pregnancy but torsion of non-pregnant uterus is a very rare condition. It may cause irreversible ischemic changes and life-threatening conditions. To prevent these complications, early and correct diagnosis is of great importance. Computed tomography and magnetic resonance imaging are successful methods for prompt diagnosis in suspected cases. Also, these methods can guide the surgeon. The aim of this case was to evaluate the clinical and imaging findings of a non-pregnant patient with uterine torsion.

**Anahtar Kelimeler:** Myoma, Torsion abnormality, uterine neoplasms, magnetic resonance imaging, computed tomography.

Yavaş HG, Ufuk F. Unusual cause of acute abdominal pain: Uterine torsion Pam Med J 2019;12:157-159.

#### Özet

Uterin torsiyon, akut karın ağrısının olağan dışı bir nedeni olup gebelikte görülebilir fakat gebe olmayan uterusun torsiyonu çok nadir bir durumdur. Düzeltilmeyen iskemik değişiklikler ve hayati tehlike oluşturan durumlara neden olabilir. Bu komplikasyonları önlemek için erken ve doğru tanı çok önemlidir. Şüpheli vakalarda bilgisayarlı tomografi ve manyetik rezonans görüntüleme hızlı ve başarılı tanı için faydalı görüntüleme yöntemleridir. Ayrıca, bu yöntemler cerrahiye rehberlik eder. Biz burada uterin torsiyonlu gebe olmayan bir hastanın klinik ve görüntüleme bulgularını sunmayı amaçladık.

**Anahtar Kelimeler:** Miyom, torsiyon, uterin tümörler, manyetik rezonans görüntüleme, bilgisayarlı tomografi.

Yavaş HG, Ufuk F. Nadir bir akut batın nedeni: Uterus torsiyonu Pam Tıp Derg 2019;12:157-159.

#### Introduction

Uterine torsion is an unusual cause of acute abdominal pain and it can be seen in pregnancy but torsion of non-pregnant uterus is an extremely rare condition [1-4]. Non-pregnant uterine torsion may be associated with huge uterine mass such as fibroid or malignant tumor. Neglected uterine torsion may cause irreversible ischemic changes and life-threatening conditions [5, 6]. To prevent these complications and in surgical planning, early and correct diagnosis is important. Here, we present a case of giant uterine fibroid torsion accompanying uterine torsion diagnosed by computed tomography (CT) and magnetic resonance imaging (MRI). We also aimed to emphasize the imaging findings.

#### Case Report

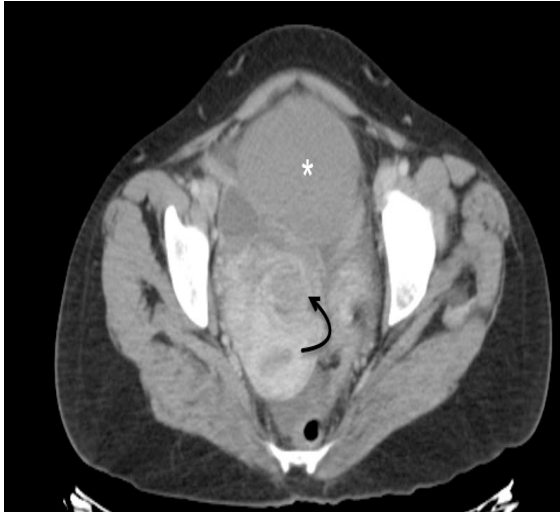A 42-year-old mentally retarded female patient presented to the emergency department with sudden onset lower abdominal pain. In the history of the patient, the pain started 1 day ago and gradually increased. Physical examination revealed abdominal distention and guarding was positive on lower quadrants. Laboratory results showed elevated white-blood cell count (WBC; 19.800/ml, normal range; 3.000 – 10.500/ml) and c-reactive protein level (CRP; 26 mg/L, normal range; 0 - 0.5 mg/L). Other laboratory parameters were within normal limits.

The patient underwent abdominal ultrasound (US) and it showed a giant pelvic mass. Uterus and ovaries could not be evaluated due to the mass. For further evaluation

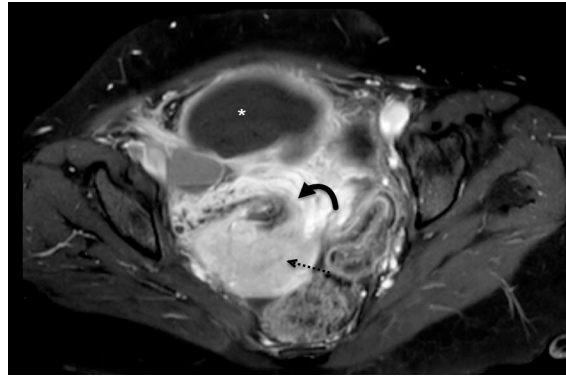
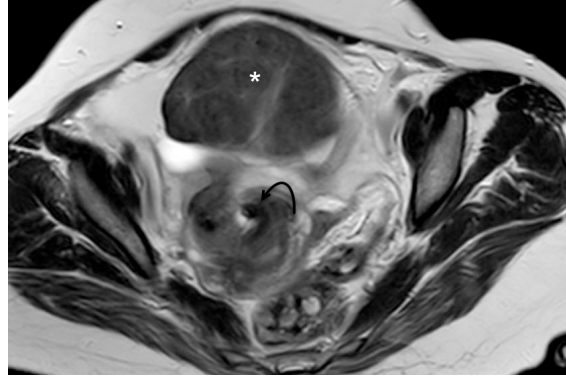
Hüseyin Gökhan Yavaş, Arş.Gör. Pamukkale Üniversitesi Tıp Fakültesi, Radyoloji Ana Bilim Dalı, DENİZLİ, e-posta:huseyingokhanyavas@gmail.com (orcid.org/0000-0003-4220-3482) (Sorumlu yazar)

Furkan Ufuk, Dr.Öğretim Görevlisi, Pamukkale Üniversitesi Tıp Fakültesi, Radyoloji Ana Bilim Dalı, DENİZLİ, e-posta:furkan.ufuk@hotmail.com (orcid.org/0000-0002-8614-5387)

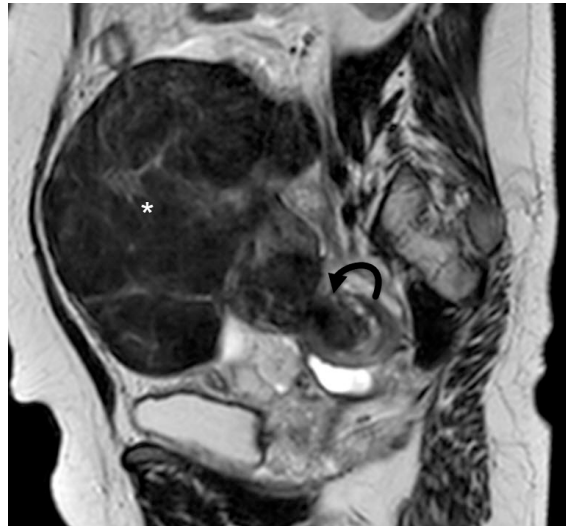intravenous contrast-enhanced abdominal CT was performed. A giant mass with no contrast enhancement was observed in the anterior part of the uterine fundus and swirl-like rotation in the ligamentous structures of the uterus was observed on CT (Fig.1). As a preliminary diagnosis, uterine pedunculated myoma torsion and accompanying uterine or adnexal torsion were suspected. To evaluate the ligamentous structures and to confirm the diagnosis, the patient underwent contrast-enhanced MRI of the lower abdomen. MRI showed a soft tissue lesion in adjacent to the uterine fundus and the lesion was hypointense on both T1- and T2-weighted images and there was no contrast enhancement in lesion. In addition, MRI showed a swirl-like rotation in the uterus and uterine ligamentous structures. Also, there was malposition of uterine ligaments (Fig. 2 and 3).



**Fig. 1.** Axial contrast-enhanced CT scan of the pelvis shows a giant mass with no contrast enhancement (\*) and swirl-like rotation in the uterus (curved black arrow). Also, a displaced round ligament is seen (black dashed arrows).



**Fig. 2. A)** Axial contrast-enhanced T1-weighted and **B)** axial T2-weighted MRI of the pelvis shows a giant hypointense mass with no contrast enhancement (\*), swirl-like rotation in the uterus (curved black arrow). Also, uterine enhancement is seen (black dashed arrows).



**Fig. 3.** Sagittal T2-weighted MRI of the pelvis shows a giant hypointense mass and swirl-like rotation in the uterus (curved black arrow).

The patient underwent abdominal laparotomy. Giant uterine fibroid and uterine torsion (approximately 150 degrees) was confirmed with surgery. Uterine detorsion was performed and uterus was observed as viable. Enucleation of gangrenous mass was performed and lesion was diagnosed with leiomyoma, histopathologically. The one-month follow-up was uneventful.

## Discussion

The uterus rotates more than 45 degrees around its long axis, called uterine torsion. Uterine torsion may be seen due to pregnancy or giant uterine mass, as in our case [1-7]. Broad ligament and uterosacral ligaments that hold the uterus in place. In the presence of large uterine mass, the mass can be twisted around itself but it may distort the normal position of the uterus and cause uterine torsion, as in our case. Also, the blood supply of the uterus may be affected, and torsion may cause necrosis or rupture [5, 6, 8]. In our case, blood supply of the myoma was distorted, but uterus observed as viable.

Isolated uterine torsion may present with non-specific acute abdominal pain, vaginal bleeding or shock. It is very difficult to differentiate from other causes of acute abdominal pain by only clinical and laboratory findings [4-6]. The diagnosis of uterine and/or adnexal torsion and demonstrate the complications preoperatively is important and it will guide the surgeon. CT findings in uterine torsion have been described previously [6-8]. Herein combination of CT and MRI findings of uterine torsion was described.

First of all, gas in the uterine cavity on plain radiographs has been described as a feature of uterine torsion [7]. However, this is a nonspecific finding and it can be seen in other situations such as pelvic inflammatory disease or after intrauterine instrumentation. In our case, there was no contrast enhancement in the fibroid on MRI, indicating that ischemic process. Also, uterine contrast enhancement was normal indicating that viable uterus. In addition, MRI and CT showed a swirl-like rotation in the uterus and ligamentous structures of the uterus, indicating uterine torsion.

Uterine fibroid and accompanying uterine torsion is one of the rare cause of acute abdominal pain. If the diagnosis is delayed uterine or adnexal torsion may cause

undesirable results. Therefore, uterine and/or adnexal torsion should be kept in mind in the differential diagnosis of acute abdominal pain in females. CT and MRI are successful methods for prompt diagnosis in suspected cases. Also, these methods can guide the surgeon, as in our case.

**Conflict of Interest:** The authors declare that there is no conflict of interest.

## References

1. Bolognese RJ, Weber LL, Zachary TV Jr. Torsion of the nonpregnant uterus JAMA. 1967;199:157.
2. Vavrinkova B, Binder T. Uterine torsion in pregnancy. Neuro Endocrinol Lett 2015;36:241-242.
3. Wilson D, Mahalingham A, Ross S. Third trimester uterine torsion: case report. J Obstet Gynaecol Can. 2006;28:531-535.
4. Grover S, Sharma Y, Mittal S. Uterine torsion: a missed diagnosis in young girls? J Pediatr Adolesc Gynecol 2009;22:5-8
5. Collinet P, Narducci F, Stien L. Torsion of a nonpregnant uterus: an unexpected complication of an ovarian cyst. Eur J Obstet Gynecol Reprod Biol 2001;98:256-257
6. Luk SY1, Leung JL, Cheung ML, So S, Fung SH, Cheng SC. Torsion of a nonpregnant myomatous uterus: radiological features and literature review. Hong Kong Med J 2010;16:304-306
7. Davies JH. Torsion of a nonpregnant nonmyomatous uterus. Clin Radiol 1998;53:780-782
8. Yap FY, Radin R, Tchelepi H. Torsion, infarction, and rupture of a nonpregnant uterus: a complication of a large ovarian cyst. Abdom Radiol 2016;41:2359-2363.