

PAPER DETAILS

TITLE: Gebe Hastada Ovaryan Torsion Tanisinda MRG

AUTHORS: Mert Köroglu, Mustafa Yalçın, Bahattin Baykal, Harun Yıldız, Ahmet Yesildag, Orhan Oyar

PAGES: 39-42

ORIGINAL PDF URL: <https://dergipark.org.tr/tr/download/article-file/196601>

MRI in the Diagnosis of Ovarian Torsion in a Pregnant Patient

Mert Koroğlu, Mustafa Yalçın, Bahattin Baykal, Harun Yıldız,
Ahmet Yeşiladağ, Orhan Oyar

Süleyman Demirel Üniversitesi Tıp Fakültesi Radyoloji AD, Isparta

Özet

Gebe Hastada Ovaryan Torsion Tanısında MRG

Gebeliğin ikinci trimesterinde MRG (Manyetik rezonans görüntüleme) ile tanı konulan vakayı sunuyoruz. Over torsiyonunun MRG bulguları torsiyon tarafındaki lokal inflamasyondan intraovaryan hemorajiye ve hatta hemoperitona kadar değişkenlik gösterebilir. Cerrahi acillerden olan bu patolojinin preoperatif tanısı fetal ve maternal morbiditeyi azaltmak için çok önemlidir.

Anahtar kelimeler: Over, Torsiyon, Manyetik rezonans görüntüleme, Gebelik

Abstract

We report a case of ovarian torsion during 2nd trimester of pregnancy which was diagnosed with MRI (Magnetic resonance imaging). MRI findings of ovarian torsion may vary from local inflammation in the twisted side, to intraovarian hemorrhage and to even hemoperitoneum. Preoperative diagnosis of this surgical emergency is very important to decrease fetal and maternal morbidity.

Key words: Ovary, Torsion, Magnetic resonance imaging, Pregnancy

Introduction

Ovarian torsion is caused by partial or complete rotation of the mesovarium. Torsion of the adnexal structures may involve the tube or ovary but more often involves both. The preoperative diagnosis of torsion is very difficult and delay in surgical intervention can lead to irreversible damage to the ovary. The usual predisposing factor is an ipsilateral adnexal mass that is almost always benign. Torsion infrequently occurs in the absence of an apparent adnexal mass. This is usually seen in children, in whom the adnexa are especially mobile, allowing torsion at the mesosalpinx (1).

Ovarian torsion during pregnancy especially in the second and third trimesters is a very rare condition. The diagnosis is difficult to establish on the basis of symptoms, physical findings or imaging modalities. Between 10% and 20% of all ovarian torsions occur in pregnant women, mostly in the first trimester (1, 2). In the second and third trimesters, the diagnostic accuracy of ultrasound especially transvaginal ultrasound is limited because the ovaries are displaced from their normal positions (2).

CT may still be the preferred further examination method in acute abdomen, but since there is an ionizing radiation in CT, it's not a preferred imaging modality for pregnant women (3, 4).

Fast MRI (Magnetic resonance imaging) sequences allows examination of pregnant patients with acute abdominal pain, although it cannot be used for severely ill patients in unstable condition. Several studies have reported that MRI provided more specific, useful information about various acute gynecologic diseases (4, 5). With the recent developments in fast sequences and coil technology, MRI is more often utilized in the obstetric setting for imaging of both maternal and fetal diseases. There is no clinical or experimental evidence of teratogenic or other adverse effects of MRI during pregnancy (6,7).

Case report

A 25-year-old pregnant woman presented to the emergency unit with acute onset of lower abdominal pain. No recent illness, fever, or urinary complaints were reported, and her vital signs were stable. Physical examination was normal except for right lower quadrant abdominal tenderness and rebound. No cervical dilatation was detected. Hemoglobin, hematocrit, white blood cell and platelet count, and urine analysis were normal.

Ultrasonography revealed a fetus in utero with a

Yazışma Adresi: Dr Mert Koroglu
Suleyman Demirel Üniversitesi Tıp Fakültesi Radyoloji AD
32200 Isparta
Tel: 0246 2112897
E-mail: mertkoroglu@hotmail.com
mertkoroglu2000@yahoo.com

gestational age of 23 weeks. 4x5x7 cm hyperechoic mass containing multiple cysts was seen in right lower quadrant.

Differential diagnosis included plastrone appendicitis, ovarian tumor, ovarian torsion, and myoma of the uterus with necrotic infarction. In order to clarify the diagnosis and to decide on the need for immediate surgical intervention, MRI was performed. Fast pulse sequences were used to avoid artifacts due to fetal movements. MRI was performed with a 1.5 T superconducting system (Signa; GE Medical Systems, Milwaukee, Wisconsin) with a phased-array coil. MRI protocol included axial, coronal and sagittal T2-weighted single shot fast spin echo (SSFSE) images (TR: infinite, TE: 80 ms, matrix: 256 x 256, bandwidth: 31.25 Hz/pixel, slice thickness: 6 mm with 2 mm spacing), axial fat-suppressed fast spin echo (FSE) T2-weighted images (TR: 2500-3200 ms, TE: 90 ms, number of excitations (NEX): 2, echo train length (ETL): 17, matrix: 192x 256, bandwidth: 20.83 Hz/pixel, slice thickness: 7 mm with 1 mm spacing), axial short tau inversion recovery (STIR) (TR: 7750 ms, TE: 34 ms, Inversion Time (TI): 150 ms, NEX:2, ETL: 17, matrix: 160 x 256, bandwidth: 15.63 Hz/pixel, slice thickness: 7 mm with 1 mm spacing), and axial T1-weighted FSE images (TR: 700 ms, TE: minimum, NEX: 3, ETL: 2, matrix: 192 x 256, bandwidth: 20.83 Hz/pixel, slice thickness: 6 mm with 1 mm spacing) were obtained. SSFSE images were obtained during sustained respiration (at the end of expiration). All other sequences were acquired during quiet respiration. The region of interest was from the level of the kidneys to the symphysis pubis. The field of view varied from 25 to 40 cm. Total scanning time was about 30 min. MRI showed enlarged right ovary 4x 5 x 7 cm in size, containing multiple follicles largest being 18 mm in diameter (Figure 1). No mass lesion within the ovary was detected. Lesion demonstrated curvilinear hyperintens areas on T1-weighted images and this was interpreted as a sign of introvarian hemorrhage. The pedicle of right ovary was enlarged when compared with the left side. Normal left ovary was also visualized. MRI diagnosis was right ovarian torsion with intraovarian hemorrhage.

The patient underwent surgery, and laparotomy instead of laparoscopy was performed because of the pregnancy. The pathology report described an enlarged right ovary with extensive hemorrhage. It contained multiple cysts. The pregnancy continued without problems. The patient was discharged on postoperative

day 4.

Discussion

A rapid, reliable, and accurate imaging method is needed for the evaluation of pregnant patients with acute pelvic pain since clinical and laboratory findings cannot reliably confirm or dismiss a diagnosis of ovarian torsion in pregnancy. The ideal imaging method should be capable of diagnosing the other possible etiologies of pelvic pain.

US is traditionally the initial imaging modality of choice for evaluation of patients in obstetrics since it is safe, inexpensive and can be easily performed at the bedside (8-10). However US is highly operator dependent and factors such as intervening bowel gas, the gravid uterus and obesity may interfere with the quality and adequacy of the examination. CT is of limited use in obstetric patients because of teratogenic effects of the radiation.

MRI findings in various gynecologic emergencies including ovarian hemorrhage, ectopic pregnancy, tumor rupture, torsion, hemorrhage, infarction, and pelvic inflammatory diseases were described (7). The main strength of MRI is its ability to determine the exact organ of origin when it is not clearly determined by other imaging modalities (7). MRI of the pelvis allows evaluation of both medically emergent and non-emergent causes of pelvic pain. Several studies reported that MRI provided more specific, useful information about various gynecologic diseases (5, 7).

Ovarian torsion accounts for approximately 3% of gynecologic emergencies, and 10-20% of the ovarian torsions are found in pregnant women, usually in the first trimester. Adnexal torsion in the second and third trimester is very uncommon. Adnexal torsion is frequently associated with ovarian hyperstimulating therapy or ovarian masses. The preoperative diagnosis is difficult and adnexal torsion should be considered when an ovarian mass is detected in the appropriate clinical setting (2, 11).

Torsion of the ovarian pedicle results in circulatory stasis that is initially venous, but it becomes arterial as the torsion and the resultant edema progress. When complete torsion with hemorrhagic necrosis is suspected, immediate surgery is necessary. If left untreated, hemorrhagic infarction of the involved ovary may be followed by infection, leading to peritonitis and, in some cases, death (4, 5). Morphologically, the involved ovary may be a complex mass with septation and debris, a cystic

mass, or a solid mass with peripheral cysts of 8–12 mm in diameter. This latter appearance reflects congestion of the ovary and transudation of fluid into follicles owing to circulatory impairment and has been described by Graif et al (12).

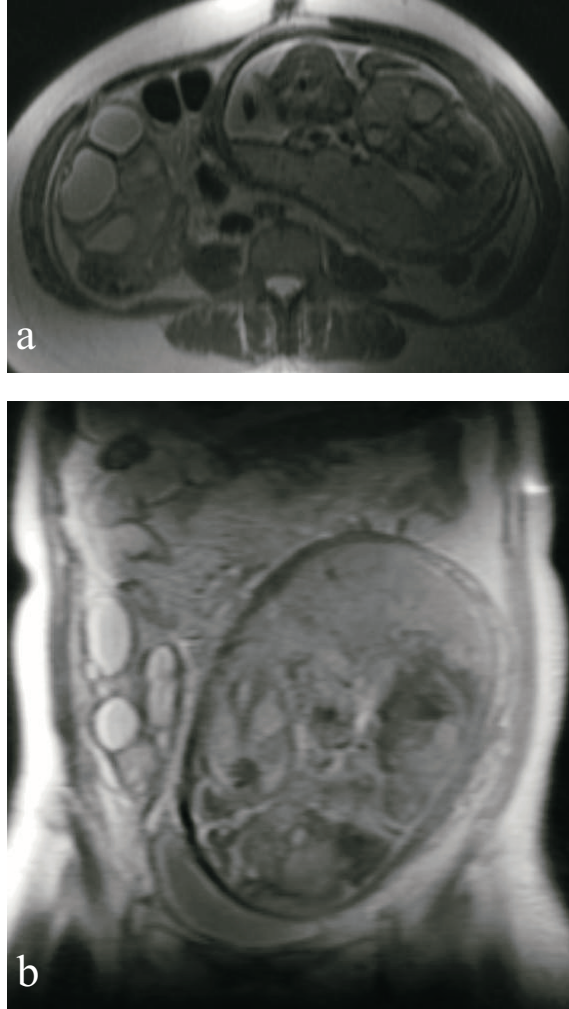


Figure 1: Right ovarian torsion and hemorrhage in a 23 year-old patient at 23 weeks of gestation. (a) axial T2-weighted SSFSE (TR/TE: infinite/80) (b) coronal T2-weighted SSFSE (TR/TE: infinite/80) images show enlarged right ovary 4 × 5 × 7 cm in size, containing multiple follicles. Lesion demonstrated curvilinear hyperintense areas on T1-weighted images and this was interpreted as a sign of introvarian hemorrhage (not shown). Surgery confirmed the diagnosis of right ovarian torsion and introvarian hemorrhage.

Ultrasound findings, including solid, cystic, and complex pelvic tumors with or without fluid collections in the pouch of Douglas, are nonspecific. Ultrasound is of limited value during pregnancy since ovaries are displaced by the enlarged uterus. The limited specificity of Doppler US was showed by demonstrating normal adnexal arterial waveforms

at Doppler US in case reports of proved adnexal torsion. This may be due to the dual ovarian blood supply (the ovarian artery from the aorta and the ovarian arterial branches from the uterine artery). Another explanation may be venous thrombosis due to torsion leads to symptoms and ovarian necrosis before arterial thrombosis occurs (11, 13, 14). Findings of ovarian torsion on non-enhanced MRI include a thick, edematous pedicle, signal intensities indicative of hemorrhage within the ovary or the tube, smooth wall thickening of the twisted ovarian cystic mass, ascites, hemoperitoneum and uterine deviation to the twisted side (11, 15). The MRI findings of massive ovarian edema, which is regarded to be a rare variant of torsion resulting from partial intermittent torsion is also reported (16). Accurate and early diagnosis essential for prompt surgical intervention to avoid fetal and maternal morbidity and mortality. For this purpose MRI is a safe, accurate and fast imaging method for evaluation of pregnant patients with acute pelvic pain. It provides a broad evaluation of the pelvic organs and enables the diagnosis of many other emergency etiologies of pelvic pain during pregnancy.

References

1. Jain, KA. "Magnetic resonance imaging findings in ovarian torsion." *Magn Reson Imaging* 1995; 13: 111-13
2. Born C, Wirth S, Stabler A, Reiser M. Diagnosis of adnexal torsion in the third trimester of pregnancy: a case report. *Abdom Imaging* 2004 ; 29: 123-127
3. Levine D, Barnes PD, Edelman RR. Obstetric MRI. *Radiology* 1999; 211: 609–617
4. Nagayama M, Watanabe Y, Okumura A, Amoh Y, Nakashita S, Dodo Y. Fast MRI in obstetrics. *Radiographics* 2002; 22: 563-582
5. Dohke M, Watanabe Y, Okumura A, et al. Comprehensive MRI of acute gynecologic diseases. *RadioGraphics* 2000; 20: 1551–1566
6. Jung SE, Byun JY, Lee JM, et al. MR of maternal diseases in pregnancy. *AJR* 2001; 177: 1293-1300
7. Nishino M, Hayakawa K, Iwasaku K, Takasu K. Magnetic resonance imaging findings in gynecologic emergencies. *JCAT* 2003; 27: 564-570
8. Albayram F, Hamper UM. Ovarian and adnexal torsion: spectrum of sonographic findings with pathologic correlation. *J Ultrasound Med* 2001; 20 :1083-1089
9. Yaman C, Ebner T, Jesacher K. Three-dimensional power Doppler in the diagnosis of ovarian torsion. *Ultrasound Obstet Gynecol* 2002; 20: 513-515
10. Degirmenci NA, Ozkan IR, Ilhan H. Case report: Ovarian torsion in inguinal canal. *Tani Girişim Radyol*

- 2003; 9: 388-390
11. Rha SE, Byun JY, Jung SE, et al. CT and MRI features of adnexal torsion. *RadioGraphics* 2002; 22: 283-294
 12. Graif M, Shalev J, Strauss S, et al. Torsion of the ovary: sonographic features. *AJR* 1984; 143: 1331-1334
 13. Hurh PJ, Meyer JS, Shaaban A. Ultrasound of a torsed ovary: characteristic gray-scale appearance despite normal arterial and venous flow on Doppler. *Pediatr Radiol* 2002; 32: 586-588
 14. RosadoWMJr, Trambert MA, Gosink BB, Pretorius DH. Adnexal torsion: diagnosis by using Doppler sonography. *AJR* 1992; 159: 1251-1253
 15. Kimura I, Togashi K, Kawakami S, Takakura K, Mori T, Konishi J. Ovarian torsion: CT and MRI appearances. *Radiology* 1994; 190: 337-341
 16. Kramer LA, Lalani T, Kawashima A. Massive edema of the ovary: high resolution MR findings using a phased-array pelvic coil. *J Magn Reson Imaging* 1997; 7: 758-760