

PAPER DETAILS

TITLE: EVALUATION OF MEIBOMIAN GLANDS IN CUTANEOUS ROSACEA

AUTHORS: Ersin MUHAFAIZ,Seray ASLAN,Hasan Ali BAYHAN,Emine ÇÖLGEÇEN,Canan GÜRDAL

PAGES: 621-626

ORIGINAL PDF URL: <https://dergipark.org.tr/tr/download/article-file/1859020>

EVALUATION OF MEIBOMIAN GLANDS IN CUTANEOUS ROSACEA

CİLT ROZASEASINDA MEİBOMİAN BEZLERİN DEĞERLENDİRİLMESİ

Ersin MUHAFAZ¹, Seray ASLAN BAYHAN², Hasan Ali BAYHAN², Emine ÇÖLGEÇEN³, Canan GÜRDAL⁴

¹ Kafkas University, Faculty of Medicine, Department of Ophthalmology, Kars, TURKEY

² Bozok University, Faculty of Medicine, Department of Ophthalmology, Yozgat, TURKEY

³ Bozok University, Faculty of Medicine, Department of Dermatology, Yozgat, TURKEY

⁴ Dünya Göz Hospital, Ophthalmology Department, Ankara TURKEY.

Cite this article as: Muhafaz E, Aslan Bayhan S, Bayhan HA, Çölgeçen E, Gürdal C. Evaluation of Meibomian Glands in Cutaneous Rosacea. Med J SDU 2021; 28(4): 621-626.

Öz

Amaç

Cilt rozaseası olan hastalarda gözyaşı fonksiyonlarını ve Meibomian bezlerin durumunu değerlendirmek.

Gereç ve Yöntem

Cilt rozaseası olan 38 hasta (çalışma grubu) ile 30 sağlıklı gönüllü bireyin (kontrol grubu) sağ gözleri değerlendirildi. Oküler yüzey hastalık indeksi (OSDI) skoru hesaplandıktan sonra sırasıyla gözyaşı ozmolariteleri ve gözyaşı kırılma zamanları (T-BUT) ölçülüp ve Schirmer testi yapıldı. Alt ve üst kapaktaki meibomian bezler Sirius ön segment analiz sistemi ile meibografi yapılarak değerlendirildi.

Bulgular

Gruplar arasında yaş ve cinsiyet açısından istatistiksel olarak anlamlı fark saptanmadı ($p>0.05$). OSDI skoru, gözyaşı ozmolaritesi ve Schirmer değerleri açısından gruplar arasında istatistiksel olarak anlamlı fark saptanmadı (tümü için $p>0.05$). Çalışma grubunun T-BUT değerlerinin kontrol grubuna göre anlamlı olarak daha kısa olduğu tespit edildi ($p<0.01$). Rozasea ve kontrol grubunda üst göz kapağında meibomian bezlerdeki kayıp oranının ortanca değerleri sırası ile %18.00 (çeyrekler arası aralık [ÇAA]: %8.10-27.75) ve %14.60 (ÇAA: %7.95-25.30) iken alt göz kapağı

meibografisinde bu değerler sırası ile %15.00 (ÇAA: %9.37-25.90) ve %11.15 (ÇAA: %5.60-19.70) idi. Hem alt hem de üst göz kapağında meibomian bezlerdeki kayıp oranı açısından gruplar arasında istatistiksel olarak anlamlı bir fark saptanmadı (sırasıyla, $p=0.39$ ve $p=0.18$).

Sonuç

Cilt rozaseası olan hastalarda daha yüksek oranda meibomian bez kaybı gözlenmesine rağmen, bu istatistiksel olarak kontrol grubundan farklı değildi. Buna rağmen bu hastalarda gözyaşı instabilitesi olduğu saptandı.

Anahtar Kelimeler: Cilt Rozaseası, Gözyaşı Fonksiyonları, Kuru Göz, Meibografi, Meibomian Bezler.

Abstract

Objective

To evaluate tear functions and Meibomian glands' status in patients with cutaneous rosacea.

Material and Methods

Right eyes of 38 patients with cutaneous rosacea (study group) and 30 healthy volunteers (control group) were evaluated. After Ocular Surface Disease Index (OSDI) score was calculated, tear osmolarity

Sorumlu yazar ve iletişim adresi /Responsible author and contact address: E.M. / ersinmuhafaz@hotmail.com

Müracaat tarihi/Application Date: 04.07.2021 • **Kabul tarihi/Accepted Date:** 29.09.2021

ORCID IDs of the authors: E.M: 0000-0002-8281-8767; S.A.B: 0000-0001-8514-9450;

H.A.B: 0000-0002-3364-6890; E.Ç: 0000-0001-9651-6068; C.G: 0000-0002-5312-378X

and tear break-up time (T-BUT) were measured, and the Schirmer test was applied respectively. Meibomian glands in the lower and upper eyelids were evaluated by meibography using the Sirius anterior segment analysis system.

Results

No statistically significant difference was detected between the groups in respect of age and gender ($p>0.05$). No statistically significant difference was determined between the groups in respect of the OSDI score, tear osmolarity, and Schirmer test values ($p>0.05$ for all). The T-BUT values of the study group were detected to be significantly shorter than those of the control group ($p<0.01$). The median values of meibomian gland loss rate in the upper eyelid of the rosacea and control groups were 18.00%

(Interquartile range [IQR]: 8.10-27.75%) and 14.60% (IQR: 7.95-25.30%) respectively, while these values in the lower eyelid meibography, were 15.00% (IQR: 9.37-25.90%) and 11.15% (IQR: 5.60-19.70%) respectively. No statistically significant difference was determined between the groups in terms of loss of meibomian glands in both the upper and lower eyelids ($p=0.39$ and $p=0.18$, respectively).

Conclusion

Although a higher rate of loss of meibomian glands was observed in patients with cutaneous rosacea, this was not statistically different from the control group. However, tear instability was detected in these patients.

Keywords: Cutaneous Rosacea, Tear Functions, Dry Eye, Meibography, Meibomian Glands.

Introduction

Rosacea is one of the inflammatory cutaneous diseases which damages sebaceous glands and blood vessels, especially in the middle region of the face (1). Although it can be seen in children, rosacea generally starts after the age of 30 years and with progression, clinical findings are fully formed at the age of 40-60 years (2,3). These findings include flushing, erythema on the face, telangiectasis, papules and pustules. In the late stage, sebaceous gland hypertrophy and phymatous changes associated with dermal fibrosis occur (4). Although the etiology of rosacea is not fully understood, genetic predisposition, immune system dysfunction and inflammatory reactions are thought to be responsible (2). It has been suggested that the disease is activated by inflammatory reactions triggered by factors such as Demodex Folliculorum infestation, spicy food, alcohol consumption, menopause, and environmental factors such as sunlight and climate and temperature changes (1-3,5).

Although rosacea is a skin disease, as it leads to inflammation, the lid margins, meibomian glands, conjunctiva, sclera/episclera, and cornea are also affected (6). Ocular involvement is found in approximately 50% of patients diagnosed with cutaneous rosacea, and the ocular findings emerge before skin findings in approximately 20% of patients (4,5). As diagnosis is a little difficult, it is difficult to determine the actual prevalence of ocular rosacea because there is no specific serological test and findings are generally overlooked (7). Eye involvement is usually bilateral and when diagnosis and treatment

cannot be made, this may lead to ocular morbidity and social problems. Ocular symptoms of patients include burning, dryness, a foreign body sensation, itching, watering, pain, photophobia, and blurred vision (8-10). In rosacea patients with eye involvement, dry eye, cicatrising conjunctivitis, corneal infiltrations, phlyctenules, peripheral corneal vascularisation, corneal thinning and ulcerations are seen (8,9,11,12).

Irregularities on the eyelid margin, telangiectasis, dilated Meibomian gland orifices and intense seborrheic secretion are found secondary to Meibomian gland dysfunction (MGD) accompanying rosacea. A foamy accumulation is seen at the edge of the lower eyelid associated with excessive Meibomian secretion (9-11). Although there is no specific ocular finding in rosacea, it is most often accompanied by MGD (6). MGD is a chronic ocular surface disease that disrupts ocular surface hemostasis and is characterised by qualitative changes in gland secretion or obstruction of the terminal secretory channels of the Meibomian glands (13). Meibography is a non-invasive and reliable method to determine the anatomic changes and loss rates in the glands when evaluating MGD (14,15). Our purpose in this study is to assess Meibomian glands with meibography and tear functions in rosacea patients.

Material And Methods

Thirty eight patients with cutaneous rosacea were included in the study group and 30 healthy individuals were included in the control group. Ethical approval was obtained from the Bozok University Ethics Committee (date: 25.05.2015; number: 604-351)

before starting the study. Study processes were implemented in accordance with the standards of Helsinki Declaration. Informed consent was taken from each participant. Patients with acne vulgaris, psoriasis, and vitiligo were not included into the study. Subjects with pterygium, giant papillary conjunctivitis, ocular surgery history and contact lens use were excluded from the study. The rosacea patients included in the study were individuals who were followed up with systemic or local treatments in the dermatology department due to skin lesions. Those who receiving ocular treatment or those with ocular rosacea were not included in the study in order not to disturb homogenization.

Patients followed up with a diagnosis of rosacea in the examination performed by an experienced dermatologist in the dermatology clinic were included in the study group (2). Then, in the ophthalmology clinic, the visual acuity of the participants was measured and anterior segment slit lamp examination was performed. For the evaluation of tear functions, Ocular Surface Disease Index (OSDI) questionnaire scores were calculated, tear film osmolarity (TearLab Corporation, San Diego, CA, USA) and tear break-up time (T-BUT) were measured respectively and the Schirmer test was made under topical anesthesia. Meibography of the right eye of each subject was performed with the Sirius topography device (Sirius, CSO, Florence, Italy).

Images of the Meibomian glands of the each eyelid was taken with the meibography mode of the Sirius topography using infrared light. By everting the each eyelid respectively, meibography of the Meibomian glands were taken. The loss in the glands is calculated by marking the gland boundaries, and the device gives a score by grading this loss rate. Loss percentage in the Meibomian glands <10% calculated as grade 0, 10-25% loss as grade 1, 25-50% loss as grade 2, 50-75% loss as grade 3 and

>75% loss as grade 4 (meiboscore).

The results of the study were analysed statistically with SPSS24 version (Statistical Package for the Social Sciences, IBM). It was determined whether the data showed normal distribution or not. In the comparisons between groups, the Student t-test or the Mann-Whitney U test was performed. The p value of lower than 0.05 was noted as statistically significant.

Results

Rosacea group consisted from 31 females and seven males and control group consisted from 22 females and eight males. The mean age of study and control groups were 49.50 ± 12.51 years (range, 22-75 years) and 47.86 ± 12.82 years (range, 26-71 years), respectively. No statistically significant difference was observed between the groups in respect of age and gender ($p=0.59$ and $p=0.41$). When the groups were evaluated in relation to the tear parameters, T-BUT values of the rosacea patients were significantly shorter than those of the control subjects ($p<0.01$). But no statistically significant difference was founded between the rosacea and control groups in terms of OSDI score, tear film osmolarity and Schirmer test values ($p=0.12$, $p=0.90$ and $p=0.08$, respectively).

The median of loss rate in the upper eyelid meibomian glands was 18.00% (interquartile range [IQR]: 8.10%-27.75%) in the rosacea patients and 14.60% (IQR: 7.95%-25.30%) in the healthy subjects ($p = 0.39$). The median of loss percentage in the lower eyelid meibomian glands was 15.00% (IQR: 9.37%-25.90%) in the rosacea group and 11.15% (IQR: 5.60%-19.70%) in the control subjects ($p=0.18$). There was no significant difference between the two groups in relation of upper and lower eyelid meiboscores ($p=0.73$, $p=0.11$, respectively) (Table 1). Figure 1 demonstrates meibography of a patient from the rosacea group.

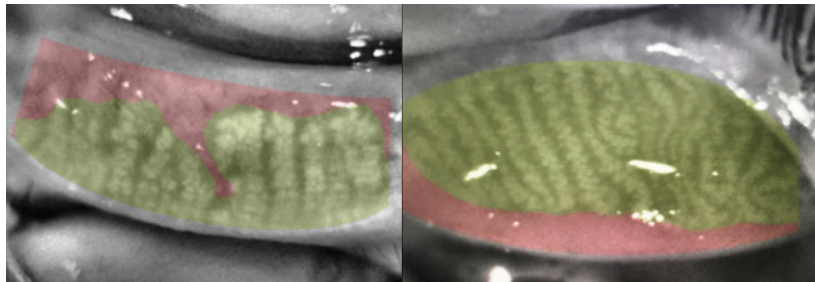


Figure 1
Meibomian gland loss rate of a patient's upper and lower eyelid from study group.

Table 1 The tear parameters and the results of meibography of the study participants

| | Study Group (n=38) | Control Group (n=30) | p value |
|---|-----------------------------------|-----------------------------------|-----------------|
| | Mean±SD Median (IQR) | Mean±SD Median (IQR) | |
| Tear Osmolarity (mOsm/L) | 293.54±8.77 292 (287-297) | 294.63±11.04 293 (287-296) | 0.90 |
| TBUT (secs) | 6.0±4.69 5 (3-7) | 13.2±5.9 14 (8-16.7) | <0.01 |
| Schirmer (mm/5 min) | 7.2±4.5 7 (3.75-10) | 9.8±5.5 9 (4-14) | 0.08 |
| Loss on upper eyelid Meibography (%) | 21.25±16.43 18.00 (8.10-27.75) | 17.44±12.79 14.60 (7.95-25.30) | 0.39 |
| Loss on lower eyelid Meibography (%) | 17.40±11.70 15.00 (9.37-25.90) | 13.44±10.61 11.15 (5.60-19.70) | 0.18 |
| Upper eyelid Meiboscore | 1.0±0.9 1 (0-2) | 0.9±0.9 1 (0-2) | 0.73 |
| Lower eyelid Meiboscore | 0.9±0.7 1 (0-1.75) | 0.6±0.6 1 (0-1) | 0.11 |

TBUT: Tear Break-up Time, SD: Standard Deviation, IQR: Interquartile Range
Data are presented as mean ± standard deviation and median (IQR)

Discussion

The pathophysiology of rosacea has been associated with inflammation, vascular dysfunction and Demodex infestations (1,2,5,16). As patients benefit from anti-inflammatory and antibiotic treatments, this supports the view that inflammatory and infective processes have a role in the pathogenesis (16,17). MGD, which is seen very often in rosacea patients, leads to rapid evaporation of tears associated with abnormal lipid expression (18,19). As one of the most frequently encountered diseases in ophthalmology clinics, MGD can be evaluated biomicroscopically or can be evaluated more objectively with the relatively new method of meibography. Previous studies have shown that MGD grading is a reliable method in the evaluation of the Meibomian glands with meibography (14,20).

In the present study, non-contact images of the Meibomian glands of cutaneous rosacea patients were taken by the Sirius device to assess the loss ratios and meiboscores. Although the loss rate and meiboscore of both the upper and lower eyelid meibomian glands were higher in the cutaneous rosacea group than in the control group, this was

not statistically significant. Contrary to the results of our study a previous study found the Meibomian glands' damage was more advanced in skin rosacea patients than control subjects (21). We think that the difference in the results of these two studies may be due to the different rates of the subtypes of skin rosacea included in the studies. Because the histopathological findings of different subtypes of cutaneous rosacea may be different and the severity of these findings may vary according to the subtypes (22). In another study that evaluated lower eyelid Meibomian glands with an in vivo confocal microscope according to inflammation, fibrosis and the degree of meibum reflectivity, the scores of the rosacea patients were reported to be significantly higher than those of the controls. Also a correlation was reported between the Meibomian gland findings in the lower eyelid and face findings in that study (23). This results suggest that there may be a relationship between the severity of skin rosacea and the involvement of the meibomian glands. And this may have contributed to the fact that the results of our study differ from the results of previous studies. In addition, the fact that histopathological findings on the skin vary with the severity of rosacea supports our idea (22). Palamar et al. determined that although

rosacea patients had a higher loss rate of lower eyelid Meibomian glands, there was no statistically significant difference between rosacea and control groups in relation of loss of upper eyelid meibomian glands. However, they included only patients with ocular rosacea in their study (15). In our study, only patients with cutaneous rosacea were evaluated.

It is a widely known fact in the literature that some drugs used in the systemic treatment of skin rosacea (e.g. doxycycline) are also used in the treatment of meibomian gland dysfunction (24,25). In addition, it has been shown that systemic ivermectin, which is used in the treatment of rosacea, is effective in reducing the concentration of Demodex Folliculorum, which plays a role in the etiology of MGD, in the eyelashes (26). It has been suggested that even topical creams applied to the face may benefit the ocular surface (27). These findings suggest that the treatments our rosacea patients received for skin rosacea may have prevented damage to their meibomian glands.

Of the tear function tests in this study, only the TBUT value was observed to be significantly shorter in the rosacea patients. In another study that evaluated tear function tests in rosacea patients, a significant difference was found in the TBUT and tear osmolarity values compared to the healthy individuals (28). However, as in our study, no significant difference was observed between the groups in relation of the OSDI and Schirmer test values. In another study, a positive correlation was found between anti-inflammatory cytokines and TBUT (29). From these results, it was thought that the TBUT could have been shortened as a result of the increased tear evaporation associated with inflammatory processes in the tear films of rosacea patients in this study.

Our study is comprehensive in terms of evaluating the confinement of important parameters for ocular surface hemostasis, such as meibomian glands, tear osmolarity, Schirmer test, and TBUT. However, one of the most important limitations of our study is the limited number of patients. Therefore, studies with larger series are needed.

Conclusion

Although a higher rate of loss of meibomian glands was observed in patients with skin rosacea, this was not statistically different from the control group. However, tear instability may occur in these patients. Further studies with large series investigating the relationship between cutaneous rosacea subtypes and disease severity with meibomian gland loss are

needed to elucidate the association of meibomian glands and cutaneous rosacea.

Conflict of Interest Statement

The authors have no conflicts of interest to declare.

Ethical Approval

Ethical approval was obtained from the Bozok University Ethics Committee (date: 25.05.2015; number: 604-351) before starting the study. Study processes were implemented in accordance with the standards of Helsinki Declaration.

Consent to Participate and Publish

Written informed consent to participate and publish was obtained from all individual participants included in the study.

Funding

This research did not receive any specific grant from funding agencies in the public, commercial, or not-for-profit sectors.

References

- Steinhoff M, Schaubert J, Leyden JJ. New insights into rosacea pathophysiology: a review of recent findings. *J Am Acad Dermatol* 2013;69:5–26.
- Gallo RL, Granstein RD, Kang S, Mannis M, Steinhoff M, Tan J, Thiboutot D. Standard classification and pathophysiology of rosacea: The 2017 update by the National Rosacea Society Expert Committee. *J Am Acad Dermatol* 2018;78:148-155.
- Spoendlin J, Voegel JJ, Jick SS, Meier CR. A study on the epidemiology of rosacea in the U.K. *Br J Dermatol* 2012;167:598-605.
- Webster G, Schaller M. Ocular rosacea: a dermatologic perspective. *J Am Acad Dermatol* 2013;69:42–43.
- Crawford GH, Pelle MT, James WD. Rosacea: I. Etiology, pathogenesis, and subtype classification. *J Am Acad Dermatol* 2004;51:327–341.
- Awais M, Anwar MI, Iftikhar R, Iqbal Z, Shehzad N, Akbar B. Rosacea—the ophthalmic perspective. *Cutan Ocul Toxicol* 2015;34:161-166.
- Blount BW, Pelletier AL. Rosacea: a common, yet commonly overlooked, condition. *Am Fam Physician* 2002;66:435-440.
- Vieira AC, Höfling-Lima AL, Mannis MJ. Ocular rosacea—a review. *Arq Bras Oftalmol* 2012;75:363–369.
- Oltz M, Check J. Rosacea and its ocular manifestations. *Optometry* 2011;82:92–103.
- Wilkin J, Dahl M, Detmar M, Drake L, Liang MH, Odom R, Powell F. Standard classification of rosacea: Report of the National Rosacea Society Expert Committee on the classification and staging of rosacea. *J Am Acad Dermatol* 2004;50:907-912.
- Ghanem VC, Mehra N, Wong S, Mannis MJ. The prevalence of ocular signs in acne rosacea: comparing patients from ophthalmology and dermatology clinics. *Cornea* 2003;22:230-233.
- Dursun Altınörs D, Asena L. Systemic Diseases and Dry Eye. *MN Oftalmoloji* 2016;23:53-59.
- Knop E, Knop N, Millar T, Obata H, Sullivan DA. The international workshop on meibomian gland dysfunction: report of the subcommittee on anatomy, physiology, and pathophysiology of the meibomian gland. *Invest Ophthalmol Vis Sci* 2011;52:1938-1978.

14. Arita R, Itoh K, Inoue K, Amano S. Noncontact infrared meibography to document age-related changes of the meibomian glands in a normal population. *Ophthalmology* 2008;115:911–915.
15. Palamar M, Değirmenci C, Ertam I, Yağci A. Evaluation of dry eye and meibomian gland dysfunction with meibography in patients with rosacea. *Cornea* 2015;34:497–499.
16. Holmes AD. Potential role of microorganisms in the pathogenesis of rosacea. *J Am Acad Dermatol* 2013;69:1025–1032.
17. Müftüoğlu İK, Aydın Akova Y. Clinical Findings, Follow-up and Treatment Results in Patients with Ocular Rosacea. *Turk J Ophthalmol* 2016;46:1-6.
18. Evren Ö, Karci AA, Orhan İ, Artüz F, Tamer U, Sener B, Gürsel E. Tear Film Function and Lipid Composition of Meibomian Glands. *Turk J Ophthalmol* 2006;36:450-456.
19. Alvarenga LS, Mannis MJ. Ocular rosacea. *Ocul Surf* 2005;3:41–58.
20. Adil MY, Xiao J, Olafsson J, Chen X, Lagali NS, Ræder S, Utheim ØA, Dartt DA, Utheim TP. Meibomian Gland Morphology Is a Sensitive Early Indicator of Meibomian Gland Dysfunction. *Am J Ophthalmol* 2019;200:16-25.
21. Machalińska A, Zakrzewska A, Markowska A, Safranow K, Wiszniewska B, Parafiniuk M, Machaliński B. Morphological and Functional Evaluation of Meibomian Gland Dysfunction in Rosacea Patients. *Curr Eye Res* 2016;41:1029-1034.
22. Lee WJ, Jung JM, Lee YJ, et al. Histopathological Analysis of 226 Patients With Rosacea According to Rosacea Subtype and Severity. *Am J Dermatopathol* 2016; 38: 347-352.
23. Liang H, Randon M, Michee S, Tahiri R, Labbe A, Baudouin C. In vivo confocal microscopy evaluation of ocular and cutaneous alterations in patients with rosacea. *Br J Ophthalmol* 2017;101:268-2674.
24. Schaller M, Almeida LM, Bewley A, Cribier B, Dlova NC, Kautz G, Mannis M, Oon HH, Rajagopalan M, Steinhoff M, Thiboutot D, Troielli P, Webster G, Wu Y, van Zuuren E, Tan J. Rosacea treatment update: recommendations from the global ROSacea COnsensus (ROSCO) panel. *Br J Dermatol.* 2017;176:465-471.
25. Andrade FMX, Picosse FR, Cunha LPD, Valente CM, Bezerra FM, Miot H, Bagatin E, Freitas D. Ocular surface changes in the treatment of rosacea: comparison between low-dose oral isotretinoin and doxycycline. *Arq Bras Oftalmol.* 2020;83:109-112.
26. Holzchuh FG, Hida RY, Moscovici BK, Villa Albers MB, Santo RM, Kara-José N, Holzchuh R. Clinical treatment of ocular Demodex folliculorum by systemic ivermectin. *Am J Ophthalmol.* 2011;151:1030-1034.e1.
27. Sobolewska B, Doycheva D, Deuter CM, Schaller M, Zierhut M. Efficacy of Topical Ivermectin for the Treatment of Cutaneous and Ocular Rosacea. *Ocul Immunol Inflamm.* 2020:1-5. Epub ahead of print. PMID: 32255398.
28. Ozek D, Evren Kemer Ö, Artüz F. Assessment of Tear Functions in Patients with Acne Rosacea without Meibomian Gland Dysfunction. *Ocul Immunol Inflamm* 2019;27:632-635.
29. Topcu-Yılmaz P, Atakan N, Bozkurt B, Irkeç M, Aban D, Mesci L, Tezcan İ. Determination of tear and serum inflammatory cytokines in patients with rosacea using multiplexbead technology. *Ocul Immunol Inflamm* 2013;21:351-359.