

PAPER DETAILS

TITLE: Ultrasound-Guided Bilateral Infraclavicular Block: Case Report

AUTHORS: Mehmet SARGIN,Mehmet Selçuk ULUER

PAGES: 55-58

ORIGINAL PDF URL: <https://dergipark.org.tr/tr/download/article-file/413663>

Ultrasound-Guided Bilateral Infraclavicular Block in a Patient with Distal Radius Fracture

Distal Radius Kırıklı Hastada Ultrason Rehberliğinde Bilateral İnfraklaviküler Blok

Abstract

Peripheral nerve blockade is a good alternative technique in cases where general anesthesia is not required or there are high risks. When regional anesthesia is required in more than one region in the body, the risk of toxicity will proportionally increase as the dose of the local anesthetics used is increased. In recent years, increased diversity of anesthetic applications and easier access in clinics to medical tools such as ultrasonography equipment have provided a significant decrease in the required doses of local anesthetics. Discussing in the light of the current literature, this paper reports a bilateral infraclavicular block performed on a patient with bilateral distal radius fracture by using low doses of local anesthetic agents.

Keywords: infraclavicular block; ultrasound; regional anesthesia

Öz

Periferik sinir blokajı, genel anestezi gerektirmeyen ya da yüksek riskli olan vakalar için iyi bir alternatif tekniktir. Vücudun birden fazla bölgesinde bölgesel anestezinin gerekli olduğu durumlarda lokal anestezi dozları arttıkça toksisite riski de orantılı olarak artmaktadır. Son yıllarda anestezi uygulamalarının daha çeşitli hale gelmesi ve kliniklerde ultrasonografi ekipmanları gibi tıbbi araçlara daha kolay erişilebilmesi, gereken lokal anestezi dozunda önemli bir azalma sağlamıştır. Mevcut literatürün de gözden geçirildiği bu yazıda, bilateral distal radius kırığı olan bir hastaya düşük doz lokal anestezi ajan kullanılarak uygulanan bilateral infraklaviküler blok bildirilmiştir.

Anahtar Sözcükler: infraklaviküler blok; ultrason; bölgesel anestezi

Mehmet Sargın,
Mehmet Selçuk Uluer

Konya Eğitim ve Araştırma Hastanesi,
Anesteziyoloji ve Reanimasyon Kliniği,
Konya, Türkiye

Geliş Tarihi /Received : 06.09.2017
Kabul Tarihi /Accepted: 16.11.2017

DOI: 10.21673/anadoluklin.336887

Sorumlu Yazar/Corresponding Author
Mehmet Sargın
Konya Eğitim ve Araştırma Hastanesi,
Anesteziyoloji ve Reanimasyon Kliniği,
Konya, Türkiye
E-mail: mehmet21sargin@yahoo.com

INTRODUCTION

Brachial plexus block is a reliable and intraoperative regional anesthesia technique that allows for prolonged postoperative analgesia and is frequently used in upper extremity surgeries (1). Although brachial plexus can be blocked by interscalene, supraclavicular, infraclavicular, and axillary approaches, performing upper extremity blocks also has several disadvantages. First, it is a time-consuming process and inconvenient for patients. Another disadvantage is the toxicity risk associated with regional anesthesia. Using decreased amounts of medication in order to avoid the toxicity risk can result in an unsuccessful block. In recent years, the risks and disadvantages associated with anesthesia methods decreased as use of ultrasonography (US) equipment in regional anesthesia has become prevalent, with a reduction in the doses required for regional anesthesia (2).

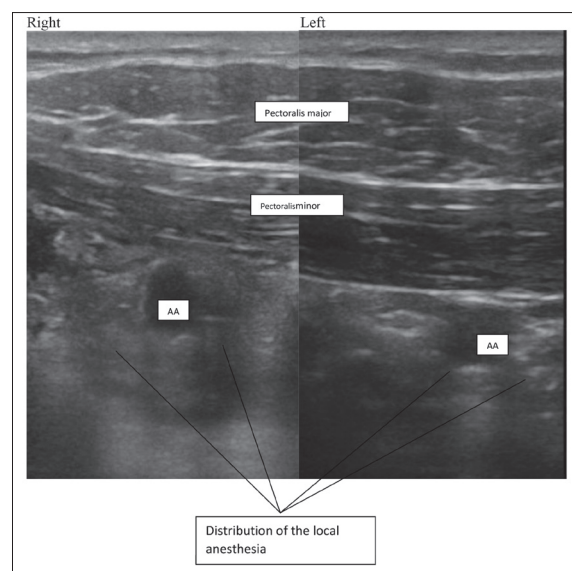
Despite its disadvantages, regional anesthesia is convenient, specifically in cases where general anesthesia is not possible, in multi-trauma cases where there is an emergency for operating, and when the preoperative fasting has not been completed. This paper reports a successful ultrasound-guided bilateral infraclavicular block performed on a patient, who was scheduled for upper extremity surgery after a non-vehicle related traffic accident, by administering local anesthetics in doses lower than routinely used.

CASE REPORT

A patient with bilateral radius fracture was assessed for surgical treatment. The patient was male (80 kg, 175 cm), 27 years old, and had no systemic disease history. He was monitored for physiological signs via electrocardiogram (ECG), and for peripheral blood oxygen saturation (SpO_2) and non-invasive blood pressure (NIBP). He had head trauma with abrasions on the face and scalp, although no pathologic symptoms were detected during computed tomography. No other pathology due to the trauma was observed either. The laboratory tests results were within the normal range. The vital signs of the patient in the operating room were as follows: heart rate: 102/min, arterial blood pressure (non-invasive):

125/78, peripheral oxygen saturation (SpO_2): 93%. For the advantage of postoperative analgesia, bilateral infraclavicular block was performed after obtaining the patient's consent. One mg of midazolam was administered to the patient for sedation. The patient being in the supine position, the head was turned in the opposite direction to that in which the block was performed. The arm where the block was performed was brought to the adduction position and then placed on the upper chest in flexion. Following the disinfection of the region using poly(vinyl pyrrolidone)-iodine complex, the US probe (Mindray 7L4s linerprob, 1 MHz, Shenzhen, China) was sterilely placed longitudinally into the region where the lateral sagittal infraclavicular block was performed (3). Once the images of the axillary artery vein and brachial plexus cords were obtained, an 80-mm-long, 22-gauge, nerve-stimulator needle (Pajunk, Geisinger, Germany) was directed in the 6–7 o'clock position at the artery and placed in the same plane as the US probe. Initially, only 2 ml of local anesthetic solution was used to observe the spread. The remaining local anesthetic solution was administered in divided doses and with negative aspiration.

As the spread of the regional anesthetics around each cord was visualized by means of ultrasonography,



AA: Axillary Artery

Figure 1: Ultrasonographic image of the post-infraclavicular block anatomic structures and distribution of local anesthetics

the injection was performed (Figure 1). This was applied to both upper extremities with the administration of 7 ml 2% prilocaine and 8 ml 0.5% bupivacaine for each. We evaluated sensory (with cold pack) and motor function of both upper limbs. The surgical anesthesia was achieved within 12 minutes on the right and 15 minutes on the left following the drug administration. No specific complication associated with vascular function, regional anesthesia, or the block was observed. No additional sedation or regional anesthetic injection was needed during the operation. The operation took 130 min and was completed without any problems and with minimal discomfort to the patient. At the 6th and 12th postoperative hours, the patient still experienced no discomfort.

DISCUSSION

Ultrasound-guided nerve blockade is a more convenient and efficient method to achieve anesthesia, compared to conventional regional or nerve stimulation techniques. Brachial plexus blockade by using regional or nerve stimulation techniques requires using higher doses of regional anesthetics in comparison to the US-guided blocks. As a result, often general anesthesia rather than brachial plexus blockade is preferred by anesthetists. A disadvantage of bilateral brachial plexus blocks is the toxicity risk associated with the use of high doses of regional anesthetics. For the mentioned reasons, cases that allow for bilateral brachial plexus blockade are limited. Brachial plexus can be blocked by use of interscalene, supraclavicular, infraclavicular, and axillary approaches; and the type of approach depends on the region of operation, the operator's experience, and the patient's anatomy. Interscalene blockade includes a high risk of phrenic nerve injury, and bilateral supraclavicular blockade is avoided as it has a high risk of causing bilateral diaphragmatic paralysis and pneumothorax (5). Considering this information and the fact that US-guidance reduces the risks to a great extent, the authors of the present paper preferred performing a US-guided bilateral infraclavicular block in the reported case. It is noteworthy that brachial plexus blockade provides great advantages, such as perfect analgesia and anes-

thesia, minimal hemodynamic fluctuation, and long postoperative analgesia.

Few bilateral studies on the brachial plexus have been conducted so far. Pai et al. (6) used the supraclavicular approach by administering 6 ml of 2% lidocaine and 18 ml of 0.5% bupivacaine on one side and the axillary approach by administering 8 ml of 2% lidocaine and 30 ml of 0.25% bupivacaine on the other side for bilateral plexus blockade. The two cases of bilateral infraclavicular blockade performed by Sandhu et al. (7) by administering 20 ml lidocaine and sodium bicarbonate (0,9 mEq / 10 ml and epinephrine 1/200000) and by Tekin et al. (8) by administering epinephrine in a similar manner with less regional anesthetics are examples suggesting that US-guidance is successful in decreasing the dose required for regional anesthesia. In the current case, 15 ml of local anesthetic solution was used for infraclavicular application with US-guidance instead of 30 ml. This was less than the dose reported in the literature, given that the authors did not apply to any adjuvant use. As a result, this dose did not cause a decrease in the perioperative quality of the surgical anesthesia. Maurer et al. (9) reported using interscalene approach on one side and infraclavicular approach on the other side for bilateral brachial plexus blockade in their cases. However, it resulted in an unsuccessful block because they did not employ ultrasonography; they only managed to decrease the dose of ropivacaine from 40 ml to 35 ml on both sides.

In conclusion, despite using less regional anesthetics, use of ultrasonography in peripheral nerve blocks improves the success in producing blocks, as well as decreasing the toxicity risk in bilateral cases. In addition, use of ultrasonography reduces intravenous injection risks as it provides the opportunity to visualize the anatomical structures during the operation. Therefore, bilateral infraclavicular blocks can be successfully performed by using decreased doses of anesthetics with the guidance of ultrasonography, without compromising on the quality of the block.

REFERENCES

1. Klein SM, Evans H, Nielsen K, Tucker M, Warner D, Steele S. Peripheral nerve block technique for ambulatory surgery. *Anesth Analg*. 2005;101:1663–76.
2. Marhofer P, Greher M, Kapral S. Ultrasound guidance in regional anaesthesia. *Br J Anaesth*. 2005;94:7–17.
3. Klaastad Ø, Smith HJ, Smedby O, Winther-Larssen EH, Brodal P, Breivik H, et al. A novel infraclavicular brachial plexus block: the lateral and sagittal technique, developed by magnetic resonance imaging studies. *Anesth Analg*. 2004;98(1):252–6.
4. Neal JM, Moore JM, Kopacz DJ, Liu SS, Kramer DJ, Plorde JJ. Quantitative analysis of respiratory, motor, and sensory function after supraclavicular block. *Anesth Analg*. 1998;86(6):1239–44.
5. Franco CD, Salahuddin Z, Rafizad A. Bilateral brachial plexus block. *Anesth Analg*. 2004;98(2):518–20.
6. Pai RV, Hegde HV, Santhosh M, Roopa S, Deshpande SS, Rao PR. Bilateral brachial plexus blocks in a patient of hypertrophic obstructive cardiomyopathy with hypertensive crisis. *Indian J Anaesth*. 2013;57(1):72–5.
7. Sandhu NS, Maharlouei B, Patel B, Erkulwater E, Medabalmi P. Simultaneous bilateral infraclavicular brachial plexus blocks with low-dose lidocaine using ultrasound guidance. *Anesthesiology*. 2006;104(1):199–201.
8. Tekin M, Gürkan Y, Baykal D, Solak M, Toker K. Ultrason rehberliğinde bilateral infraklavikular blok: olgu sunumu. *Ağrı*. 2010;22(1):41–3.
9. Maurer K, Ekatodramis G, Rentsch K, Borgeat A. Interscalene and infraclavicular block for bilateral distal radius fracture. *Anesth Analg*. 2002;94(2):450–2.