

## PAPER DETAILS

TITLE: Anesthesia management and challenges during interventional pulmonology procedures for central airway obstructions

AUTHORS: Gülay ÜLGER,Hilal SAZAK,Melahat UZEL SENER,Ayperi ÖZTÜRK,Musa ZENGİN,Ali ALAGÖZ

PAGES: 328-333

ORIGINAL PDF URL: <https://dergipark.org.tr/tr/download/article-file/2499771>

# Anesthesia management and challenges during interventional pulmonology procedures for central airway obstructions

İGülay Ülger<sup>1</sup>, İHilal Sazak<sup>1</sup>, İMelahat Uzel Şener<sup>2</sup>, İAyperi Öztürk<sup>2</sup>, İMusa Zengin<sup>1</sup>, İAli Alagöz<sup>1</sup>

<sup>1</sup>University of Health Sciences, Ankara Atatürk Chest Diseases and Thoracic Surgery Training and Research Hospital, Anesthesiology and Reanimation Clinic, Ankara, Turkey

<sup>2</sup>University of Health Sciences, Ankara Atatürk Chest Diseases and Thoracic Surgery Training and Research Hospital, Interventional Pulmonology Clinic, Ankara, Turkey

**Cite this article as:** Ülger G, Sazak H, Uzel Şener M, Öztürk A, Zengin M, Alagöz A. Anesthesia management and challenges during interventional pulmonology procedures for central airway obstructions. *Anatolian Curr Med J* 2022; 4(4); 328-333.

## ABSTRACT

**Aim:** Central airway obstructions (CAO) are one of the main reasons for morbidity and mortality, often originate in the lungs, and are generally unresectable. Interventional airway procedure is a preferred method in these cases. This study aimed to analyze anesthesia management in patients undergoing interventional procedures for CAO. We aimed to highlight the problem and solutions that may be encountered in such cases.

**Material and Method:** The data of 49 patients who had interventional airway procedure were analyzed retrospectively. Patients' demographic data, type of interventional procedures, localization of the lesion, and duration of the procedure were analyzed. Vital parameters and arterial blood gases (ABG) levels had been recorded before anesthesia induction (T1), after rigid bronchoscope insertion (T2), 20th-minute of the procedure (T3), after extubation (T4), and in the postoperative care unit (T5).

**Results:** The mean age was 57.90±11.99 years. The mean duration of the procedure was 34.75±15.62 minutes. The majority of the patients had American Society of Anesthesiologists (ASA) III-IV physical status. CAOs were mostly found in the main bronchus. Tumors debulking, biopsy, mechanical dilatation, argon plasma coagulation, and mechanical tumor resection were the most performed procedures. Stent insertion was performed in 3 (6.1%) patients. Two patients (4.1%) had bleeding, 3 (6.1%) patients had desaturation, and 1 (2.1%) patient had atrial fibrillation.

**Conclusion:** Interventional airway procedures are frequently used for high risk patients with CAO and comorbidities. Detailed preoperative evaluation, periprocedural teamwork, and close hemodynamic and ABG follow-up are keys to success.

**Keywords:** Anesthesia, argon plasma coagulation, central airway obstruction, cryotherapy, interventional pulmonology, rigid bronchoscopy

## INTRODUCTION

Central airway obstructions are one of the main causes of morbidity and mortality. Central airway obstructions (CAO) often originate in the lungs and are generally unresectable (1,2). The increase in lung cancer cases in recent years has also increased the incidence of CAO in the main airways (2). The major bleeding, atelectasis, pneumonia, and dyspnea are complications associated with CAO (2,3).

Advances in interventional pulmonology procedures are improving the treatment of patients with complex airway pathology caused by both benign and malignant diseases (1-3). Cryotherapy and argon plasma coagulation (APC) are among the techniques used for the treatment of

CAO. During these techniques, a rigid bronchoscope is required for majority of the cases (1-3). General anesthesia is the preferred method for most of the procedures with rigid bronchoscopy (1-4). Perioperative management of patients with CAO is a very difficult process for anesthesiologists. Most of the patients have often American Society of Anesthesiologist (ASA) III/IV physical status, major comorbidities, and almost complete airway obstruction. During procedures for these patients, sharing airway with the pulmonologist make the process even more complicated for the anesthesiologist (5-8). For these reasons, meticulous perioperative management and collaboration between the anesthesiologists and the interventional pulmonologists are crucial to reduce the mortality and morbidity rate.

Our objective was to analyze challenging circumstances and solutions for anesthesia management in patients undergoing interventional procedures for CAO. We have retrospectively analyzed patients' perioperative data.

## MATERIAL AND METHOD

The study was approved by the Ankara Atatürk Sanatorium Training and Research Hospital Clinical Researches Ethics Committee (Date: 25.05.2022, Decision No: 2012-KAEK-15/2518). Medical records of 49 patients undergoing interventional airway procedures due to CAO between July 2019 and July 2020 were analyzed. All procedures were carried out in accordance with the ethical rules and the principles of the Declaration of Helsinki. The following information was available on the records: Patients' age, gender, body mass index (BMI), ASA physical status, type of the interventional procedure, localization of the lesion, the presence of comorbidities, duration of the procedure, and Modified Aldrete Score (MAS) to identify recovery time.

### Anesthesia Protocol

The same total intravenous anesthetic procedure had been performed in all patients. Two large bore intravenous catheters had been inserted into the patients. 3 minutes after pre-oxygenation, 1 mg.kg<sup>-1</sup> lidocaine, 1 mg.kg<sup>-1</sup> methyl prednisolone, 2 mg.kg<sup>-1</sup> propofol, 1 mg.kg<sup>-1</sup> rocuronium and 0.5 µg.kg<sup>-1</sup> remifentanyl had been administered for anesthesia induction. Fentanyl was not used to avoid coughing (9). After 90 seconds, patients had been intubated with a rigid bronchoscope, and ventilated manually. During rigid bronchoscopy, leak compensation had been achieved by a continuous flush with 100% oxygen. A radial artery catheter had been inserted to monitor the blood pressure and arterial blood gases (ABG) measurements. Adequate PaO<sub>2</sub> and PaCO<sub>2</sub> levels had been achieved with peripheral oxygen saturation (SpO<sub>2</sub>) monitoring and intermittent ABG measurements. Maintenance of anesthesia had been performed by using propofol (50-75 µg.kg<sup>-1</sup>.min<sup>-1</sup>) and remifentanyl (0.025-0.05 µg.kg<sup>-1</sup>.min<sup>-1</sup>) infusions adjusted to hemodynamic response. Additional rocuronium doses had been administered, and at the end of the procedure, the rocuronium effect had been reversed by administering 2-4 mg.kg<sup>-1</sup> sugammadex intravenously. Ventilation was maintained with a standard semi-closed circuit. The ventilator was connected to the side port of the rigid bronchoscope with the circuit. Additionally, high flows (>12 L/min, up to 20 L/min) were used to compensate for leaks in the system (10). Throughout the procedures, ventilation was provided manually with instant follow-up and leak compensation. The patient's follow-up was coordinated between the anesthetists and the pulmonologists with close communication and observation.

All complications and adverse events were recorded during and after the procedure. After the intervention, patients had been followed in the postoperative care unit (PACU) until complete recovery. Recovery time was determined by using MAS records. The time to reach MAS 9-10 after discontinuation of anesthetic agents was accepted as the recovery time.

Throughout the procedure electrocardiography, SpO<sub>2</sub> measurements, and invasive arterial blood pressure monitorizations were performed. Systolic arterial pressure (SAP), diastolic arterial pressure (DAP), mean arterial pressure (MAP), heart rate (HR), SpO<sub>2</sub>, the pH, PaO<sub>2</sub>, and PaCO<sub>2</sub> values recorded before anesthesia induction (T1), after rigid bronchoscope insertion (T2), after 20th-minute of procedure (T3), after extubation (T4), and in the PACU (T5) were analyzed. Additionally, the effects of BMI, age, and procedure time on recovery time were evaluated.

### Interventional Procedures

All of the interventional procedures were performed by two interventional pulmonologists. According to the lesion location and size, after insertion of the rigid bronchoscope, suitable procedures of APC, mechanical tumor resection, cryobiopsy, cryotherapy, mechanical dilatation or stent placement procedures were used.

### Statistical analysis

Statistical analysis of the study was made with SPSS for Windows 16.0 package program. Normality analyzes of variables were performed using the Shapiro Wilk test. Variables are expressed as mean-standard deviation in normally distributed parameters and median-interquartile range in non-normally distributed parameters. Comparison between the two dependent groups for the normally distributed parameter was performed by the Paired Samples T-test. Comparison between two dependent groups was performed using the Wilcoxon Test and the Repeated Measures ANOVA test, while the Friedman test was used for the analysis of non-normally distributed dependent multiple variables. Comparison between independent multiple groups for the normally distributed parameter was made with the one-way Anova-test, and the Kruskal-Wallis test for non-normally distributed parameters; Bonferroni correction was applied when analyzing the subgroups. Spearman correlation test was used for non-normally distributed boxed correlation and Pearson test was used for normal distribution boxed correlation. p-value<0.05 was accepted as statistically significant.

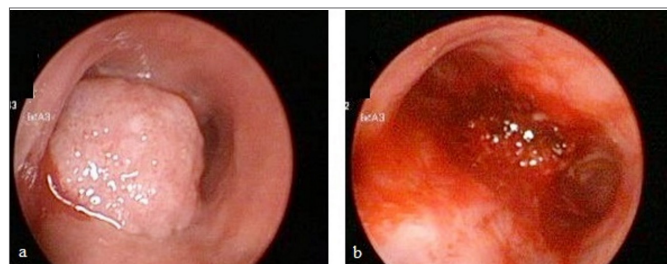
## RESULTS

Data of 49 patients were analyzed. Demographic characteristics, ASA physical status, duration of the procedure, localization of the lesion, and recovery time are shown in **Table 1**. Patients had different comorbidities. 16 (32.6%) of the patients had hypertension, 11 (22.4%) had diabetes mellitus, 11 (22.4%) had cardiac diseases, 6 (12.2%) had chronic obstructive pulmonary disease, 6 (12.2%) had extrapulmonary malignancy, 2 (4.1%) had cerebrovascular diseases, and 5 (10.2%) had other coexisting diseases.

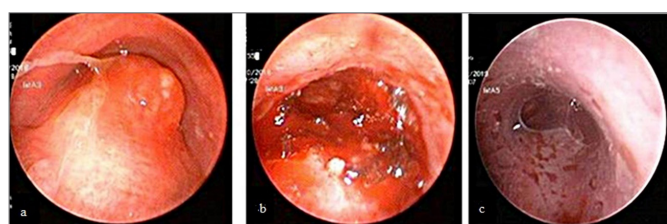
Table 1. Demographical and clinical characteristics of patients		
	n: 49	Min-max
Age (year) (mean±sd)	57.90± 11.99	23-83
Gender (F/M) n-%	9-22.5 / 40-81.5	-
BMI (kg/m <sup>2</sup> ) (mean±sd)	25.61±4.88	16.11-40.40
Duration of procedure (min) (mean±sd)	34.75 ± 15.62	9-82
Recovery time (sec)	195.61±118.62	60-600
ASA (2/3/4) n-%	2-4.1 / 36-73.4 / 11-22.5	-
Localization of airway lesion		
Trachea-carina (n-%)	12-24.4	-
Bronchus (n-%)	32-65.3	-
Tracheobronchial (n-%)	5-10.02	-

Data presented as mean±standard deviation, percentage, and minimum-maximum. ASA: American Society of Anesthesiologists; BMI: Body mass index, MAS: Modified Aldrete Score.

Tumor debulking was performed in the majority of the patients (**Figure 1a**, **Figure 1b**). Dilatation and cryotherapy were applied in 4 (8.2%) patients, while foreign body removal was performed in 2 (4.1%) patients. Stent insertion was performed in 3 (6.1%) patients (**Figure 2a**, **Figure 2b**, **Figure 2c**, **Table 2**).



**Figure 1. 1a.** Tumor almost completely obstructing the left and right main bronchi in the carina of the trachea. **1b.** After debulking, view of the carina.



**Figure 2. 2a.** Endotracheal tumor obstructing the airway. **2b.** After debulking, the view of the trachea. **2c.** View of the trachea after silicone y-stent insertion.

Table 2. Distribution of interventional airway procedures		
Procedures	n:49	%
Debulking		
APC	1	2.1
Cryoextraction	4	8.1
MTR	8	16.4
APC+MTR	2	4.0
Cryoextraction+APC+MTR	19	38.8
Cryobiopsy+APC	6	12.2
Dilatation+ Cryotherapy	4	8.2
Foreign Body Removal	2	4.1
Stent Insertion	3	6.1

Data presented as number and percentage. APC: Argon plasma coagulation, MTR: Mechanical tumor resection.

When the patients'complication were evaluated, 2 patients (4.1%) had bleeding, 3 (6.3%) patients had desaturation, and 1 (2.1%) patient had atrial fibrillation. None of the patients needed nitroglycerin or vasopressor due to hemodynamic changes during the procedure. We didn't encounter any complications during PACU follow-up.

The MAP values were significantly lower after insertion of the rigid bronchoscope according to basal values (T1) ( $p<0.001$ ). When the HR was evaluated according to the basal values (T1), the decrease in the 20<sup>th</sup>-minute (T3) of the procedure was found to be statistically significant ( $p<0.001$ ). The increase in SpO<sub>2</sub> compared to the pre-induction time (T1) was found to be statistically significant when the rigid bronchoscope was inserted (T2), at the 20<sup>th</sup>-minute of the procedure (T3), and after extubation (T4) ( $p<0.001$ ). When ABG were evaluated, pH was found to be lower than basal values (T1) at all times. According to the basal value (T1), PaO<sub>2</sub> values were found to be statistically higher during rigid bronchoscope insertion (T2), at 20<sup>th</sup>-minute (T3) and after extubation (T4) ( $p<0.001$ ). In PACU (T5), the PaO<sub>2</sub> values were found to be significantly lower, however, the values are clinically within normal limits. PaCO<sub>2</sub> values were found to be high at the time of rigid bronchoscope insertion (T2), at the 20<sup>th</sup>-minute of the procedure (T3) and after extubation (T4) when compared to the time before induction (T1) ( $p<0.001$ ) (**Table 3**). There was no correlation between recovery time and BMI, age, and duration of procedure ( $p>0.05$ ).

## DISCUSSION

Our study showed that most of the patients had ASA III-IV physical status and comorbidity. Tumor debulking procedure with cryoextraction and mechanical tumor resection were performed on the majority of the patients. During the interventional procedure we observed stable hemodynamic trend and oxygenation, even if we found acceptable alterations particularly in pH and PaCO<sub>2</sub> levels. We also found limited and acceptable complications during the procedures.



**Table 3.** Vital parameters and arterial blood gas values of patients during procedure

Variables	T1	T2	T3	T4	T5	p
MAP* (mmHg)	95.0±19.6	75.6 ±20.1	93.8±22.2	101.5±19.7	97.3±15.9	<0.001
HR* (beat/min)	96.0±13.9	96.7±10.8	90.5±11	94.4±12.6	92.5±13.3	0.002
SpO <sub>2</sub> ** (%)	94 (92-97)	98 (98-98)	97 (91-98)	95 (93-96)	93 (91- 96)	<0.001
pH**	7.49 (7.43 -7.53)	7.42 (7.36 -7.45)	7.29 (7.26 -7.32)	7.32 (7.29-7.42)	7.43 (7.41-7.46)	<0.001
PaCO <sub>2</sub> ** (mmHg)	34.7 (31.1-42.1)	39.4 (36.3-43.9)	56.5 (49.6-62.8)	45.6 (43-57.9)	36.3 (33.1-38.1)	<0.001
PaO <sub>2</sub> ** (mmHg)	98.1 (71.2-174.3)	248.5 (220.6-320.3)	213.5 (99.9-345.8)	142.9 (118.6-160.7)	73.4 (60.1-80.8)	<0.001

\*rmANOVA \*\*Friedman. p &lt; 0.005: According to T1. Data presented as mean and standard deviation and mean min-max.

HR: Heart rate; MAP: Mean arterial pressure; PaCO<sub>2</sub>: Partial arterial carbondioxide; PaO<sub>2</sub>: Partial arterial oxygen; SpO<sub>2</sub>:Peripheral oxygen saturation.

Anesthesia management for interventional pulmonology in patients with CAO poses a real challenge (5-8). These patients have severe dyspnea due to existing lung disease, severe comorbidities, and high ASA physical status (8). In addition, maintaining hemodynamic stability and providing adequate depth of anesthesia with anesthetic drugs is more difficult in elderly ages due to possible pharmacokinetic and pharmacodynamic changes (11-13). Therefore, for these patients, preoperative evaluation is very important. In the perioperative period, a detailed of evaluation of these problems and jointly decided procedure by the interventional pulmonology team is crucial for the successful management of anesthesia (7,14). The condition and the location causing the obstruction should be evaluated with a multidisciplinary approach. Since dyspnea is common in these patients, the position in which the patients are comfortable should be evaluated for dyspnea. If there occurs an airway collapse during the procedure, this evaluation can help to determine the position to be used during anesthesia induction (15). In this study, preoperative evaluation was done in collaboration with anesthesiologists and pulmonologists.

Anesthesia induction is another critical step in patients with CAO. Premedication before the procedure can be done if the general condition of the patients is suitable. However, it should be done carefully considering the serious problems that respiratory depression can cause in these patients who already have limited pulmonary reserves (15, 16). Premedication with atropine and glycopyrrolate, which were frequently used in the past, are no longer preferred (17). Additionally, for a possible airway collapse during anesthesia induction, the pulmonologist should be present and the rigid bronchoscope should be placed quickly (5, 16). In this study, premedication was not administered before induction of anesthesia, and none of the patients required emergency airway management due to airway collapse.

Anesthesia management during treatment is another critical step in patients with CAO. Patients with

respiratory distress require O<sub>2</sub> support and cannot lie in the supine position. Muscle relaxants eliminate muscle tone that keeps the airway open (3, 5, 18, 19). Performing rigid bronchoscopy under deep sedation in which spontaneous breathing is preserved, can be an alternative to general anesthesia (20). However, in deep sedation, the possibility of hypoventilation, laryngospasm, insufficient relaxation of the laryngeal muscles, coughing, or involuntary movement of the patient make it difficult to insert the rigid bronchoscope into the trachea and the work of the team. It has been reported that intravenous induction of anesthesia in patients with CAO should be fast and smooth, and prevent airway irritation (20, 21). For these reasons, propofol and remifentanyl, short-acting intravenous anesthetic agents, should be preferred for anesthesia induction and maintenance (21). Usage of muscle relaxant agents with rapid onset of action is also reasonable to enable fast insertion of rigid bronchoscope after induction with intravenous anesthetic agents. Succinylcholine is a depolarizing neuromuscular blocking agent with rapid onset and rapid recovery, which has been used since the 1950s (22). However, succinylcholine is less preferred due to the frequency of undesirable and serious side effects. Additionally, as in this study, it may be more appropriate to use muscle relaxants with moderate duration such as rocuronium, since prolonged muscle relaxation may be needed in the procedures where complex interventional procedures are required (23). Rocuronium, usage at a dose of 1 mg.kg<sup>-1</sup>, provides rapid intubation around 60 seconds (24). One of the most important advantages of rocuronium is that it allows fast reverse after the procedure by using intravenous sugammadex. This important feature of rocuronium also allow rapid recovery in the case of possible intubation problems (25). In this study, we use the same anesthetic method with rocuronium to all patients and sugammadex was used to reverse the effects of rocuronium. We didn't encounter any intubation or extubation related complications. We believe that usage of rocuronium-sugammadex combination is an effective method to prevent problems during intubation and extubation period.

Ventilation is mostly performed through rigid bronchoscopy by conventional method or high frequency jet ventilation (21). In patients with severe airway obstruction, experienced personnel and appropriate adjustment of the jet ventilator are important for solving problems such as ventilation problems, carbon dioxide retention, and the risk of barotrauma (26,27). A ventilator is connected to the side port of the rigid bronchoscope with a standard semi-closed circuit. This is a conventional ventilation method for interventional bronchoscopy. High flows are (>12 L/min, up to 20 L/min) usually necessary to compensate for leaks in the system (10). In the study throughout the procedures, the conventional ventilation method was used. The ventilation was provided manually with instant follow-up and leak compensation. The patient's follow-up was coordinated between the anesthesiologist and the pulmonologist with close communication and observation. Barotrauma, severe carbon dioxide elevation and long recovery time were not observed in any of the patients during the procedures.

Bleeding, hypoxia, hypercarbia, and barotrauma are common complications during interventional bronchoscopy (26,27). In addition to the underlying comorbidities of the patients, the severity of the CAO also plays an essential role in the development of these complications (21,23). Comprehensive and multidisciplinary perioperative evaluation and preparation are crucial to prevent these complications. In the operating room, alternative airway equipments and devices; such as small-diameter intubation tube, double lumen intubation tube, high-frequency jet ventilator, and fluoroscopy should be available in case of acute life-threatening complications such as bleeding, pneumothorax, and unpredicted airway obstructions (5).

Monitoring of hemodynamic parameters and ABG measurements are frequently required follow-up methods in patients with CAO. Massive bleeding and sudden changes in hemodynamic parameters may occur in these patients, especially because of malign airway CAO. Additionally, sharing the airway with the pulmonologist and air leaks caused by the rigid bronchoscope may prevent effective ventilation. This insufficiency can often cause especially hypercarbia and hypoxia in patients (28, 29). In this study, invasive arterial pressure monitoring and intermittent ABG measurements were performed to ensure the safety of the interventional treatment and ventilation under general anesthesia. Stable hemodynamic parameters were achieved in these patients during the procedure, and moderate changes in pCO<sub>2</sub> and pH were observed in ABG measurements consistent with the literature. Furthermore, we did not encounter any serious problems that caused the process to be terminated.

There are different interventional treatment options to manage CAO through the rigid bronchoscope such as dilation of the tracheobronchial system, electrocautery, laser therapy, cryotherapy, brachytherapy, APC or insertion of airway stents (1,18). Argon gas is applied through a probe and is ionized into a plasma by contacting a high voltage electric current at the tip of the probe. Then It conducts a monopolar electric current to the proximal target lesion (30, 31). APC is a thermal modality and thus has similar airway fire risks as other thermal modalities. The risk of airway perforation is theoretically much lower than electrocautery and laser (32). Because of this feature, APC is a commonly used method especially for the treatment of complex vascular tumors or the lesions that tend to bleed. One of the most fearful complications due to APC is fire and airway burning because of the principle of the APC. Maintaining inspired concentration of oxygen at lower than 40% mostly is performed during APC application (33). In this study we disconnected the ventilator circuit during APC in coordination with the interventional bronchoscopy team. We didn't observe any fire and airway burning related to the APC procedure.

We have some limitations in this study. First, patients' data were collected retrospectively in a single center. Additionally, since mechanical ventilation with the conventional method is a routine method used in our center, no comparison could be made with jet ventilators and other methods. Prospective and comparative studies with a large number of patients are needed on anesthetic management in patients with CAO. Second, noninvasive methods such as transcutaneous carbon dioxide measurement and bispectral index monitorization could be also used. Due to the unavailability of these devices in our clinic at the time of these procedures, we could not use them. However, we thought that invasive arterial pressure monitoring and periodic ABG measurements could be sufficient in patients with CAO.

## CONCLUSION

Patients with CAO have generally poor conditions. The mandatory simultaneous usage of the airway with the pulmonologist, performing the interventional procedure, makes the anesthesia management more difficult in such patients. Anesthesia management should conduct an appropriate preoperative assessment, maintain intraoperative convenient ventilation, use proper anesthesia agents and ensure perioperative close follow up. As a result, a multidisciplinary approach provided by skilled bronchoscopists and experienced anesthesiologists is essential in the interventional treatment of patients with CAO.

## ETHICAL DECLARATIONS

**Ethics Committee Approval:** The study was approved by the Ankara Atatürk Sanatorium Training and Research Hospital Clinical Researches Ethics Committee (Date: 25.05.2022, Decision No: 2012-KAEK-15/2518).

**Informed Consent:** Because the study was designed retrospectively, no written informed consent form was obtained from patients.

**Referee Evaluation Process:** Externally peer-reviewed.

**Conflict of Interest Statement:** The authors have no conflicts of interest to declare.

**Financial Disclosure:** The authors declared that this study has received no financial support.

**Author Contributions:** All of the authors declare that they have all participated in the design, execution, and analysis of the paper and that they have approved the final version.

## REFERENCES

- Ernst A, Feller-Kopman D, Becker HD, Mehta AC. Central airway obstruction. *Am J Respir Crit Care Med* 2004; 169: 1278-97.
- Ayers ML, Beamis JF Jr. Rigid bronchoscopy in the twenty-first century. *Clin Chest Med* 2001; 22: 355-64.
- Noppen M, Meysman M, D'Haese J, Schlessen M, Vincken W. Interventional bronchoscopy: 5-year experience at the Academic Hospital of the Vrije Universiteit Brussel (AZ-VUB). *Acta Clin Belg* 1997; 52: 371-80.
- Beyazit Y, Tanoglu A, Kekilli M, Kurt M. Successful Management of an Esophageal Foreign Body with a Rigid Bronchoscopy. *Medicine Science*. 2015; 4: 2340-43.
- El-Dawlatly A, Alnassar S, Abodonya A, Almutlaq N, Hajjar W. Anesthetic considerations of central airway obstruction. *Saudi J Anaesth* 2011; 5: 326-8.
- José RJ, Shaefi S, Navani N. Anesthesia for bronchoscopy. *Curr Opin Anaesthesiol* 2014; 27: 453-7.
- de Lima A, Kheir F, Majid A, Pawlowski J. Anesthesia for interventional pulmonology procedures: a review of advanced diagnostic and therapeutic bronchoscopy. *Can J Anaesth* 2018; 65: 822-36.
- McMahon CC, Rainey L, Fulton B, Conacher ID. Central airway compression. Anesthetic and intensive care consequences. *Anaesthesia* 1997; 52: 158-62.
- Abdullayev R, Akçaboy EY, Akçaboy ZN, Tiryaki HC, Bavullu EN, Göğüş N. Fentanile bağlı olarak görülen öksürüğe deksmedetomidinin etkisi. *Türk J Anaesth Reanim* 2013; 41, 80-3.
- Goudra BG, Singh PM, Borle A, Farid N, Harris K. Anesthesia for advanced bronchoscopic procedures: state-of-the-art review. *Lung* 2015; 193: 453-65.
- Bavullu EN, Aksoy E, Abdullayev R, Göğüş N, Dede D. Comparison of dexmedetomidine and midazolam in sedation for percutaneous drainage of hepatic hydatid cysts. *Türk J Anaesthesiol Reanim* 2013; 41: 195-9.
- Zengin M, Baldemir R. Anesthesia management in geriatric patients which were interventional bronchoscopy due to central airway obstruction; retrospective analysis. *Anatolian Curr Med J* 2022; 4; 39-43.
- Zengin M, Alagoz A. Comparison of thoracic epidural analgesia and thoracic paravertebral block applications in the treatment of acute pain after thoracotomy in geriatric patients. *Cureus* 2021; 13; 10, e18982.
- Bolliger CT, Mathur PN, Beamis JF, et al; European Respiratory Society/American Thoracic Society. ERS/ATS statement on interventional pulmonology. *European Respiratory Society/American Thoracic Society. Eur Respir J* 2002; 19: 356-73.
- Schleicher A, Groeben H. Anesthetic considerations for tracheobronchial surgery. *Journal of Thoracic Disease* 2020; 12: 6138-42.
- Semmelmann A, Loop T. Anesthesia for interventional pulmonology. *Curr Opin Anaesthesiol* 2022; 35: 82-8.
- Abdelmalak BB, Doyle DJ. Updates and controversies in anesthesia for advanced interventional pulmonology procedures. *Curr Opin Anaesthesiol* 2021; 34: 455-63.
- Selzer AR, Murrell M, Shostak E. New trends in interventional pulmonology. *Curr Opin Anaesthesiol* 2017; 30: 17-22.
- Bakan M, Topuz U, Umutoğlu T, et al. Remifentanyl-based total intravenous anesthesia for pediatric rigid bronchoscopy: comparison of adjuvant propofol and ketamine. *Clinics (Sao Paulo)* 2014; 69: 372-7.
- Conacher ID, Curran E. Local anaesthesia and sedation for rigid bronchoscopy for emergency relief of central airway obstruction. *Anaesthesia* 2004; 59: 290-2.
- Pathak V, Welsby I, Mahmood K, Wahidi M, MacIntyre N, Shofer S. Ventilation and anesthetic approaches for rigid bronchoscopy. *Ann Am Thorac Soc* 2014; 11: 628-34.
- Sparr HJ, Jöhr M. Succinylcholin-Update [Succinylcholine--update]. *Anaesthesist* 2002; 51: 565-75.
- Pawlowski J. Anesthetic considerations for interventional pulmonary procedures. *Curr Opin Anaesthesiol* 2013; 26: 6-12..
- Han TH, Martyn JA. Onset and effectiveness of rocuronium for rapid onset of paralysis in patients with major burns: priming or large bolus. *Br J Anaesth* 2009; 102: 55-60.
- Lee C, Jahr JS, Candiotti KA, Warriner B, Zornow MH, Naguib M. Reversal of profound neuromuscular block by sugammadex administered three minutes after rocuronium: a comparison with spontaneous recovery from succinylcholine. *Anesthesiology* 2009; 110: 1020-5.
- Putz L, Mayné A, Dincq AS. Jet Ventilation during rigid bronchoscopy in adults: a focused review. *Biomed Res Int* 2016; 4234861.
- Evans E, Biro P, Bedford N. Jet ventilation. *Contin Educ Anaesthesia Critical Care & Pain* 2007; 7: 2-5.
- Dincq AS, Gourdin M, Collard E, et al. Anesthesia for adult rigid bronchoscopy. *Acta Anaesthesiol Belg* 2014; 65: 95-103.
- Fernandez-Bustamante A, Ibañez V, Alfaro JJ, et al. High-frequency jet ventilation in interventional bronchoscopy: factors with predictive value on high-frequency jet ventilation complications. *J Clin Anesth* 2006; 18: 349-56.
- Platt RC. Argon plasma electrosurgical coagulation. *Biomed Sci Instrum* 1997; 34: 332-7.
- Grund KE, Storek D, Farin G. Endoscopic argon plasma coagulation (APC) first clinical experiences in flexible endoscopy. *Endosc Surg Allied Technol* 1994; 2:42-6.
- Mudambi L, Miller R, Eapen GA. Malignant central airway obstruction. *J Thorac Dis*. 2017; 9: 1087-110.
- Morice RC, Ece T, Ece F, Keus L. Endobronchial argon plasma coagulation for treatment of hemoptysis and neoplastic airway obstruction. *Chest* 2001; 119: 781-7.