

## PAPER DETAILS

TITLE: Is Extrafacial Rosacea or the Coexistence of Rosacea and Polymorph Light Eruption?

AUTHORS: Çağrı TURAN,Özlem TANAS ISIKÇI,Hatice Meral EKSIOGLU

PAGES: 132-135

ORIGINAL PDF URL: <https://dergipark.org.tr/tr/download/article-file/803898>

## IS EXTRA FACIAL ROSACEA OR THE COEXISTENCE OF ROSACEA AND POLYMORPH LIGHT ERUPTION?

## EKSTRAFASİYAL ROZASE MI, ROZASE VE POLİMORF IŞIK ERÜPSİYONU BİRLİKTELİĞİ MI?

Çağrı TURAN<sup>1</sup>, Özlem TANAS İŞİKÇİ<sup>2</sup>, Hatice Meral EKŞİOĞLU<sup>3</sup>

## ABSTRACT

Rosacea is readily diagnosed in the clinical practice and may unusually present with extrafacial involvement. This clinical picture, known as extrafacial rosacea, has been reported to be confused with various diseases besides photodermatoses in the literature. Coexistence with polymorphic light eruption and rosacea have not been reported to date as far as we know, and here we present a case displaying that this coexistence should come to mind in patients if extrafacial rosacea is considered.

**Keywords:** Rosacea, extrafacial rosacea, polymorphic light eruption

## ÖZET

Klinikte kolaylıkla tanı konulan rozase çok nadir de olsa atipik şekilde yüz dışında tutulumu ile de karşımıza çıkabilmektedir. Ektrafasial rozase olarak bilinen bu tablonun literatürde fotodermatozlar dışında çeşitli hastalıklarla da karıştırıldığı belirtilmiştir. Polimorf ışık erüpsiyonu ve rozase birlikteliği bildiğimiz kadarıyla bugüne kadar bildirilmemiş olup burada bu birlikteliğin ektrafasial rozase düşünülen hastalarda akla gelmesi gerektiğini gösteren bir olgu sunulmaktadır.

**Anahtar Kelimeler:** Rozase, ektrafasial rozase, polimorf ışık erüpsiyonu

<sup>1</sup> University of Health Sciences, Erzurum Regional Training and Research Hospital, Department of Dermatology and Venereology, Erzurum, Turkey

<sup>2</sup> University of Health Sciences, Ankara Health Training and Research Centre, Department of Pathology, Ankara, Turkey

<sup>3</sup> University of Health Sciences, Ankara Health Training and Research Centre, Department of Dermatology and Venereology, Ankara, Turkey

Geliş Tarihi / Submitted : Eylül 2019 / September 2019

Kabul Tarihi / Accepted : Ağustos 2020 / August 2020

## Sorumlu Yazar / Corresponding Author:

Çağrı TURAN

University of Health Sciences, Erzurum Regional Training and Research Hospital, Department of Dermatology and Venereology, Erzurum, Turkey

Atatürk Mahallesi, Çat Yolu Cd., Palandöken/Yakutiye/Erzurum-Post Code: 25070, Turkey.

Gsm: +90 544 525 25 04 Phone: +90 442 232 55 55

E-mail: cagrituranmd@gmail.com

## Yazar Bilgileri / Author Information:

Çağrı TURAN (ORCID: 0000-0002-6111-4314),

Özlem TANAS İŞİKÇİ (ORCID: 0000-0003-0864-3425)

Gsm: +90 505 485 52 83 E-mail: oztanas@gmail.com,

Hatice Meral EKŞİOĞLU (ORCID: 0000-0003-0172-4548)

Gsm: +90 532 513 63 35 E-mail: meral\_eksioglu@yahoo.co.uk

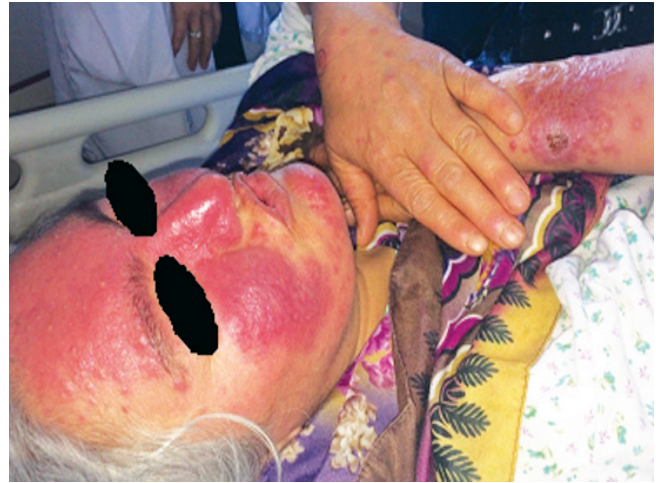Olgu sunumu olup etik kurul onayı gerekmemektedir. Olgudan yazılı izin alınmıştır.

## INTRODUCTION

Rosacea is usually easily recognized in clinical practice with its typical history and clinical findings, though its presentation with extrafacial involvement can be confusing, which can sometimes cause difficulty in diagnosis. We would like to present this phenomenon to emphasize that it is necessary to include the concurrence of “rosacea and polymorphic light eruption (PLE)” in the differential diagnosis of this unusual picture, which is known as extrafacial rosacea (ER).

### Case

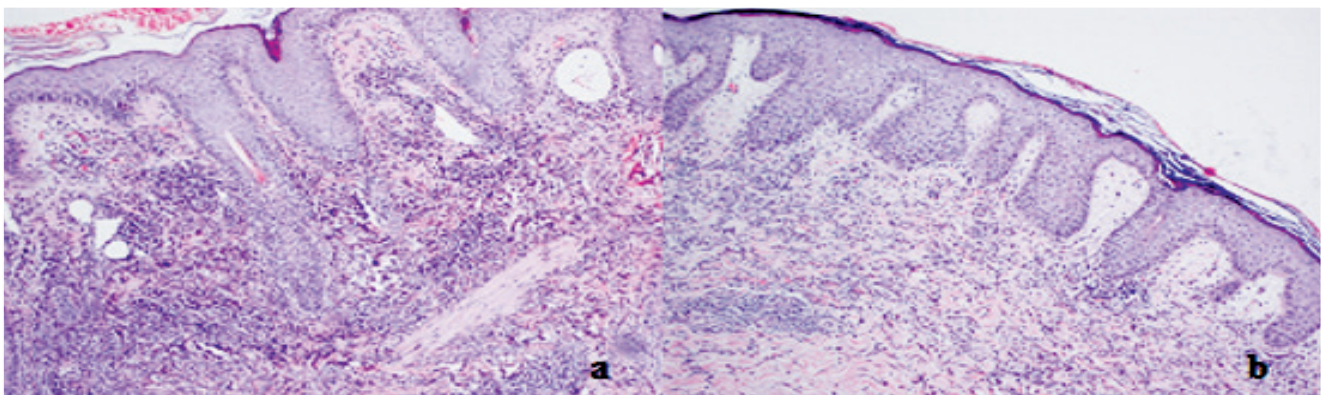
A 47-year-old female patient was admitted in May 2018 with an itchy lesion that started on the right forearm two and a half weeks ago and markedly increased on the face and over her arms after intense sun exposure 5 days ago. It was learned that the complaints in her arms first appeared at the beginning of the summer season last year, and there was a known rosacea history for two years. Patient with known hypothyroidism and diabetes mellitus has denied any drug use except levothyroxine and metformin. She had no photosynthetic food consumption story. Her personal and family history was unremarkable. Systemic findings and laboratory findings were normal. On the dermatologic examination, numerous papules and pustules on erythematous and edematous plaques in the malar areas, nose, forehead, chin, and telangiectasia in the bilateral malar areas were observed. In the right forearm, an erythematous, edematous plaque at the size of 5x9 cm, with an about 1 cm hemorrhagic crust in its center and several erythematous papules in the bilateral forearm and hand dorsum were observed (**Figure 1**). The histopathological examination of the face revealed mild perifolliculitis, dermal telangiectatic vessels and lymphohistiocytic cells (**Figure 2a**). The histopathological examination of the forearm revealed acanthosis, spongiosis in the epidermis and marked edema in papillary dermis (**Figure 2b**). Topical steroids were applied to lesions in his forearms, topical 10% sulphur cream on her face was recommended, and 100 mg/day systemic doxycycline was initiated. After 2 weeks, the complaints of the patient, except for a residual erythema, significantly improved.



**Figure 1: Papulopustular lesions on the centrofacial erythematous and edematous plaque, telangiectasia in malar areas; pronounced erythematous, edematous plaques and papules especially in the right forearm.**

### Discussion

Extrafacial rosacea was first described in 1967 by Fountain and Sarkany, who reported a patient with typical rosacea findings affecting the face and neck accompanied by papules on the arm and wrist. In 1969, Marks and Jones published a large series of 14 cases, including the case of Fountain and Sarkany, previously defined as ER (1). However, in 1963 Ayra reported papulopustular lesions in the bald scalp region of a male patient as “rosacea-like demodicosis” (2). Although the term ER is not used, it may be claimed that this is actually the first case reported in the literature. The case series reported by Marx and Jones were mean  $48 \pm 10.7$  (18-61 years) years old and most were female (male/female: 4/10) with accompanying eye involvement in 5 patients. These patients with neck, forearm, upper arm, leg, thigh, wrist, hand-foot dorsum, finger, chest and hip involvement accompanying the facial involvement of the patients were described as “disseminated rosacea” (1). Later, in a small number of case series and case reports, patients with ER who have the presternal area, back, nipple, abdominal region, scalp and



**Figure 2a: Mild perifolliculitis, dermal telangiectatic vessels and lymphohistiocytic cells (Face, Hematoxylin EosinX10)**  
**Figure 2b: Acanthosis, spongiosis in the epidermis and marked edema in papillarydermis (Forearm, Hematoxylin EosinX10)**

interestingly salivary gland involvement were reported (3-5). Palmoplantar involvement has not been reported in the literature. ER lesions are similar to facial rosacea lesions clinically and histopathologically (1). When the Turkish and English literature is reviewed, there are about 50 reported male predominant cases, unlike the largest series reported by Mark and Jones. Rosacea and PLE are more common in women (6,7).

The presence of typical rosacea findings in almost all of the ER-diagnosed patients suggests that the etiopathogenesis and triggering factors are similar. Despite the fact that erythematotelangiectatic, papulopustular rosacea are dominant in the cases described, episodic and fulminant rosacea have also been observed in a small number of cases (1,7,8).

Considering the limited number of reported cases, it can be thought that ER is extremely rare. There is no extensive prevalence study in the literature. Dupont evaluated 138 rosacea patients in 1986 for extrafacial involvement and reported that only 3 (2 females, 1 males) had telangiectatic papules in the neck region (9).

Although the diagnosis of the patients was not supported by biopsy, it is thought that extrafacial involvement may occur in 2.2% of patients with rosacea. Although it facilitates excluding the concurrence of PLE and rosacea because the papules are telangiectatic, the lack of biopsy still suggests this suspicion. ER may be thought to be frequently overlooked in clinical practice due to diagnostic difficulty. The extrafacial areas in which rosacea may arise should be routinely examined in facial rosacea patients and extrafacial involvement of rosacea should not be missed in the differential diagnosis of photodermatoses.

The most common disease among photodermatoses is PLE, which usually occurs in women aged 20-40 years after exposure to intense sunlight. There may be lesions ranging from symmetric, itchy papules, reticulo-erythemas, papulo-vesicles, plaques, vesicles and erythema multiforme-like lesions, especially in sun-exposed areas (6). Contrary to the "polymorphic variety" in the clinic, each patient has a monomorphic pattern that usually occurs in the same regions. Crust or scar development may be seen in cases where lesions are irritated by intense itching, as in our case even though they are not included in the usual clinical picture. In fact, it is important to distinguish rosacea from PLE that are rarely seen in areas such as face and are constantly exposed to sunlight during winter. ER involvement areas include those of the PLE. The involvement of non-sun-exposed areas, the presence of ocular involvement, and the duration of complaints are useful in distinguishing the ER from the PLE. The monomorphic nature of the PLE and the similar picture of the ER in the face and peripheral regions will make the distinction of these 2 diseases difficult, although the presence of other triggers such as alcohol, pain, heat, stress in addition to the sun is suggestive of ER. Approximately half of the patients

reported by Mark and Jones with definite histopathologic diagnoses had symptoms similar to PLE at the end of spring. This suggests that the combination of the two diseases should not be missed. In such ER cases in the literature have been reported to be initially treated with false diagnoses such as seborrheic dermatitis, tinea incognito, contact dermatitis (5,7,10-12). The coexistence of PLE and ER whose pathogenesis and histopathology are different is plausible as both are photodermatoses; though it has not been reported so far to the best of our knowledge. However, in our opinion, some cases thought to be ER and not confirmed by a biopsy may actually have such coexistence. In the literature, this possibility is not discussed before as far as we know.

The presence of papulopustular lesions on the basis of centrofacial erythema and telangiectasia in the present patient suggested rosacea and the diagnosis was confirmed by biopsy. The presence of papules and plaques with clinical features similar to the lesions in the face and the bilateral forearms suggested the diagnosis of ER. However, the fact that the patient had similar lesions in his forearms 1 year earlier and at the beginning of the summer, extrafacial lesions after the intense sun exposure, the absence of vascular ectasia, perifollicular infiltration in biopsy, and the presence of the significant papillary edema led to the PLE diagnosis that accompanied the rosacea picture.

In conclusion, in some patients thought to have ER, especially if the triggering factor is thought to be the sun, and the episodic picture is available, history and examination may be required to confirm the diagnosis, even if consistent with rosacea and a biopsy of the extrafacial lesion may be required to exclude the PLE. Direct immunofluorescence may also be required to exclude subacute lupus erythematosus in some patients. In the literature, the association of rosacea and PLE has not been reported before as far as we know. The present case offers an opportunity to stress that this rare coexistence should be kept in mind in the differential diagnosis of ER.

The patient has received the "informed consent form" approval. There is no conflict of interest.

## REFERENCES

- 1.) Marks R, Jones EW. Disseminated rosacea. *Br J Dermatol*. 1969;81:16-28. doi: 10.1111/j.1365-2133.1969.tb15915.x
- 2.) Ayres S, Jr. Extrafacial rosacea is rare but does exist. *J Am Acad Dermatol*. 1987;16:391-2. doi: 10.1016/S0190-9622(87)80138-X
- 3.) Plewig G, Jansen T, Kligman AM. Pyoderma faciale: A review and report of 20 additional cases: is it rosacea?. *Arch Dermatol*. 1992;128:1611-7. doi: 10.1001/archderm.1992.04530010049007
- 4.) Bostanci O, Borelli C, Schaller M. Treatment of extrafacial rosacea with low-dose isotretinoin. *Acta Derm Venereol*. 2010;90:409-10. doi: 10.2340/00015555-0888
- 5.) Ohata C, Saruban H, Ikegami R. Granulomatous rosacea affecting the lacrimal and salivary glands. *Arch Dermatol*. 2004;140:240-2. doi: 10.1001/archderm.140.2.240-b

- 6.)Oakley AM, Ramsey ML. Polymorphic Light Eruption. StatPearls Publishing LLC.; 2018. Available at: <https://www.ncbi.nlm.nih.gov/books/NBK430886>. Eriřim tarihi 12.05.2019 (Accessed May 12, 2019.)
- 7.)Aydođan K, Adım řB, Tunalı ř. Ekstrafasiyal Rozasea: Olgu Sunumu ve Literatürün Gözden Geçirilmesi. Türkiye Klinikleri Journal of Dermatology. 2004;14:156-61.
- 8.)Haugstvedt A, Bjerke JR. Rosacea fulminans with extrafacial lesions. Acta Derm Venereol. 1998;78:70-1. PMID: 9498036
- 9.)Dupont C. How common is extrafacial rosacea?. J Am Acad Dermatol. 1986;14:839. doi: 10.1016/S0190-9622(86)80532-1
- 10.)Smith LA, Meehan SA, Cohen DE. Rosacea fulminans with extrafacial lesions in an elderly man: successful treatment with subantimicrobial-dose doxycycline. J Drugs Dermatol. 2014;13:763-5. PMID: 24918570
- 11.)Katugampola G, Lanigan S. A case of extrafacial rosacea responding to topical metronidazole. J Dermatolog Treat. 1998;9:111-3. doi: 10.3109/09546639809161382
- 12.)Erbađcı Z, Erbađcı İ, Tuncel AA. Ekstrafasiyal Rozasea: İki Olgu Sunumu. Türkiye Klinikleri Journal of Dermatology. 2006;16:197-200.

Ankara Eđt. Arř. Hast. Derg. (Med. J. Ankara Tr. Res. Hosp.), 2020 ; 53(2) : 132-135

Olgu sunumu olup etik kurul onayı gerekmemektedir. Olgudan yazılı izin alınmıřtır.