

PAPER DETAILS

TITLE: Van kedilerinde Cytauxzoonosis

AUTHORS: Mehmet KARACA, Hasan Altan AKKAN, Mehmet TTNC, Nalan ZDAL, Serdar
DEGER, Zahid T AGAOGLU

PAGES: 37-39

ORIGINAL PDF URL: <https://dergipark.org.tr/tr/download/article-file/146591>

Cytauxzoonosis In Van Cats

Mehmet KARACA¹, Hasan Altan AKKAN¹, Mehmet TÜTÜNCÜ¹,
Nalan ÖZDAL², Serdar DEĞER², Zahid T. AĞAOĞLU¹

Depts. of ¹Internal Medicine, ²Parasitology, Faculty of Veterinary Medicine, University of Yüzüncü Yıl, 65080, Campus, Van, TURKEY

Sorumlu Araştırmacı-0505 3562949, vetmkaraca@hotmail.com

Summary: Cytauxzoonosis; the disease is known as cat's theileriosis is a high rate fatal disease transmitted by tick and causes by *Cytauxzoon felis*, a protozoon, which has shizogony period in both erythrocytes and macrophages. In the present study, the presence of *Cytauxzoon felis* in Van cats was aimed to investigate. In this study, 120 Van Cats aged between 1-7 and in different sexes were used as materials. For this purpose, routine hematological and biochemical analyses were performed. Clinically, symptoms related to the disease were not observed. Blood smears were also prepared from all cats. Examination of the smears revealed 9 (7.5%) cats had *Cytauxzoon felis* in their blood.

As a result, *Cytauxzoon felis* which determined first time in Turkey was present at 7.5% ratio. But specific clinical symptoms for the disease were not present possibly due to preimmunity. Therefore, these cats should be examined in terms of *Cytauxzoon felis* especially during summer season not only microscopically but also serologically.

Key words: Van cat, *Cytauxzoon felis*, microscopic examination.

Van Kedilerinde Cytauxzoonosis

Özet: Cytauxzoonosis; kedilerin theileriosis'i olarak da bilinen, kedilerde yüksek oranda ölümlere yol açabilen, keneler ile bulaşan ve eritrositler formları ile makrofajlarda doku şizogoni fazına sahip *Cytauxzoon felis*'in neden olduğu bir protozoon hastalığıdır. Çalışmada 1-7 yaş arasındaki 120 adet Van kedisinde klinik ve hematolojik muayeneler yapıldı. Kedilerde klinik olarak herhangi bir semptomla rastlanmadı. Kan örneklerinden hazırlanan frotilerin mikroskopik muayenesinde 9 (% 7,5) kediye *Cytauxzoon felis* etkeni belirlendi.

Sonuç olarak; Türkiye'de varlığı ilk defa tespit edilen *Cytauxzoon felis*'e Van kedilerinde %7,5 oranında rastlandı. Ancak kedilerde muhtemelen oluşan preimmünisyon nedeniyle hastalığa ilişkin spesifik semptomlar görülmeydi. Bu nedenle, özellikle yaz aylarında kediler sadece mikroskopik olarak değil aynı zamanda serolojik olarak *C. felis* yönünden incelenmelidir.

Anahtar kelimeler: Van kedisi, *Cytauxzoon felis*, mikroskopik muayene.

INTRODUCTION

In cat and lynx, cytauxzoonosis is a protozoon disease caused by *Cytauxzoon felis* and can be progressed with high mortality. The disease is known as cat's theileriosis. *Cytauxzoon felis* has 0.5-2 µm dimentions. Erythrocytic form of *Cytauxzoon felis* is seen as round, oval, ring and tetrad shapes under light microscope. It's schizogony period occurs in spleen, liver and lymph nodules (3, 6, 8) as it happens in other theileria species. The disease progresses with high fever, paleness, jaundice, and asphexia followed by dehydration, severe lethargia, and general paresia (6, 8, 12).

Diagnosis of the disease is made by seeing the agents in the erythrocytes in blood smears stained by Giemsa. Furthermore, tissue phase of the agent is established in bone marrow or

mononuclear phagocytes of the spleen, or serologically using Indirect Fluorescent Antibody test (6, 8, 11, 12).

In experimental studies, it has been reported that the agent is carried by tick species belong to *Dermacentor variabilis*. In cytauxzoonosis cases, lynx has been indicated for the natural reservoir and long term carrier of the disease in South and South-East district of USA (1, 2, 9). Despite the disease causes to death in lynx, it usually causes to parasitemia which hides from clinic observations and this case reduces the rate of the death of the animals (4, 5, 7, 10). In domestic cat and lynx, the reason for death due to *Cytauxzoon felis* is depend on the development of schizonts in mononuclear phagocytes rather than parasitemia. In the present study, *Cytauxzoon felis* cases determined first time in Van cats in Turkey believed to be presentable.

MATERIAL and METHOD

In the study, 120 Van cats which were obtained from Research Center for Van Cat, in different age (1-7 years old) and sex were used. Clinical, haematological and ectoparasite examinations were made on the cats. Blood smears obtained from the cats were stained with Giemsa staining and investigated for *C. felis* under light microscope.

RESULTS

In the study, no symptom of Cytauxzoonosis was observed in the cats examined in this study. The number of erythrocytes and haematocrit values were in normal physiological limits. No ectoparasite was found in the cats. Examination of the blood samples of the cats revealed that 9 cats (7.5%) had the *Cytauxzoon felis* agent. The agents of the *Cytauxzoon felis* with different appearances are given in figure 1.

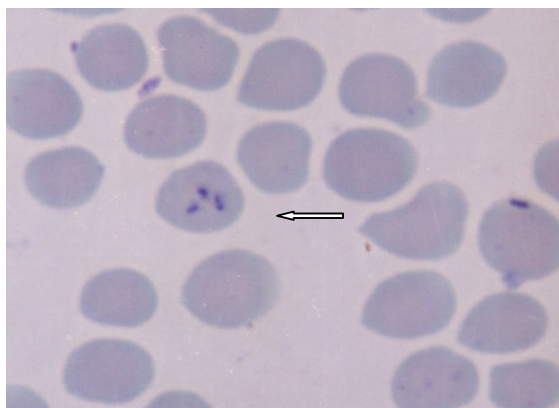


Figure 1: Parachute form of *Cytauxzoon felis* (Giemsa x 400)

REFERENCES

1. Blouin EF, Kocan AA, Glenn BL, Kocan KM, Hair JA (1984): Transmission of *Cytauxzoon felis* Kier, 1979 from bobcats, *Felis rufus* (Scheber), to *Dermacentor variabilis* (Say). J. Wildl Dis. 20, 241-242.
2. Blouin EF, Kocan AA, Kocan KM, Hair J (1987): Evidence of a limited schizogonous cycle for *Cytauxzoon felis* in bobcats following exposure to infected ticks. J. Wild Dis. 23, 499-501.
3. Butt MT, Bowman D, Barr MC, Roelke ME (1991): Iatrogenic transmission of *Cytauxzoon felis* from a Florida panther (*Felis concolor coryi*) to a domestic cat. Journal of Wildlife Disease.; 27, 342-347.
4. Cowell RL, Fox JC, Tyler RD (1988): Feline Cytauxzoonosis. Compend. Contin. Educ. Pract. Vet. 10, 731-736.
5. Franks PT, Harvey JW, Shields RP, Lawman MJP (1988): Hematological findings in experimental feline Cytauxzoonosis. J. American Animal Hosp. Assoc. 24, 395-401.
6. Fraser CM, Bergeron JA, Mays A, Aiello SE (1991): The Merck Veterinary Manual. Seventh Ed. Merck & Co., Inc. Rahway, N.J., USA, p: 72.
7. Glenn BL, Stair EL (1984): Cytauxzoonosis in domestic cats: report of two cases in Oklahoma, with a review and discussion of the disease. JAVMA, 184, 822-825.

DISCUSSION and CONCLUSION

It has been reported that cytauxzoonosis progresses with high fever, paleness, jaundice, asphyxia and lethargia in addition to the high rate of death in domestic cats (6, 8, 12). In this study, no clinical symptoms mentioned above and death was observed in the cats which had *Cytauxzoon felis*. Similar findings were also reported by other workers (12).

No tick species belong to *Dermacentor variabilis* were found on the cats. Furthermore, no study has been performed in the region about the same tick species that cause the disease and the role of lynx in the spread of the disease.

Despite the reports expressing the decrease in the number of erythrocytes and haematocrit values, both the number of erythrocytes and haematocrit values were in physiological limits in the present study. A possible explanation for this result can be made by the results of Walker and co-workers (12) in which it has been expressed that low parasitemia, preimmunity of the animals, infection of the cats with lower virulent agents or an unknown immunity against to the disease could affect haematologic findings.

In conclusion, this study demonstrates first time the presence of *Cytauxzoon felis* in Van Cats (7.5%) in Turkey. Preimmunity against the parasite, which can be occurred in many blood parasites, may prevent to observe the clinical symptoms of this parasite caused. Especially clinical symptoms caused by this parasite must be taken into consideration in summer. In addition to clinical examinations, using microscopic and serologic methods is important in the diagnosis of the disease. Additional investigations on the presence of the *Dermacentor variabilis* and the role of other tick species in the transmission of the disease should be done.

8. Hoover JP, Walker DB, Hedges JD (1994): Cytauxzoonosis in cats: Eight cases (1985-1992). JAVMA, 205, 3: 455-460.
9. Kier AB, Wightman SR, Wagner JE (1982): Interspecies transmission of Cytauxzoon felis. American J. Vet. Res. 43, 102-105.
10. Kier AB (1984): Cytauxzoonosis. In: Green, C.E ed. Microbiology and infectious disease of the dog and cat. Philadelphia: W.B Saunders Co, 791-795.
11. Uilenberg G, Franssen FFJ, Perie NM (1987): Relationships between *Cytauxzoon felis* and African piroplasmids. Veterinary Parasitology. 26: 1-2, 21-28.
12. Walker DB, Cowell RL (1995): Survival of a domestic cat with naturally acquired cytauxzoonosis. JAVMA. 206, 9:1363-1365.