

PAPER DETAILS

TITLE: AESTHETIC MANAGEMENT OF ANTERIOR TEETH WITH DIRECT COMPOSITE
VENEERS AND BLEACHING AFTER FIXED ORTHODONTIC TREATMENT

AUTHORS: Engin Firat ÇAKAN,Fatma YILDIRIM,Ahu TOPKARA


PAGES: 17-23

ORIGINAL PDF URL: <https://dergipark.org.tr/tr/download/article-file/553840>



Aydın Dental Journal

Journal homepage: <http://dergipark.ulakbim.gov.tr/adj>



AESTHETIC MANAGEMENT OF ANTERIOR TEETH WITH DIRECT COMPOSITE VENEERS AND BLEACHING AFTER FIXED ORTHODONTIC TREATMENT

DergiPark
AKADEMİK

Engin Fırat ÇAKAN¹, Fatma YILDIRIM², Ahu TOPKARA²

ABSTRACT

In present time people consider more about appearance and facial aesthetics according to the past. Person in social communication is perceived by the expression on his/her face. The middle and the lower section of the face where the eyes, the maxilla and the mandible are located, are the primary attention spots and have an undisputed important place in social life. Smile of individuals, reveals the anterior teeth and disrupts or improves the harmony of the face. Therefore, dental aesthetics, which creates an important part of the facial appearance, is a prominent feature of overall aesthetic.

As a result of the development of the adhesive dentistry, aesthetic expectations of the patients are possible to provide by the physicians. The main purpose of the aesthetic treatments in dentistry is to establish the design of a beautiful smile in addition to provide a good function. After dental procedures, especially the appearance of the upper anterior teeth is great importance in terms of patient satisfaction. Although, there are many types of treatment options available for functional and aesthetic problems in the upper anterior region, multidisciplinary treatment approaches are recommended for an optimal treatment.

The aim of this study was to demonstrate anterior aesthetic rehabilitation of a patient who had Angle Class I malocclusion with crowding. Discoloration of anterior teeth due to previous treatments, managed with direct composite veneer following vital and non-vital in-office bleaching after orthodontic treatment.

Keywords: anterior crowding, direct composite veneers, laminate veneers, tooth bleaching

ÖZET

Günümüzde bireyler dış görünüşlerine ve yüz estetiklerine geçmiş zamanlara oranla daha fazla önem vermektedir. Sosyal iletişimde kişi, yüzündeki ifade ile algılanır. Gözlerin bulunduğu yüzün orta bölümü ve maksilla ve mandibulanın bulunduğu alt bölümü, ilk dikkat çeken noktalar ve kişinin sosyal yaşamı içinde tartışmasız önemli bir yer tutmaktadır. Bireylerin gülümsemeleri ön dişleri göz önüne çıkarır ve bu gülümseme yüzün harmonisini bozar ya da geliştirir. Bu nedenle yüz görünümünün önemli bir parçasını oluşturan diş estetiği, ön planda yer almaktadır.

Adeziv diş hekimliğinin gelişimi ve varış noktası sonucunda estetik beklentilerin hekim tarafından sağlanması mümkün hale gelmiştir. Diş hekimliğinde estetik amaçlı yapılan tedavilerde esas amaç, fonksiyonun kazandırılmasının yanı sıra, güzel bir gülüş dizaynının da ortaya konmasıdır. Dental girişimler sonrasında, özellikle üst ön bölge dişlerinin görünümü hasta memnuniyeti açısından büyük önem taşımaktadır. Üst çene anterior bölgedeki fonksiyonel ve estetik problemler için birçok tedavi seçeneği bulunmaktadır; fakat ideal bir tedavi için multidisipliner tedavi yaklaşımları önerilmektedir.

Bu olgu sunumunda, Angle Sınıf I maloklüzyon ve çapraşıklığa sahip olan hastanın, üst çene ortodontik tedavisini takiben, tedavi öncesinde mevcut olan restorasyonlar sonucunda meydana gelen renklenme ve form bozukluklarının, devital ve ofis tipi beyazlatma uygulamaları kombine edilerek, direkt kompozit veneer uygulaması ile estetik rehabilitasyonu sunulacaktır.

Anahtar Kelimeler: diş beyazlatma, direkt kompozit veneer, laminate veneer, ön çapraşıklık

¹Kemerburgaz University, Faculty of Dentistry, Department of Restorative Dentistry, Istanbul, Turkey.

²Istanbul Aydın University, Faculty of Dentistry, Department of Orthodontics, Istanbul, Turkey

INTRODUCTION

In present time people consider more about appearance and facial aesthetics according to the past. The social media determines the desirable appearance, for this reason patients quest to beautify their smiles. The first step in any type of dental therapy is to establish treatment objectives. If the appropriate goals or objectives have not been identified before treatment, it is impossible to achieve the ideal results.¹ So, multidisciplinary treatment approaches are recommended for optimal treatment. Due to the increasing importance of the smile aesthetic which provides confidence-boosting process in social and professional experience, many adult patients prefer orthodontic treatment. Particularly in adult patients, aesthetic solutions should be planned with interdisciplinary strategies as the case requires.² In fact, the primary goal of modern orthodontics is to establish the proper occlusal relationship between the maxillary and mandibular arches while maintaining facial esthetics.³ In order to achieve it, the physician will often have to rely on restorative procedures to reach the optimal esthetic result.⁴

With advances and interest in adhesive dentistry, bleaching of discolored teeth has become popular. Tooth discoloration is a multifactorial event that can be internal or external origin and classified as intrinsic, extrinsic or both according to the etiology and localization of staining.^{5,6} Extrinsic discoloration is caused by chromogenous intake through dietary sources such as tea, coffee, fizzy drinks, wine, tobacco or poor oral hygiene.⁷ Intrinsic discoloration largely results of genetic or metabolic causes such as amelogenesis imperfecta, dentinogenesis imperfecta, dentinal dysplasia, fluorosis and tetracycline intake during tooth development

process. Local reasons such as pulp necrosis, pulp tissue remnants after root canal treatment and endodontic filling materials also may occur intrinsic discoloration.⁵

Intrinsic discoloration involves on enamel, dentin or both of them, while extrinsic discoloration occurs on enamel.⁸ Therefore, extrinsic discoloration can be partly removed with mechanical cleaning and/or brushing with toothpaste; internal discoloration can be eliminated only with bleaching.^{9,10} For non-vital bleaching, 30% sodium perborate and 35% hydrogen peroxide solution used either in combination or separately. There are two basic bleaching techniques for internal discolored teeth: walking and thermocatalytic bleaching.¹¹ In-office bleaching, different concentrations of hydrogen peroxide are applied approximately 45 minutes for each practice 2 to 6 times.⁸ Both of these treatments are used on non-vital teeth for adapting same color harmony.

Lots of people, consider that the best solution is porcelain crowns for highly discolored teeth. Crowns that made by high aesthetic ceramic materials, have potential to provide long-term aesthetics. On the other hand, the number of physicians who accept the applications of adhesive dentistry are increasing. Composite laminate veneer applications, with a conservative approach to protect the natural tooth structure, are an alternative treatment to porcelain crowns.¹² Direct composite veneers indicated as a complementary treatment option to the bleaching, to ensure aesthetic compliance for old restorations, to replace missing tooth tissue or to mask discolored teeth. The aim of this case-report was to demonstrate an anterior aesthetic rehabilitation of a patient who had Angle Class I malocclusion with crowding.

Discoloration of anterior teeth due to previous root canal treatments and restorations, treated with direct composite veneers following non-vital walking and in-office bleaching after orthodontic treatment.

CASE REPORT

A 22-year-old female patient who had Angle Class I malocclusion, crowding and 4 mm midline shift in the maxillary anterior region (Fig 1), was referred to Department of Orthodontics, for existing orthodontic treatment. Patient had started her orthodontic treatment in another clinic and her upper left second premolar teeth was extracted in order to correct upper jaw midline discrepancy. The orthodontist had bonded the ceramic braces just only in the upper teeth (Fig 2). After treatment had started, she had wanted

to continue her treatment in Istanbul Aydin University, Faculty of Dentistry.

Initial case procedures were started when the patient came for the first appointment in faculty clinics. For the assessment of this case; radiographs, photographs and the study cast models were taken. The transverse positions of the maxillary and mandibular midlines were evaluated in postero-anterior cephalogram. There was no skeletal discrepancy between the jaws and it was found that the midline shift was caused from dental asymmetry. Thus, we thought that her previous orthodontist had reached the same conclusion and had chosen the tooth extraction treatment. Before the orthodontic treatment, solving other dental problems is important for oral hygiene recovery. Because it will become so difficult for patient to maintain oral hygiene during the

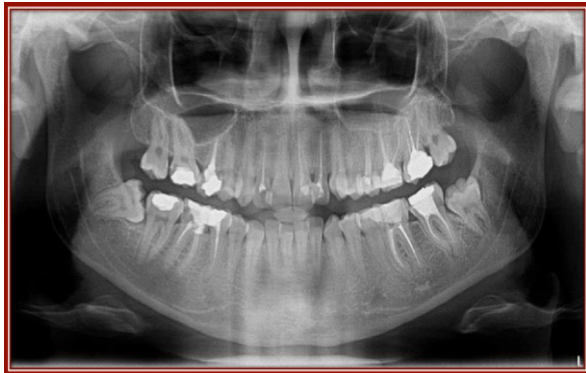

Figure 1 OPG Before Orthodontic Treatment

orthodontic treatment. In this case the physician whom started the orthodontic treatment, was began without taking into account procedures. Patient had periodontal problems and gingival index scores were measured close to 2 because of poor oral hygiene at first arrival. Furthermore, she had discoloration both as existing root canal treatments and as deformed previous restorations. All under these terms, the treatment plan was determined by a multidisciplinary approach.

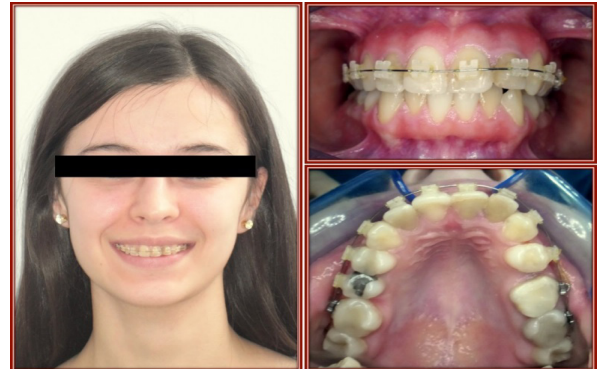

Figure 2 Case Photos (Before)

As a result of treatment planning, periodontal improvement was defined as to be done first. After periodontal treatment was completed, oral health care education and motivation were given and correction of poor oral hygiene was provided. It was decided to continue treatment with existing braces not to prolong the duration of treatment. Therefore, after consultation with Department of Restorative Dentistry, the renewal of restorative treatments and aesthetic improvement were left to the end

of the orthodontic treatment. Depending on the patient's demand, orthodontic treatment has begun only in upper jaw after informed consent form received. To achieve good Class II occlusion at the left side, the extraction space was used to slide and correct the midline.

Over a period of 15 months, orthodontic treatment was completed. On the right side Class I molar occlusion and on the left side full cusp Class II molar occlusion with a Class I canine relationship and 2 mm overjet and overbite for both sides were obtained (Fig 3).

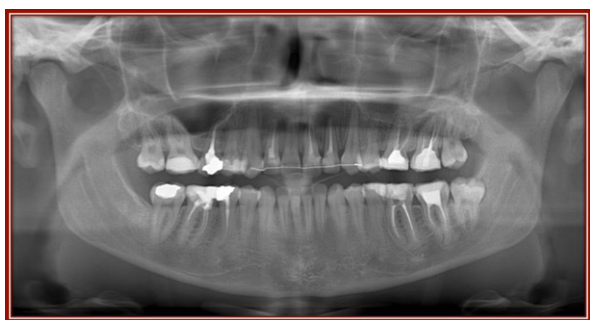

Figure 3 OPG After Orthodontic Treatment

For the treatment of the patient's aesthetic expectations, the patient was referred to the Department of Restorative Dentistry following the end of the orthodontic treatment. During this process, Essix retainers were prepared in order to maintain the treatment outcomes. First of all, when the patient visited to the restorative dentistry clinic, discoloration and color mismatch of the teeth had been focused on. In order to remove tooth discoloration due to pre-made root canal treatment, non-vital walking bleaching was planned. Discolored upper left central and both upper lateral incisors were included to the treatment. Residual supplies in the pulp chamber were cleaned and root canal orifices were closed with glass ionomer cement in hermetic manner. Opalescence Endo (Ultradent Productions Inc, UT, USA), 35% hydrogen peroxide was

applied at first practice and was changed for 3 times in every 4 days. 4 days after the last appointment, the teeth were bleached substantially. To reach the final colors of the root canal treated teeth, Opalescence Endo was cleaned with physiological saline and has been waited for one week. At the beginning of the following week, the pulp chamber was sealed by calcium hydroxide (Sultan Healthcare, PA, USA) for one week to allow elimination of residual oxygen. During this two-week period, in-office bleaching (Philips Zoom WhiteSpeed, Philips, Holland) was done for 2 times, one week apart in 15-minute sessions, to adapt all the teeth. After reaching the final colors of the teeth in the anterior region, the teeth which has degraded aesthetic features, edge harmony, colors and forms, were restored with Composite Laminate Veneers due to extensive borders of restoration (Fig 4). Existent caries and old restorations has been removed in accordance with minimally invasive treatment procedures. A three-step etch-and-rinse bonding agent (Adper Single Bond 2, 3M/ESPE, St. Paul, MN, USA) and a nanofil composite (Filtek Ultimate, 3M/ESPE, St. Paul, MN, USA) were used. The composite increments were placed between the tooth and matrix strip by using hand instruments. Subsequent to polymerization, contouring and finishing were performed with microfine finishing diamonds and restorations were polished using abrasive disks (Sof-Lex, 3M/ESPE, St. Paul, MN, USA) ranging from medium to superfine. At the end of all restorative procedures, fixed lingual retainers were bonded to prevent relapse (Fig 4).

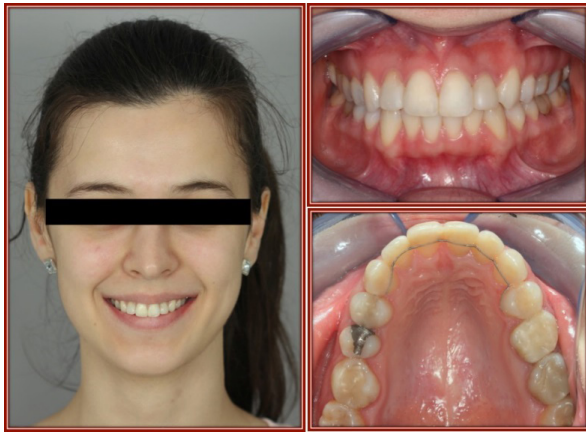

Figure 4 Case Photos (After)

DISCUSSION

Before the beginning of the orthodontic treatment, required process for oral hygiene maintain should be completed. Substantially when the proper teeth positions and optimal occlusion is achieved, orthodontic treatment can be terminated without the need to any other treatment. Depending on the aesthetic expectations, if there is a requirement for the renewal of previous restorations to rearrange the remaining tooth shapes or colors, restorative dentistry should play a part in the finishing phase of the orthodontic treatment.¹³ Physician should determine the treatment objectives, as should meet the requirements of the patient. To meet the treatment needs of patients properly, it is necessary to evaluate all aspects of the case. Constant interaction and communication among the team members and the patient at all level of treatment are the keys to the success of the interdisciplinary treatment.¹⁴

In dental and facial aesthetics, dental midlines relative to each arches and to the face are very important.¹⁵ In diagnosing dental asymmetries, a through clinical examination and radiographic evaluation are necessary. Each dental arches should be evaluated

separately both clinically and by using dental cast models, to accurately determine the bilateral symmetry of the molar and canine positions. In addition to the clinical and dental model evaluation, differentiation between various types of asymmetries can be aided by the use of postero-anterior cephalograms.¹⁶ In this case by using clinical examination, dental cast model evaluation and postero-anterior cephalometric analyses, it was determined that the 4 mm of midline shift to the right side was dentoalveolar.

Through dental asymmetries are often treated asymmetric extraction sequences and asymmetric mechanics.¹⁶ In this case; for to propose of the treatment of the 4 mm of dentoalveolar midline discrepancy, upper left premolar tooth was extracted and upper left canine was distalized 4 mm to correct the midline and the remaining extraction space was closed by anterior mesialization of molar teeth to provide full Class II molar relationship in the left side.

In order to plan aesthetic rehabilitation of discolored teeth, both porcelain and composite laminate veneers may be preferred. Between both treatment options, technical precision and cost should also be considered as well as aesthetic results to be obtained. Porcelain veneers are more resistant to adhesive and cohesive forces. Therefore, when requested to increase the inciso-gingival sizes of the teeth, porcelain laminate veneers should be preferred.^{17,18} Although the composite veneers are aesthetic, they don't provide exactly all the aesthetic properties of dental structures as much as porcelain. In addition to aesthetic properties, good results are obtained with porcelain veneers in terms of satisfaction of patients.^{18,19} However, porcelain veneers require more technical precision and higher costs compared to composite veneers. Due

to providing the aesthetic results in the same appointment, quick application period and comparative low costs, direct composite veneers may be preferred.²⁰ In this case composite laminate veneers were preferred due to aesthetic expectations of the patient, her age and treatment cost in addition to obtain desired level of the patient's tooth color and shapes without changing inciso-gingival sizes of the teeth.

CONCLUSIONS

Smile design should be in full compliance with the facial aesthetic features that were performed in accordance with different perspectives and the combination of different disciplines.

Before and during the orthodontic process, adhesive dentistry and orthodontics collaboration are necessary to facilitate the formation of foresight in the creation of a new smile harmony following orthodontic treatment.

REFERENCES

- [1] Kokich VG. Create realistic objectives. *Am J Orthod Dentofacial Orthop.* 2011; 139(6):713.
- [2] Rodriguez Flores JM. Multidisciplinary orthodontic treatment in adult patients: the future of orthodontics. *Int J Orthod Milwaukee.* 2010; 21(3):11-21.
- [3] Wylie WL. The mandibular incisor-its role in facial esthetics. *Angle Orthod.* 1955; 25:32-41.
- [4] Senty EL. The maxillary cuspid and missing lateral incisor: esthetics and occlusion. *Angle Orthod.* 1976; 46:365-371.
- [5] Nathoo SA. The chemistry and mechanisms of extrinsic and intrinsic discoloration. *J Am Dent Assoc.* 1997; 128 Suppl:6S-10S.
- [6] Hattab FN, Qudeimat MA, al-Rimawi HS. Dental discoloration: an overview. *J Esthet Dent.* 1999; 11(6):291-310.
- [7] Watts A, Addy M. Tooth discolouration and staining: a review of the literature. *Br Dent J.* 2001; 190(6):309-16.
- [8] Ozel Y, Ozel E, Attar N, Aksoy G. Bleaching in dentistry. *EÜ Dişhek Fak Derg* 2007; 28: 33-40.
- [9] Zantner C, Derdilopoulou F, Martus P, Kielbassa AM. Randomized clinical trial on the efficacy of 2 over-the-counter whitening systems. *Quintessence Int.* 2006; 37(9):695-706.
- [10] Yap AU, Wattanapayungkul P. Effects of in-office tooth whiteners on hardness of tooth-colored restoratives. *Oper Dent.* 2002; 27(2):137-41.
- [11] Attin T, Paqué F, Ajam F, Lennon AM. Review of the current status of tooth whitening with the walking bleach technique. *Int Endod J.* 2003; 36(5):313-29.
- [12] Roberson TM, Heymann HO, Swift Jr EJ. *Sturdevant's Art and Science of Operative Dentistry.* 5th ed. Mosby Inc, Missouri. 2006; p:637-648.
- [13] Kokich VG, Spear FM. Guidelines for managing the orthodontic-restorative patient. *Semin Orthod.* 1997; 3(1):3-20.
- [14] Savana K, Ansari A, Hamsa R, Kumar M, Jain A, Singh A. Interdisciplinary therapy in orthodontics: an overview. *Int J Advanced Health Sci.* 2014; 1(5):23-31.
- [15] Burstone CJ. Diagnosis and treatment planning of patients with asymmetries. *Semin Orthod.* 1998; 4(3):153-64.
- [16] Bishara SE, Burkey PS, Kharouf JG. Dental and facial asymmetries: a review. *Angle Orthod.* 1994; 64(2):89-98.
- [17] Jordan RE. *Esthetic Composite Bonding Techniques and Materials.* St. Louis, Mosby-Year Book, Inc. 2nd ed. 1993; p:84-86,132-134,140,150.

- [18] Peumans M, Van Meerbeek B, Lambrechts P, Vanherle G. Porcelain veneers: a review of the literature. J Dent. 2000; 28(3):163-77.
- [19] Meijering AC, Roeters FJ, Mulder J, Creugers NH. patients' satisfaction with different types of veneer restorations. J Dent. 1997; 25(6):493-7.
- [20] Chiche GJ, Pinault A. Esthetics of anterior fixed prosthodontics. Chicago, Quintessence. 1994; p:42-46.