

PAPER DETAILS

TITLE: A forgotten cause of myocardial infarction in an octogenarian patient: Type 1 Kounis Syndrome

AUTHORS: Tarik YILDIRIM,Seda Elcim YILDIRIM

PAGES: 165-167

ORIGINAL PDF URL: <https://dergipark.org.tr/tr/download/article-file/911455>

BALIKESİR MEDICAL JOURNAL

A forgotten cause of myocardial infarction in an octogenarian patient: Type 1 Kounis Syndrome

Yaşlı hastada miyokart infarktüsünün nadir bir nedeni: Tip 1 Kounis sendromu

Tarık Yıldırım¹, Seda Elcim Yıldırım¹

1-Balıkesir Üniversitesi Tıp Fakültesi Kardiyoloji Anabilim Dalı, Balıkesir/ Türkiye

Öz

81 yaş erkek hastaya, aile hekimi tarafından, diz ağrısı nedeni ile, nonsteroid antiinflamatuar bir ilaç olan diklofenak sodium başlanmış. 100 mg diklofenak sodium intramuskuler verildikten 30 dakika sonar şiddetli göğüs ağrısı ve jeneralize eritem başlayan hasta ambulansla acil servise getirildi. Göğüs ağrısı nedeniyle çekilen EKG’de, D2, D3 aVF leadlerinde 2-3 mm ST elevasyonu diğer leadlerde resiprokal değişiklikler saptandı (Figure 1). Acil olarak katater laboratuvarına alınan hastaya yapılan koroner anjiyografide koroner arterlerin normal olduğu tespit edildi (Figure 2,3). Sonrasında Tip 1 Kounis tanısı konulup intravenöz antihistaminik ve 40 mg prednizolon uygulandı. Hasta 2. gün taburcu edildi. Yaşlı hastalarda da tip 1 Kounis sendromu olabileceğini akıldan tutmamız gerekir.

Anahtar Kelimeler: Kounis sendromu, diklofenak,

Abstract

A non-steroidal antiinflammatory drug, diclofenac sodium, was initiated to 81 year-old male patient for his knee pain by a general practitioner. After 30 minutes of ingestion of 100 mg diclofenac sodium, severe chest pain and generalized erythema had started and he was brought to our emergency department by the ambulance staff. Owing to the chest pain , an ECG was performed and it revealed 2-3 mm ST segment elevation in DII-DIII and aVF leads and reciprocal changes in other leads (Figure 1A). Immediately the patient underwent to catheter laboratory and the coronary angiogram showed normal coronary arteries without any obstruction (Figure 2,3). Then Kounis Type 1 was diagnosed and intravenous antihistaminic and 40 mg of prednisolone was administered. The patient was discharged on the second day. Our case is an example of type 1 Kounis syndrome in an octogenarian patient which we should keep in mind.

Keywords: Kounis syndrome, diclofenac,

Gönderilme Tarihi: 31-07-2019
Kabul Tarihi: 21-12-2019

Atıf İçin: Tarık Yıldırım, Seda Elcim Yıldırım, A forgotten cause of myocardial infarction in an octogenarian patient: Type 1 Kounis Syndrome Balıkesir Medical Journal,2019 3(3);165-167

Sorumlu Yazar: Tarık Yıldırım
Balıkesir Üniversitesi Tıp Fakültesi Kardiyoloji Anabilim Dalı,
Balıkesir/ Türkiye
e-mail: kdrtarik@gmail.com

DOI: 10.33716/bmedj.599198

A forgotten cause of myocardial infarction in an octogenarian patient: Type 1 Kounis Syndrome

A non-steroidal antiinflammatory drug diclofenac sodium was initiated to 81 year-old male patient for his knee pain by a general practitioner. After 30 minutes of ingestion of 100 mg diclofenac sodium, severe chest pain and generalized erythema had started and he was brought to our emergency department by the ambulance staff.

Owing to chest pain an ECG was performed and it revealed 2-3 mm ST segment elevation in DII-DIII and aVF leads and reciprocal changes in other leads (Figure 1). Immediately the patient underwent to catheter laboratory and the coronary angiogram showed normal coronary arteries without any obstruction (Figure 2,3).

Then Kounis Type 1 was diagnosed and intravenous antihistaminic and 40 mg of prednisolone were administered (1). The patient was discharged on the second day. Our case is an example of type 1 Kounis syndrome in an octogenarian patient which we should keep in mind.

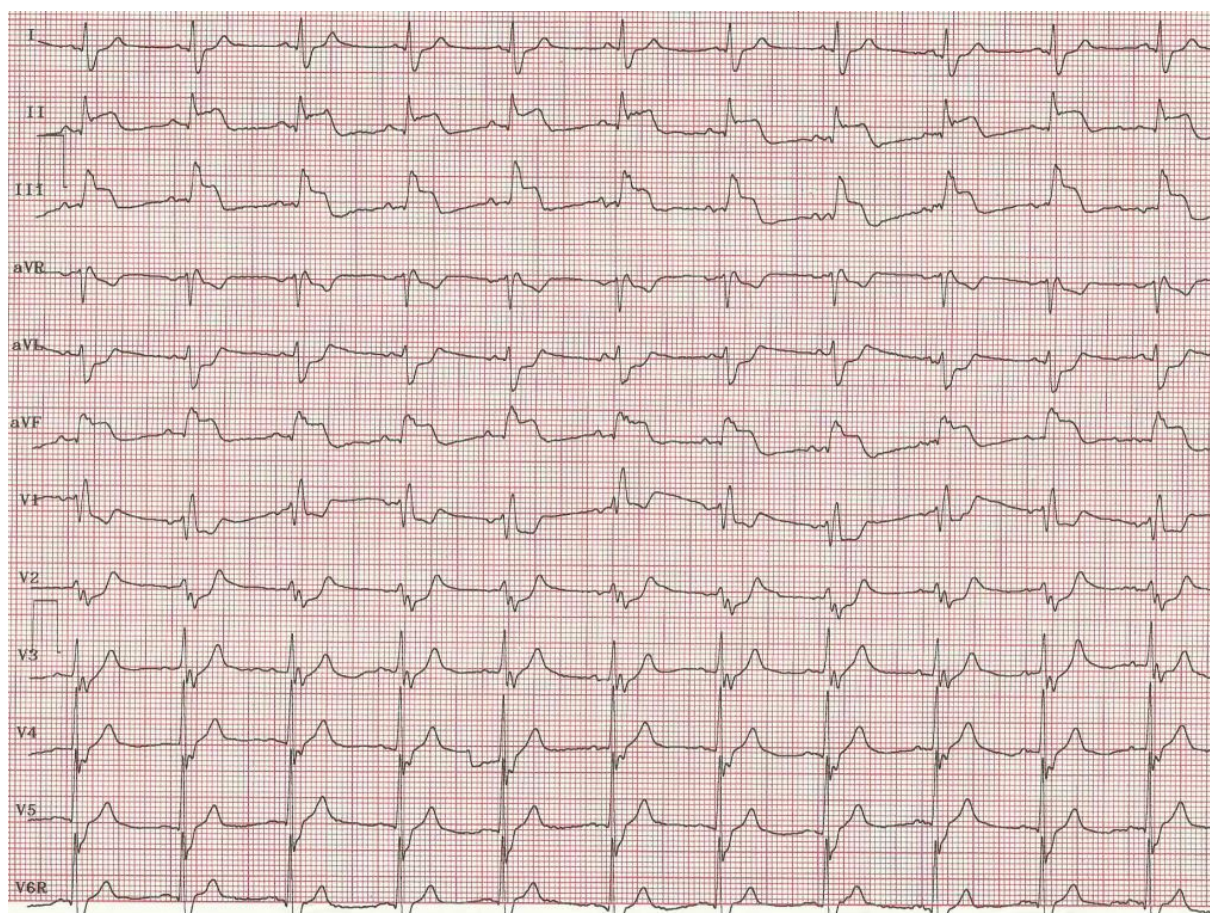


Figure 1. ST segment elevation in leads D2, D3 and aVF

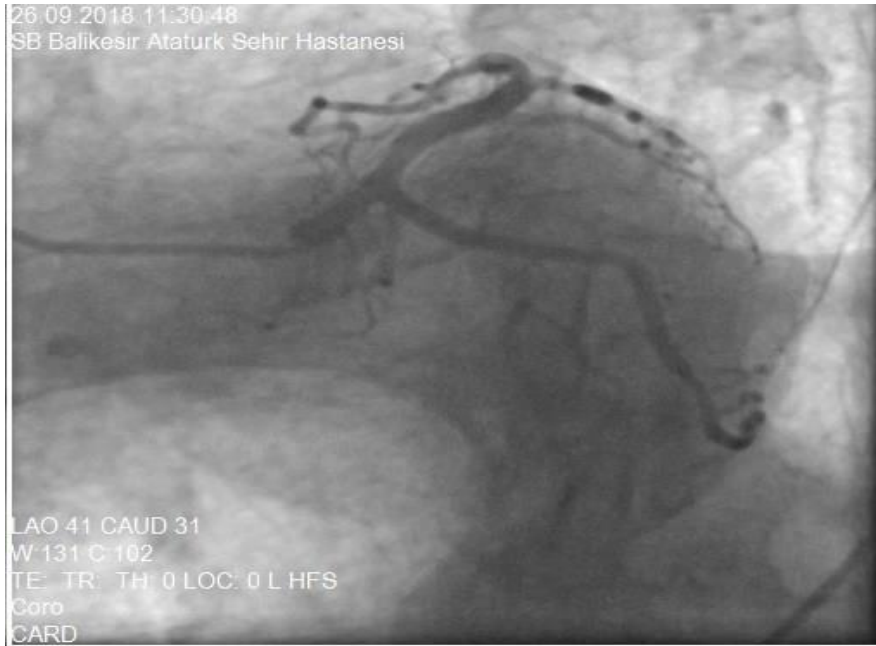

Figure 2. Anteroposterior caudal projection of circumflex and left anterior desendan artery

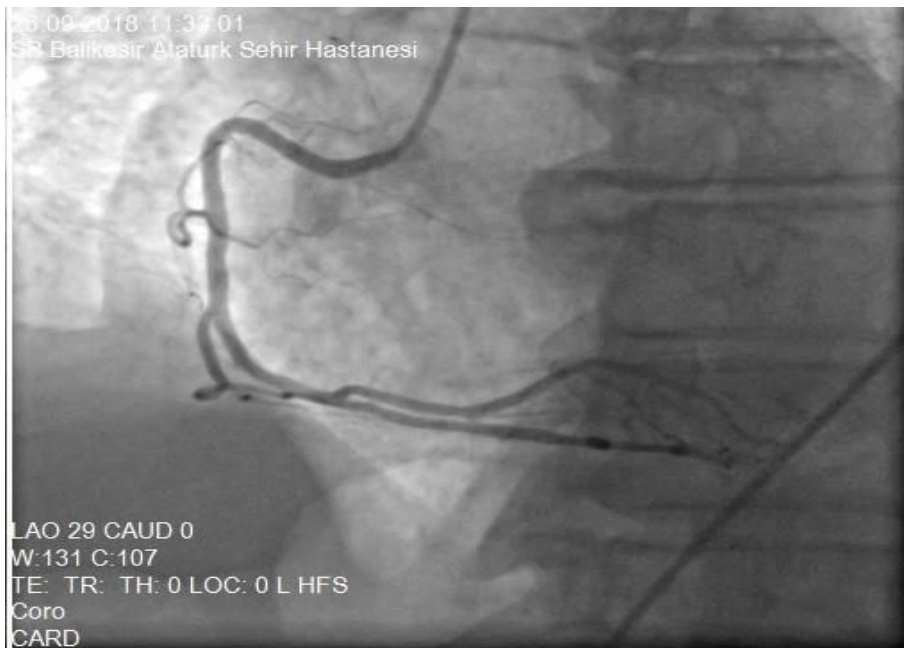


Figure 3. Left anterior oblique projection of Right coronary artery

Refferences

- 1- Kounis NG. Kounis syndrome: an update on epidemiology, pathogenesis, diagnosis and therapeutic management. Clin Chem Lab Med. 2016;54(10):1545-59.