

PAPER DETAILS

TITLE: An unusual cause of apareunia: septate hymen

AUTHORS: Baran ÖZDEMİR,Çagri ARIOGLU AYDIN,Cihan ÇETİN

PAGES: 1366-1368

ORIGINAL PDF URL: <https://dergipark.org.tr/tr/download/article-file/2322015>



EDİTÖRE MEKTUP / LETTER TO THE EDITOR

An unusual cause of apareunia: septate hymen

Aparoninin olağandışı bir sebebi: septat himen

Baran Özdemir¹ , Çağrı Arıoğlu Aydın² , Cihan Çetin³ 

¹Bahçeşehir University, School of Medicine, Istanbul, Turkey

²Medical Park Göztepe Hospital, Department of Obstetrics and Gynecology, Istanbul, Turkey

³Bahçeşehir University, School of Medicine, Department of Obstetrics and Gynecology, Istanbul, Turkey

Cukurova Medical Journal 2022;47(3):1366-1368

To the Editor,

Hymenal variations appear in a wide variety of shapes with most women do not notice until puberty unless it is imperforated hymen. Nearly half of sexually active women have suffered from sexual dysfunction¹. Sexual dysfunction can be due to a variety of factors, including structural issues, which commonly present with dyspareunia or apareunia, and psychological worries. A detailed genitourinary examination and clinicians' awareness of the risk factors and the possible etiologic factors are necessary for the appropriate approach^{2,3}. Even though hymenal abnormalities like imperforated hymen typically present with symptoms at earlier ages with primary amenorrhea and hematocolpos at the time of menarche, they rarely present with apareunia or dyspareunia^{4,5}. In this paper, we present a patient who presented with apareunia

A 23-year-old woman presented with the complaint of inability to have sexual intercourse during her attempts in the last three months after her marriage. She declared herself a virgin. Although she first got a psychiatric evaluation due to a possible vaginismus diagnosis, she did not benefit from the treatment. The patient reported no other symptoms such as pelvic pain, dysmenorrhea, dysuria, or dyschezia. Her medical history revealed no systemic or gynecologic disease. She had no previous surgery. She reported no drug or alcohol use. On abdominal examination, her abdomen and pelvic region showed no tenderness with palpation. Her gynecologic examination

confirmed the diagnosis of a thick vertical hymenal septum (8 mm) without any bulging during inspection of the vulva and hymen. Two hymenal openings were visualized on each side of the septum (Figure 1a). A horizontally placed Foley catheter behind the hymenal septum excluded the possible diagnosis of a continuing vertical vaginal septum (Figure 1b). Transrectal ultrasonography (USG) showed a normal-sized uterus with normal endometrial thickness, and ovaries with normal follicular structure and size. She was also evaluated with abdominal/urinary system USG, and they did not show any abnormalities. Under intravenous sedation with diazepam, upper and lower edges of the septum were excised using electrocautery and an annular hymenal structure was formed and by this way, virginity was also conserved (Figure 2). She was discharged from the hospital two hours after the operation and given single-dose transrectal 100mg indomethacin for analgesic purposes. 1 month after the operation she reported no complaints during the sexual intercourse. The patient gave consent for the publication of her medical/surgical data.

Sexual discomfort is a common condition affecting nearly half of women throughout their lives¹. Multiple factors are involved in the etiology, and these factors can be further investigated. Symptoms may range from disability to having sexual penetration, called apareunia; to painful sexual intercourse, called dyspareunia. The case we present in this article is a recently married 23-year-old virgin

Yazışma Adresi/Address for Correspondence: Dr. Baran Özdemir, Bahçeşehir University, School of Medicine, Istanbul, Turkey. E-mail: ozdemirbrn@gmail.com.

Geliş tarihi/Received: 21.03.2022 Kabul tarihi/Accepted: 17.07.2022

woman with a complaint of apareunia. Vulvodynia, vulvar vestibulitis, vaginitis, urethritis², and especially vaginismus⁶ are more commonly thought possible diagnoses for patients presenting with apareunia or dyspareunia. Occasionally, like in our case, patients may first seek psychiatric evaluation and treatment for vaginismus. As a matter of course, they do not benefit from this approach. It is important to keep in mind that hymenal variations may also cause apareunia or dyspareunia. As a result of their uncommon appearance after pubertal ages, they can easily be missed by an inexperienced physician unless complete hymenal visualization is done during vulvar inspection.

Some hymenal variants are identified and considered clinically significant including imperforated hymen, microperforated hymen, and septate hymen⁵. The presentation of a patient with a hymenal abnormality varies by age group, but the most common findings are pain due to hematocolpos or difficulty using

tampons after menarche^{5,7}. Apareunia and dyspareunia are also rare findings for hymenal abnormalities because symptoms of an abnormal hymen variation usually appear before the sexually active ages. This report shows the importance of a careful vulvar/hymenal inspection for a patient suffering from apareunia. Once detected, several methods can be used for the surgical excision depending on the hymenal abnormality. Following the electrosurgical excision of the superior and inferior edges of the vertical septum, a hymen with an annular structure was formed in order to preserve the virginity of the patient. For the patients who give importance to preserving their virginity, this can be a secondary benefit⁸.

Although septate hymen is a rare variation, physicians should keep this etiology in their mind for patients presenting with apareunia and these patients should first have a careful gynecologic examination.

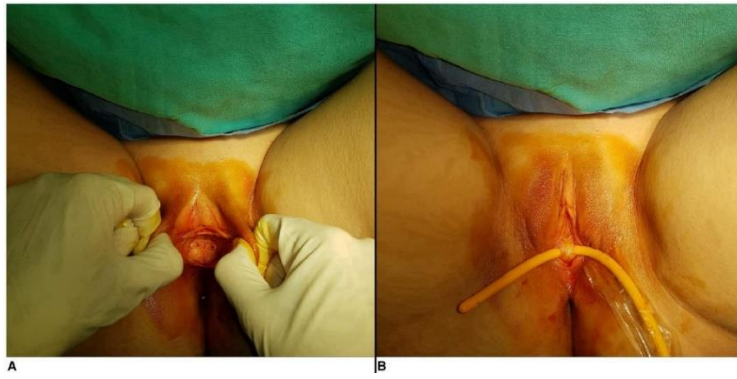


Figure 1.a) Inspection of two hymenal openings on each side of the septum. b) Foley catheter is placed horizontally behind the septate hymen.

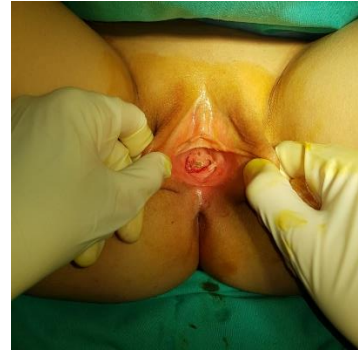

Figure 2. Postoperative photograph of the hymen.

Yazar Katkıları: Çalışma konsepti/Tasarımı: BÖ, ÇAA, CÇ; Veri toplama: BÖ, ÇAA, CÇ; Veri analizi ve yorumlama: BÖ, ÇAA, CÇ; Yazı taslağı: BÖ, ÇAA, CÇ; İçerğin eleştirel incelenmesi: BÖ, ÇAA, CÇ; Son onay ve sorumluluk: BÖ, ÇAA, CÇ; Teknik ve malzeme desteği: ÇAA, CÇ; Süpervizyon: ÇAA, CÇ; Fon sağlama (mevcut ise): yok.

Etik Onay: Bu çalışma editöre mektup niteliğinde olup, etik kurul onayına gerek yoktur.

Hakem Değerlendirmesi: Editöryal değerlendirme.

Çıkar Çatışması: Yazarlar çıkar çatışması beyan etmemişlerdir.

Finansal Desteği: Yazarlar finansal destek beyan etmemişlerdir.

Author Contributions: Concept/Design : BÖ, ÇAA, CÇ; Data acquisition: BÖ, ÇAA, CÇ; Data analysis and interpretation: BÖ, ÇAA, CÇ; Drafting manuscript: BÖ, ÇAA, CÇ; Critical revision of manuscript: BÖ, ÇAA, CÇ; Final approval and accountability: BÖ, ÇAA, CÇ; Technical or material support: ÇAA, CÇ; Supervision: ÇAA, CÇ; Securing funding (if available): n/a.

Ethical Approval: As this is a letter to the editor, it does not need the approval of the ethics committee.

Peer-review: Editoria review.

Conflict of Interest: Authors declared no conflict of interest.

Financial Disclosure: Authors declared no financial support

REFERENCES

1. Jamieson DJ, Steege JF. The prevalence of dysmenorrhea, dyspareunia, pelvic pain, and irritable bowel syndrome in primary care practices. *Obstet Gynecol.* 1996;87:55-8.

2. Hill DA, Taylor CA. Dyspareunia in women. *Am Fam Physician*. 2021;103:597-604.
3. Canlorbe G, Laas E, Cortez A, Darai E. Spontaneous hymeneal endometriosis: a rare cause of dyspareunia. *BMJ Case Rep*. 2014;2014:bcr2013202299..
4. Paniel BJ, Haddad B, el Medjadji M. Dyspareunie orificielle: le point de vue du chirurgien. *Contraception, fertilité, sexualité*. 1995;23:271-4.
5. Diagnosis and Management of Hymenal Variants: ACOG Committee Opinion, Number 780. *Obstetrics and Gynecology*. 2019;133:e372–6.
6. Michetti PM, Silvaggi M, Fabrizi A, Tartaglia N, Rossi R, Simonelli C. Unconsummated marriage: can it still be considered a consequence of vaginismus?. *Int J Impot Res*. 2014;26:28-30.
7. Parton JR, O'Mahony F. Unusual presentation of a septate hymen leading to a retained vaginal tampon in the urinary bladder. *BMJ Case Rep*. 2021;14:e239428.
8. Cetin C, Soysal C, Khatib G, Urunsak IF, Cetin T. Annular hymenotomy for imperforate hymen. *J Obst Gynaecol Res*. 2016;42:1013-5.