

## PAPER DETAILS

TITLE: A MALT LYMPHOMA PRESENTING WITH PRIMARY DIFFUSE RENAL INVOLVEMENT

AUTHORS: Abdulkadir Karismaz,Elif Suyani,Mehmet Hilmi Dogu,Gülben Erdem Huq,Sermin Altindal,Istemi Serin,Osman Yokus

PAGES: 248-250

ORIGINAL PDF URL: <https://dergipark.org.tr/tr/download/article-file/2903622>

## A MALT LYMPHOMA PRESENTING WITH PRIMARY DIFFUSE RENAL INVOLVEMENT

### PRIMER DİFFÜZ BÖBREK TUTULUMU İLE PREZENTE OLAN BİR MALT LENFOMA

ABDÜLKADİR KARIŞMAZ<sup>1</sup>, ELİF SUYANI<sup>2</sup>, MEHMET HİLMİ DOĞU<sup>3</sup>, GÜLBEN ERDEM HUQ<sup>4</sup>, SERMİN ALTINDAL<sup>5</sup>, İSTEMİ SERİN<sup>6</sup>, OSMAN YOKUŞ<sup>7</sup>

<sup>1</sup> Department of Hematology, University of Health Sciences, Istanbul Training and Research Hospital, Istanbul, Turkey

<sup>2</sup> Department of Hematology, University of Health Sciences, Adana Training and Research Hospital, Adana, Turkey,

<sup>3</sup> Department of Internal Medicine and Hematology, Istinye University, Liv Hospital, Istanbul, Turkey

<sup>4</sup> Department of Pathology, University of Health Sciences, Istanbul Training and Research Hospital, Istanbul, Turkey

<sup>5</sup> Department of Hematology, University of Health Sciences, Istanbul Training and Research Hospital, Istanbul, Turkey

<sup>6</sup> Department of Hematology, University of Health Sciences, Istanbul Training and Research Hospital, Istanbul, Turkey

<sup>7</sup> Department of Hematology, University of Health Sciences, Istanbul Training and Research Hospital, Istanbul, Turkey

#### ÖZET

Marjinal zon lenfomada böbreğin tutulumu sık görülen bir durum değildir. Yetmiş yedi yaşında kadın hasta böbrek yetmezliği şikayeti ile kliniğe başvurdu. Böbrek biyopsisinde normal böbrek dokusunun yerini alan diffüz lenfoid infiltrasyon saptandı. İmmüno-histokimyasal boyamada CD20, CD38, kappa, IgD pozitif ve CD3, lambda, siklin D1, CD5, CD23, CD43 negatif bulundu. Ki-67 %10 pozitif. Hastaya MALT tip marginal zon lenfoma tanısı konuldu. Evreleme için yapılan vücut Fluorodeoksiglukoz pozitron emisyon tomo-grafi/bilgisayarlı tomografi (FDG PET/CT) her iki böbrekte yaygın FDG tutulumu göstermekteydi, lenfadenopati saptanmadı. Kemik iliği aspirasyonu ve biyopsisi normaldi. Rituximab - bendamustin kemoterapi rejimi başlandı. Sonuç olarak, bu olgu böbreği diffüz olarak tutan ilk MALT lenfoma olgusudur ve böbrek fonksiyonlarının geri dönüşümsüz kaybını önlemek için hızlı tanı ve tedavi gerekmektedir.

**Anahtar Kelimeler:** Lenfoma, MALT lenfoma, böbrek, böbrek tutulumu.

#### ABSTRACT

The involvement of kidney in marginal zone lymphoma is not a frequent condition. Seventy-seven-year-old female presented with renal failure. Renal biopsy revealed diffuse lymphoid infiltration replacing the normal renal tissue. Immunohistochemical staining was CD20, CD38, kappa, IgD positive and CD3, lambda, cyclin D1, CD5, CD23, CD43 negative. Ki-67 was 10% positive. The patient was diagnosed as MALT type marginal zone lymphoma. Body Fluorodeoxyglucose positron emission tomography/computed tomography (FDG PET/CT) performed for staging revealed diffuse FDG uptake in both kidneys and no lymphadenopathy was detected. Bone marrow aspiration and biopsy were normal. Rituximab - bendamustin chemotherapy regimen was started. In conclusion, this is the first case of MALT lymphoma involving kidney diffusely which requires rapid diagnosis and treatment to prevent irreversible loss of renal functions.

**Keywords:** Lymphoma, MALT lymphoma, kidney, renal involvement

**Corresponding author:** İstemi Serin

**E-mail:** serinistemi@hotmail.com

**ORCID:** 0000-0003-1855-774X

**Submission date:** 26.01.2023 **Accepted date:** 22.02.2023

**Cite as:** Karismaz A, Suyani E, Doğu MH, Huq GE, Altindal S, Serin I, Yokus O. A Malt Lymphoma Presenting with Primary Diffuse Renal Involvement. Eskisehir Med J. 2023; 4(supp): 248-250. doi: 10.48176/esmj.2023.142.

## INTRODUCTION

Marginal zone lymphomas (MZLs), constituting 5-17% of all non-Hodgkin lymphomas, comprise mucosa-associated lymphoid tissue (MALT) lymphoma, splenic MZL and nodal MZL subtypes. Marginal zone lymphomas originate from B lymphocytes existing in marginal zone of secondary lymphoid follicles and usually develop in the white pulp of splenic and MALT where robust antigenic entrance occurs (1, 2).

According to the 2016 WHO classification of lymphoid neoplasia, MZL can be divided into nodal marginal zone lymphoma, splenic marginal zone lymphoma, and extra nodal MALT lymphoma (3). The stomach is the most common anatomical site for MALT, followed by the skin, lungs, intestines, and ocular adnexa (4). MALT usually develops secondary to chronic inflammation as a result of infection or autoimmune disorders (4).

Four chromosomal translocations responsible for MALT were defined as follows:  $t(11;18)(q21;q21)$ ,  $t(14;18)(q32;q21)$ ,  $t(3;14)(p14.1;q32)$  and  $t(1;14)(q22;q32)$  (2-6).  $t(11;18)$  was the first one revealed for MALT lymphoma, disrupts the *api2* gene on chromosome 11q21 and the *malt1* gene on chromosome 18q21, resulting in a new *api2-malt1* chimeric gene.

The involvement of kidney in MZL is not a frequent condition and primary renal MALT lymphoma has been reported as case reports (7-12). Here, we present a MALT lymphoma case presenting with primary diffuse renal involvement.

## CASE

Seventy-seven year old female presented with renal failure. Her medical history and physical examination were unremarkable. Her laboratory tests were as follows; white blood cell count:  $5.61 \times 10^9/L$ , neutrophil count:  $12.65 \times 10^9/L$ , hemoglobin: 12 g/dL, thrombocyte count:  $249 \times 10^9/L$ , blood urea nitrogen: 153 mg/dL, creatinin: 3.94 mg/dL. Peripheral smear, biochemical and liver test results were normal. Hepatitis B serum (HBs) Antigen, HBs anti-body, hepatitis C antibody, and human immunodeficiency antibody, Anti-HIV test results were negative. A renal biopsy was performed and revealed diffuse lymphoid cell infiltration replacing the normal renal tissue. The infiltration consisted of small and medium sized lymphocytes containing round nuclei with dispersed dusty chromatin and without any nucleolus; the cytoplasm of the cells were narrow and eosinophilic. Some of the cells had plasmacytoid appearance. No Dutcher body was observed. Immunohistochemical staining showed that CD20, CD38, kappa, IgD were positive and CD3, lambda, cyclin D1, CD5, CD23, CD43, lambda were negative. Ki-67 was 10% positive (Figure 1). The differential diagnosis was done between extranodal MZL and lymphoplasmacytoid lymphoma. Due to the widespread IgD positivity, the patient was diagnosed as MALT type MZL. Body Fluorodeoxyglucose positron emission tomography/computed tomography (FDG PET/CT)

performed for staging revealed diffuse FDG uptake in both kidneys and no lymphadenopathy was detected (Figure 2). Bone marrow aspiration and biopsy were normal. Rituximab - bendamustine chemotherapy regimen was started. After the 4th course of treatment, the patient died due to extensive systemic progression of lymphoma.

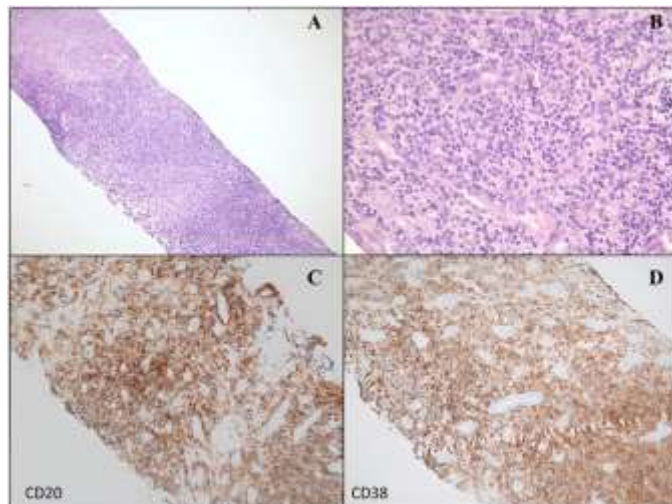


Figure 1. At low power magnification (A) kidney is extensively infiltrated by a lymphoma with a diffuse pattern (H&Ex40). At higher magnification (B) the neoplasm is composed of small lymphoid cells with round nuclear contours and clumped chromatin pattern (H&Ex400). Infiltration is diffusely positive with CD20 (C) and CD38 (D) (DABx200).

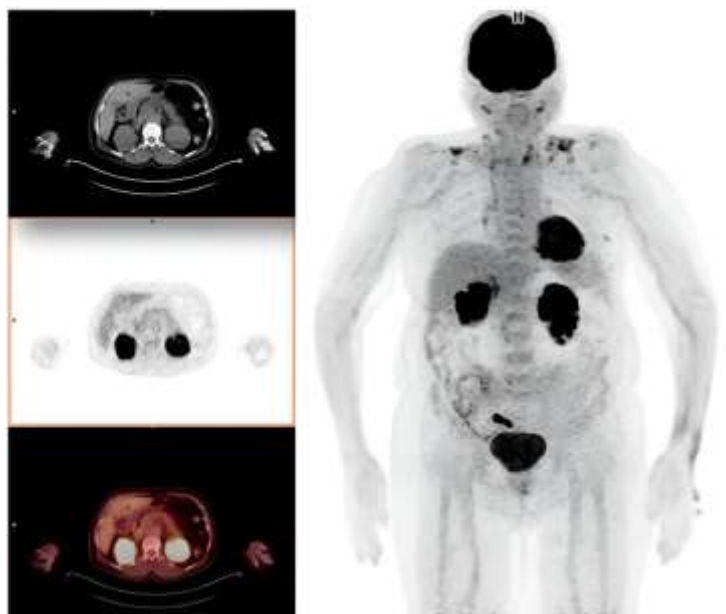

Figure 2. Fluorodeoxyglucose positron emission tomography/computed tomography image of the patient at diagnosis.

## DISCUSSION

This case presenting to the clinic with acute renal failure without any mass formation and being diagnosed with MALT creates a unique feature for the literature. When the cases in the literature are examined, it was revealed that renal

MALT cases were diagnosed with renal mass; however, our case was unique as, there was a diffuse infiltration of the both kidneys with MALT lymphoma. The tumor must have been developed from the lymphatics located in the kidney (13). But, how both kidneys were involved diffusely is an issue that needs to be explained. We speculate that a chronic antigenic stimulation caused by a chemical through blood or an infectious agent through urinary system may have caused the development MALT lymphoma in both kidneys diffusely.

In the review of Garcia et al., the median age was reported as 65 years (7). The fact that the majority of the cases described in the literature are middle-aged and older, strength-ens the possibility of chronic inflammation. While similarly reported patients were generally seen in unilaterally and mass formation, the patient in our case report was diagnosed as bilat-eral diffuse infiltrative. Patients from literature presented mostly with flank pain and urinary system complaints, while our case was diagnosed during the acute renal failure examination. In the further examination, no area compatible with extranodal involvement was observed. While glandular structures, ocular area, prostate were accompanying extranodal areas, no extranodal involvement area including bone marrow was detected in our case (14-17).

There were accompanying chronic inflammatory conditions and rheumatological comorbidities in previously described cases, the anamnesis of our case was unremarkable. The risk of developing lymphoma in patients with Sjögren's syndrome, which is frequently seen together, was found to be 44 times higher than in the normal population (18). While Sjögren's syndrome may accompany the cases described in the literature, such a feature was not present in our case. In terms of treatment, chemotherapy was preferred in most of the defined cases, while remission was achieved with nephrectomy in some cases (7, 19).

In conclusion, to our knowledge, this is the first case of MALT lymphoma involving kidney diffusely which requires rapid diagnosis and treatment to prevent irreversible loss of renal functions.

**Acknowledgements:** We respectfully remember all the colleagues we lost in the fight against COVID-19.

**Ethics Committee Approval:** Informed consent was obtained from our patient to publish the presentation.

**Informed Consent:** Written informed consent was obtained from the patient for publication of this case report and any accompanying images.

**Authorship Contributions:** Concept and design of article: IS, Data Collecting: IS, GEH, SA; Writing: IS, GEH, OY; Drafting and critical revision of the article: IS, AK, ES, MHD.

**Conflict of interest:** The authors declare that they have no competing interests.

**Financial Disclosure:** No funding was received. None of the authors has disclosures relevant to this manuscript.

## REFERENCES

1. Joshi M, Sheikh H, Abbi K, et al. Marginal zone lymphoma: old, new, targeted, and epigenetic therapies. *Ther Adv Hematol* 2012;3:275-90.
2. Zinzani PL. The many faces of marginal zone lymphoma. *Hematology Am Soc He-matol Educ Program* 2012;2012:426-32.
3. Quintanilla-Martinez L. The 2016 updated WHO classification of lymphoid neo-plasias. *Hematol Oncol* 2017;35:37-45.
4. Khalil MO, Morton LM, Devesa SS et al. Incidence of marginal zone lymphoma in the United States, 2001-2009 with a focus on primary anatomic site. *Br J Haematol* 2014; 165: 67-77.
5. Isaacson PG, Du MQ. MALT lymphoma: from morphology to molecules. *Nat Rev Cancer* 2004;4:644-53.
6. Bacon CM, Du MQ, Dogan A. Mucosa-associated lymphoid tissue (MALT) lympho-ma: a practical guide for pathologists. *J Clin Pathol* 2007;60:361-72.
7. Garcia M, Konoplev S, Morosan C, et al. MALT lymphoma involving the kidney: a report of 10 cases and review of the literature. *Am J Clin Pathol* 2007;128:464-73.
8. Berger F, Felman P, Thieblemont C, et al. NonMALT marginal zone B-cell lympho-mas: a description of clinical presentation and outcome in 124 patients. *Blood* 2000;95:1950-56.
9. Chi PJ, Pei SN, Huang TL, et al. Renal MALT lymphoma associated with Walden-ström macroglobulinemia. *J Formos Med Assoc* 2014;113:255-57.
10. Charitaki E, Liapis K, Moutzouris DA, et al. Primary renal MALT lymphoma pre-senting with cryoglobulinaemia. *Nephrol Dial Transplant* 2011;26:3819-21.
11. Kato Y, Hasegawa M, Numasato S, et al. Primary mucosa-associated lymphoid tis-sue-type lymphoma arising in the kidney. *Int J Urol* 2008;15:90-2.
12. Tuzel E, Mungan MU, Yorukoglu K, et al. Primary renal lymphoma of mucosa-associated lymphoid tissue. *Urology* 2003;61:463.
13. Ishikawa Y, Akasaka Y, Kiguchi H, et al. The human renal lymphatics under normal and pathological conditions. *Histopathology* 2006;49:265-73.
14. Pelstring RJ, Essell JH, Kurtin PJ, et al. Diversity of organ site involvement among malignant lymphomas of mucosa-associated tissues. *Am J Clin Pathol* 1991;96: 738-45.
15. Gromicho A, Araújo D, Oliveira V, et al. Mucosa-Associated Lymphoid Tissue Lym-phoma Involving the Kidney and Renal Pelvis. *Cureus* 2021;13:15172.
16. Qiu L, Unger PD, Dillon RW, et al. Low-grade mucosa-associated lymphoid tissue lymphoma involving the kidney: report of 3 cases and review of the literature. *Arch Pathol Lab Med* 2006;130:86-9.
17. Araki K, Kubota Y, Iijima Y, et al. Indolent behaviour of low-grade B-cell lymphoma of mucosa-associated lymphoid tissue involved in salivary glands, renal sinus and prostate. *Scand J Urol Nephrol* 1998;32:234-6.
18. Titsinides S, Nikitakis N, Piperi E, et al. MALT Lymphoma of Minor Salivary Glands in a Sjögren's Syndrome Patient: a Case Report and Review of Literature. *J Oral Maxillofac Res* 2017;8:5.
19. Parveen T, Navarro-Roman L, Medeiros LJ, et al. Low-grade B-cell lymphoma of mucosa-associated lymphoid tissue arising in the kidney. *Arch Pathol Lab Med* 1993;117:780-3.



4.0 Uluslararası Lisansı ile lisanslanmıştır.