

PAPER DETAILS

TITLE: Adverse Effects of Lead Treatment: Relationship of Histopathological Changes and Protective Role of Sodium Selenite on Non-Diabetic and Diabetic Rat Hearts

AUTHORS: Hatice BAS,Suna KALENDER,Fatma APAYDIN

PAGES: 855-859

ORIGINAL PDF URL: <https://dergipark.org.tr/tr/download/article-file/83671>



Adverse Effects of Lead Treatment: Relationship of Histopathological Changes and Protective Role of Sodium Selenite on Non-Diabetic and Diabetic Rat Hearts

Hatice BAŞ^{1,*}, Suna KALENDER², Fatma Gökçe APAYDIN³

¹ *Bozok University, Faculty of Arts and Science, Department of Biology, Yozgat, Turkey*

² *Gazi University, Gazi Education Faculty, Department of Science Education, Ankara, Turkey*

³ *Gazi University, Faculty of Science, Department of Biology, Ankara, Turkey*

Received: 28/04/2014 Revised: 06/05/2014 Accepted: 09/05/2014

ABSTRACT

The present study was designed to examine the effects of lead nitrate (LN) and whether selenium has a cardioprotective effect on diabetic and non-diabetic rats. Selenium and LN were administered orally for 28 days to streptozotocin-induced diabetic and non-diabetic rats. Animals were divided into 8 groups: control, sodium selenite, LN, LN+Sodium selenite, diabetic-control, diabetic sodium selenite, diabetic LN and diabetic LN+Sodium selenite. In our present study LN and diabetes caused histopathological changes in heart of animals. We found that sodium selenite treatment did not show protective effect on diabetes mellitus (DM) caused damages. However it showed protective effect against LN but, not completely shown a protective.

Key words: *Lead toxicity, sodium selenite, diabetes mellitus, histopathology, heart*

1. INTRODUCTION

Due to heavy metals toxicity and accumulation they have a great ecological consideration [1]. Some of them are essential for living organisms including man. But when organisms are exposed to higher doses than required amount they show adverse effects. Other heavy metals like as lead (Pb) is non-essential for metabolic activities and demonstrates toxic effects [2]. Pb is a spread and permanent environmental and occupational toxic metal [3]. Organisms exposure to Pb contact with Pb based paints in houses, automobiles, disposable batteries, etc., [4]. Pb causes many pathological

dysfunctions including cardiac [5], neurological [6], hepatic [4], immunological [7], renal [8] and haematological [9].

Selenium (Se) is an essential trace element. It has been reported to decrease the rate of methylmercury-induced neurological damages [10]. Seafood species [11] and vegetables [12] known to be good dietary source of this element. It prevents several illnesses, such cancer, hypercholesterolemia and cardiovascular disease [12]. Se was found to have a protective effects in different organs [13]. It was given to animals in sodium selenite form in most of studies [14].

*Corresponding author, e-mail: htc.haticebas@gmail.com

Diabetes mellitus (DM) is one of main reason of mortality in population. It is an important common endocrine disorder and characterized by hyperglycemia. This situation results from the failures in insulin secretion or action. DM develops and progresses vascular complications including cardiovascular and cerebrovascular diseases [15, 16]. Heart failure and myocardial infarction are chronic complications of DM [17]. After myocardial infarction, the mortality rate of diabetic patients is twice of non-diabetic patients[18]. DM causes changes in tissue biological functions. Alterations in functions contribute in the pathogenesis of organ failures [19]. Some chemical agents such as streptozotocin (STZ) can change function of β -cells leading to DM. STZ destroys β -cells which produce insulin in pancreas, by DNA methylation and DNA damage [16].

In the present study, the subacute effects of LN and sodium selenite on heart of non-diabetic and STZ-induced diabetic rats were investigated light microscopic examination.

2. EXPERIMENTAL PROCEDURES

2.1. Animals and Chemicals

Male Wistar rats, weighing 200-250 g, were obtained from the Gazi University Laboratory Animals Growing and Experimental Research Center. The animals were housed at 22 ± 2 °C and they were supplied with standard laboratory chow and water *ad libitum* and left to accommodate for 10 days before the beginning of study. The protocol which used in this study was approved by the Gazi University Animal Experiments Local Ethics Committee. The procedures were performed in accordance with international guidelines for care and use of laboratory animals. Lead nitrate (LN), sodium selenite, streptozotocin (STZ) and all the other chemicals were obtained from Sigma Aldrich. LN [20] and sodium selenite [21] were dissolved in distilled water.

2.2. Animal Grouping and Treatment

The rats were randomly assigned to eight groups.

- Group 1: Control group (n=6)
- Group 2: Sodium selenite group (n=6)
- Group 3: LN group (n=6)

- Group 4: LN+Sodium selenite group (n=6)
- Group 5: Diabetic control group (n=6)
- Group 6: Diabetic sodium selenite group (n=6)
- Group 7: Diabetic LN group (n=6)
- Group 8: Diabetic LN+Sodium selenite group (n=6)

During 28 days, 1ml/ kg b.w (body weight) distilled water for control groups, 1ml/ kg b.w sodium selenite for sodium selenite treatment groups and 22.5 mg/kg b.w (1/100 LD₅₀) LN [20, 22] for LN treatment groups were given to rats daily via gavage. Diabetes was induced using an intraperitoneal (i.p) injection of STZ at a single dose of 55 mg/kg in sodium citrate buffer (pH 4.5). Two days later, the blood glucose levels were measured from the tail with a glucometer. Animals whose blood glucose levels of 300 mg/dl or higher were approved to be diabetic [23].

2.3. Light microscopic examination

The ventricles of hearts from each animal were dissected and fixed in Bouin. Then samples dehydrated in ascending grades of ethanol and embedded in paraffin. Sections of 6-7 μ thickness were taken from paraffin blocks and stained with hematoxylin and eosin and examined by light microscopy (Olympus BX51, Tokyo, Japan) and photographed with a camera (Olympus E-330, Olympus Optical Co., Ltd., Japan).

3. RESULTS

3.1. Histological results

In our study histopathological examination of diabetic and non-diabetic rat hearts were investigated using light microscope. The histological examination of the heart tissues of the control and sodium selenite treated rats showed normal cyto-architecture of myocardial fibers and cardiac muscle cells. Rats treated with LN alone exhibited necrosis and degeneration in myocardial fibers. Sodium selenite treatment reduced these pathological changes but it was shown that necrosis and degeneration in myocardial fibers. Diabetic control and sodium selenite treated rats showed increased eosinophilia in myocardial fibers in the heart. In LN treated diabetic rats there were degenerative changes, inflammation, cytoplasmic vacuolization in myocytes and edema in connective tissue. In LN+sodium selenite treated rats edema in connective tissue and cytoplasmic vacuolization in myocytes were seen. (Figure 1).

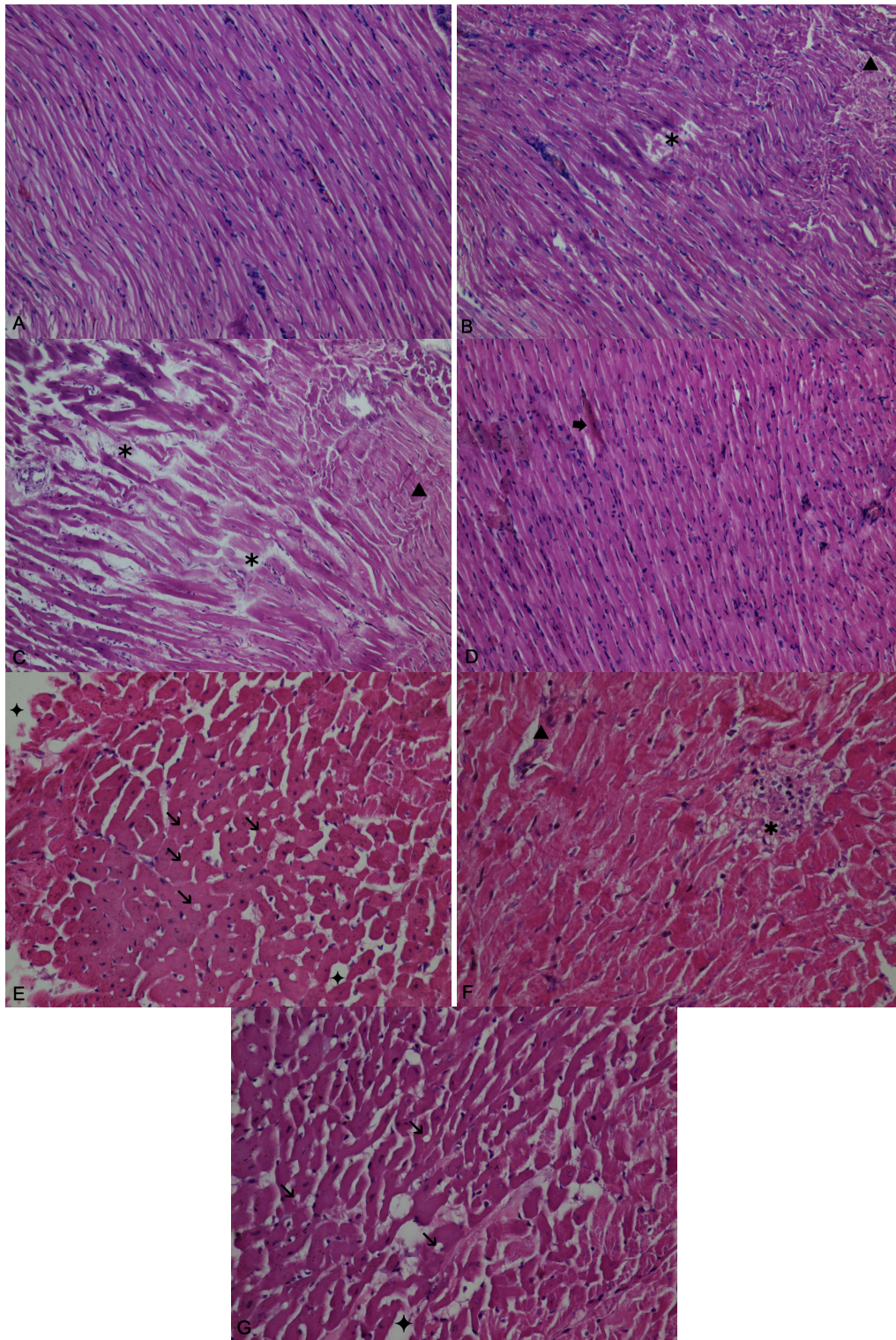


Figure 1. (A) Heart section of control rats were observed in normal structure x200. (B) Heart sections of LN treated rats showing necrosis (*) and degeneration (▲) in myocardial fibers x200. (C) Heart sections of LN+ Sodium selenite treated rats showing necrosis (*) and degeneration (▲) in myocardial fibers x200. (D) Heart sections of STZ control rats showing eosinophilia in myocardial fibers (➡) x400. (E-F) Heart sections of STZ-LN edema in connective tissue (◆), cytoplasmic vacuolization in cardiac muscle cells (↘), inflammation (*), and degeneration (▲) in myocardial fibers x400. (G) Heart sections of STZ-LN+Sodium selenite treated rats showing cytoplasmic vacuolization in cardiac muscle cells (↘) and edema in connective tissue (◆) x400.

4. DISCUSSION

Pb has some important properties that cause to its adverse effects. It acts like similar to calcium and competitively inhibits calcium actions in substantial areas. Particularly, it breaks the intracellular messenger system regulated by calcium. Also it shows high affinity for sulfhydryl groups so induces reduction of sulphhydryl dependent enzyme activities [24]. Former studies indicate that heavy metals induces many oxidative damages [4, 25]. Despite the mechanism of Pb toxicity is not known certainly, there is demonstration that Pb can induce production of ROS and interrupts the antioxidant enzyme activities in tissues [4, 26].

Heavy metals can cause histopathologic changes in tissues such as liver [1], heart [27] and testes [13]. Accumulation of heavy metals in tissues can cause this changes. Accumulation does not only consist in the construction of the tissue also depend on the interaction between target organs and metals[1]. Lead causes pathological damages in tissue and organs such as kidney [28], liver and brain [4]. Various factors are correlated with cardiovascular diseases such as the industrial pollution of the environment with metals which has become a serious case [29]. There are too many unwanted effects of heavy metals on cardiovascular system [30, 31]. The myocardium when exposed to heavy metal reduces its contractility [30]. In a previous study authors reported histopathological changes such as interstitial fibrosis, vacuolization, hemorrhage and necrosis in rat hearts treated with chromium [29]. Exposure to cadmium produce extensive degeneration in cardiac muscle and interstitial fibrosis in mice heart [27]. We found by means of this study that LN induced many histopathological changes by light microscopic examinations in heart of rats. Histological investigations of rats shows that LN treatment caused abnormal pathological changes in the cardiac tissue.

In conclusion, exposure to LN and DM caused toxic effects on heart tissues in rats. Sodium selenite treatment ameliorated LN induced histologic changes but not protect completely in rats, but it didn't protect DM induced adverse effects.

CONFLICT OF INTEREST

No conflict of interest was declared by the authors.

REFERENCES

[1] El-Naggar, A.M., Mahmoud, S.A. Tayel, S.I., "Bioaccumulation of some heavy metals and histopathological alterations in liver of *Oreochromis niloticus* in relation to water quality at different localities along the river Nile, Egypt", *WJFMS*. 1 (2): 105–114, (2009).

[2] FAO, "Committee for inland fisheries of Africa; Report of the third session of the working party on pollution and fisheries", *FAO fisheries*. Rep., No. 471, (1992).

[3] Zbakh, H., Abbassi, A.E., "Potential use of olive mill wastewater in the preparation of functional beverages: a review". *J. Funct. Food*, 4: 450–458 (2012).

[4] Dewanjee, S., Sahu, R., Karmakar, S., Gangopadhyay, M., "Toxic effects of lead exposure in Wistar rats: Involvement of oxidative stress and the beneficial role of edible jute (*Corchorus olitorius*) leaves", *Food Chem. Toxicol.* 55: 78–91 (2013).

[5] Voors, A.W., Shuman, M.S., Johnson, W.D., "Additive statistical effects of cadmium and lead on heart-related disease in a North Carolina autopsy series". *Arch. Environ. Health*, 37: 98–102 (1982).

[6] Bellinger, D.C., "Very low lead exposures and children's neurodevelopment". *Curr. Opin. Pediatr.* 20: 172–177 (2008).

[7] Rosenberg, C.E., Fink, N.E., Salibian, A., "Humoral immune alterations caused by lead: studies on an adult toad model". *Acta Toxicol. Arg.* 15: 16–23 (2007).

[8] Rastogi, S.K., "Renal effects of environmental and occupational lead exposure". *Ind. J. Occup. Env. Med.* 12: 103–106 (2008).

[9] Khalid, G., Fartosi, A.L., "Effect of selenium and lead on some blood parameters of male mice". *J. Dohuk Univ.* 11: 62–66 (2008).

[10] Kaur, P., Evje, L., Aschner, M., Syversen, T., "The in vitro effects of selenomethionine on methylmercury-induced neurotoxicity", *Toxicol. in Vitro*, 23: 378–385 (2009).

[11] World Health Organisation, "Environmental Health Criteria 58: Selenium" *International Programme on Chemical Safety*, Geneva. (1987).

[12] Luo, Y., Zhang, B., Cheng, W., Wang, Q., "Preparation, characterization and evaluation of selenite-loaded chitosan/TPP nanoparticles with or without zein coating". *Carbohydr. Polym.* 82: 942–951 (2010).

[13] Kalender, S., Uzun, F.G., Demir, F., Uzunhisarcıklı, M., Aslanturk, A., "Mercuric chloride-induced testicular toxicity in rats and the protective role of sodium selenite and vitamin E", *Food Chem. Toxicol.* 55: 456–462 (2013).

[14] Orun, I., Talas, Z.S., Ozdemir, I., Alkan, A., Erdogan, K., "Antioxidative role of selenium on some tissues of (Cd²⁺, Cr³⁺)-induced rainbow trout", *Ecotoxicol. Environ. Safe.* 71: 71–75 (2008).

[15] Altan, V.M., "The pharmacology of diabetic complications", *Curr. Med. Chem.* 10: 1317–27 (2003).

[16] Al-Khalifa, A., Mathew, T.C., Al-Zaid, N.S., Mathew, E., Dashti, H., "Low carbohydrate ketogenic diet prevents the induction of diabetes using

streptozotocin in rats", *Exp. Toxicol. Pathol.* 63: 663–669 (2011).

[17] Thirunavukkarasu, M., Penumathsa, S.V., Koneru, S., Juhasz, B., Zhan, L., Otani, H., Bagchi, D., Das, D.K., Maulik, N., "Resveratrol alleviates cardiac dysfunction in streptozotocin-induced diabetes: Role of nitric oxide, thioredoxin, and heme oxygenase", *Free Radical Bio. Med.* 43: 720–729 (2007).

[18] Abbott, R.D.; Donahue, R.P.; Kannel, W.B.; Wilson, P.W., "The impact of diabetes on survival following myocardial infarction in men vs women: the Framingham Study" *JAMA* 260: 3456–3460 (1988).

[19] Ayaz, M., Turan, B., "Selenium prevents diabetes-induced alterations in $[Zn^{2+}]_i$ and metallothionein level of rat heart via restoration of cell redox cycle", *Am J Physiol Heart Circ Physiol* 290: H1071-H1080 (2006).

[20] Sharma, V., Sharma, A., Kansal, L., "The effect of oral administration of *Allium sativum* extracts on lead nitrate induced toxicity in male mice", *Food Chem. Toxicol.* 48: 928-936 (2010).

[21] Othman, A.I., El Missiry, M.A., "The role of selenium against lead toxicity in male rats", *J. Biochem. Mol. Toxicol.* 12: 345-349 (1998).

[22] Plastunov, B., Zub, S., "Lipid peroxidation processes and antioxidant defense under lead intoxication and iodine-deficient in experiment", *Anales Universitatis Mariae Curie Skłodowska Lublin-pol.* 21: 215-217 (2008).

[23] Schmatz, R., Melazzo Mazzanti, C., Spanevello, R., Stefanello, N., Gutierrez, J., Corrêa, M., Melgarejo da Rosa, M., Rubin, M.A., Schetinger, M.R.C., Morsch, V.M., "Resveratrol prevents memory deficits and the increase in acetylcholinesterase activity in streptozotocin-induced diabetic rats", *Eur. J. Pharmacol.* 610: 42-48 (2009).

[24] Gordon, J.N., Taylor, A., Bennett, P.N., "Lead poisoning: case studies", *Br. J. Clin. Pharmacol.* 53: 451–458 (2002).

[25] Kim, S.H., Sharma, R.P., "Mercury alters endotoxin induced inflammatory cytokin expression in liver: differential role of P38 and extra cellular signal-regulated mitogen activated protein kinases", *Immunopharm. Immunotech.*, 27: 123-135 (2005).

[26] Franco, R., Sánchez-Olea, R., Reyes-Reyes, E.M., Panayiotidis, M.I., "Environmental toxicity, oxidative stress and apoptosis: Ménage à Trois", *Mutat. Res.* 674: 3–22 (2009).

[27] Mana, P., Sinha, M., Sil, P.C., "Amelioration of cadmium-induced cardiac impairment by taurine", *Chem. Biol. Interact.* 174: 88–97 (2008).

[28] Lakshmi, B.V.S., Sudhakar, M., Aparna, M., "Protective potential of Black grapes against lead induced oxidative stress in rats", *Environ. Toxicol. Pharmacol.* 35: (361–368 (2013).

[29] Soudani, N., Troudi, A., Bouaziz, H., Amara, I.B., Boudawara, T., Zeghal, N., "Cardioprotective effects of selenium on chromium (VI) -induced toxicity in female rats", *Ecotoxicol. Environ. Safe.* 74: 513-520 (2011).

[30] Assis, G.P.S., Silva, C.E.C., Stefanon, I., Vassallo, D.V., "Effects of small concentrations of mercury on the contractile activity of the rat ventricular myocardium", *Comp. Biochem. Physiol.*, 134: 375–383 (2003).

[31] Machado, A.C., Padilha, A.S., Wiggers, G.A., Siman, F.D.M., Stefanon, I., Vassallo, D.V., "Small doses of mercury increase arterial pressure reactivity to phenylephrine in rats", *Environ. Toxicol. Pharmacol.*, 24: 92–97 (2007).