

PAPER DETAILS

TITLE: Can phosphatidylcholine increase the efficacy of bioactive glass graft when used as a carrier? an experimental study

AUTHORS: Murat KAYA,Nazim KARAHAN,Demet PEPELE,Baris YILMAZ,Ahmet MIDI,Batuhan ÖZPIÇAK

PAGES: 1044-1050

ORIGINAL PDF URL: <https://dergipark.org.tr/tr/download/article-file/2357203>

Can phosphatidylcholine increase the efficacy of bioactive glass graft when used as a carrier? an experimental study

✉Murat Kaya¹, ✉Nazım Karahan², ✉Demet Pepele Kurdal³, ✉Barış Yılmaz³, ✉Ahmet Midi⁴, ✉Batuhan Özpiçak⁴

¹Marmara University Pendik Training and Research Hospital, Department of Orthopedics and Traumatology, Istanbul, Turkey

²Çorlu District State Hospital, Department of Orthopedics and Traumatology, Tekirdag, Turkey

³Fatih Sultan Mehmet Training and Research Hospital, Department of Orthopedics and Traumatology, Istanbul, Turkey

⁴Bahçeşehir University, Faculty of Medicine, Department of Pathology, Istanbul, Turkey

Cite this article as: Kaya M, Karahan N, Pepele Kurdal D, Yılmaz B, Midi A, Özpiçak B. Can phosphatidylcholine increase the efficacy of bioactive glass graft when used as a carrier? an experimental study. J Health Sci Med 2022; 5(4): 1044-1050.

ABSTRACT

Aim: Bioactive glass (Bioglass) is a substance causing strong mechanical bondings at the interface of soft tissue-biomaterial-bone through a series of biochemical and biophysical reactions, commonly used to restore developing bone defects due to surgery. On the other hand, phosphatidylcholine is a lipid substance increasing antibiotics' efficiency as a carrier. Since we met no study using the combination of Bioglass and phosphatidylcholine for bone defects, we aimed to investigate whether the bioglass-phosphatidylcholine combination would be more effective.

Material and Method: Thirty Sprague-Dawley 3-6-months-old female rats with a mean weight of 400 gr were divided into five subgroups (six in each group). A 5-mm critical defect was created in the middle of the condyle throughout the burr's diameter bilaterally. The phosphatidylcholine-bioglass graft was placed at one side, and Bioglass contralaterally to fill the defect. The rats were sacrificed at 24 hours, 72 hours, first, third, and sixth weeks postoperatively. The right and left rat femurs were removed and examined histopathologically.

Results: There was no statistically significant difference between the groups regarding filling volume, newly formed and necrotic bone, fibrous tissue, residual graft material, integration, foreign body reaction, and defect organization, indicating that Bioglass served efficiently for filling the defect. In addition, phosphatidylcholine neither augmented nor impaired the healing process.

Conclusion: These results indicated that Bioglass served efficiently for filling the defect, and the presence of phosphatidylcholine neither augmented nor impaired the healing process. However, further experimental studies are required until its clinical application is implemented.

Keywords: Phosphatidylcholine-bioglass, mechanical bondings, foreign body reaction, 5-mm critical defect, residual graft material

INTRODUCTION

Bioactive materials are substances causing strong mechanical bondings at the interface of tissue and material (soft tissue-biomaterial-bone) by a particular biological response through a series of biochemical and biophysical reactions (1). Bioactive materials may be either osteoconductive or osteopductive, depending on their chemical and biological behaviors at the interface.

Such a promising biomaterial is bioactive glass (BAG), also known as bioglass (2). It is an osteoconductive biomaterial commonly used to restore developing bone defects during surgeries to treat trauma, tumors, implant revisions, osteomyelitis, and regenerate the region (3,4).

BAG involves a group of synthetic, silicate-based ceramics. When it was developed in the 1970s, it was formed using a combination of silicon dioxide (SiO₂), sodium oxide (Na₂O), calcium oxide (CaO), and phosphorus pentoxide (P₂O₅) (5). 45S5 (45% SiO₂, 24.5% CaO, 24.5% Na₂O, 6% P₂O₅, and hydroxy-carbon-apatite (HCA), in a form similar to in vivo bone and creating bioactivity on its surface) is one of the commonly utilized bioactive glass grafts (6). When exposed to body fluids after implantation, BAG causes the accumulation of a calcium phosphate layer through surface reactions. As a result, sodium, silica, calcium, and phosphate ions are released from the surface, increasing the local pH and osmotic pressure. Subsequently, a silica gel layer is

formed on the surface of the glass, and amorph calcium phosphate precipitates on this layer. Such amorph structures are crystallized to natural hydroxyapatite that initiates the activation of osteoblasts for new bone formation. The glass is eventually resorbed and replaced by newly formed bone due to continuing reactions and layer formation. However, rapid BAG degradation seems to create a high pH microenvironment during the entire process, endangering ionic-level bone growth and not favored by the cells (7).

Phosphatidylcholine is a lipid substance with a high affinity for calcium ions and has a controlled release effect on the dissolution profile when it contacts body fluids. It has been shown in studies investigating antibiotic efficiency that, when added as a carrier, phosphatidylcholine increases the antibiotic efficiency by creating differences regarding the biofilm layer's inhibition, decomposition rate, and elongation profile (8,9). However, our literature review revealed no study investigating the effect of using phosphatidylcholine as a carrier substance for bioactive glass. Therefore, we aimed to investigate whether BAG would be more effective in filling the critical defects in the presence of phosphatidylcholine.

MATERIAL AND METHOD

The study was carried out with the permission of The Animal Experiments Local Ethics Committee in Acibadem University approved the study protocols with the report (Date: 14.02.2019, Decision No: ACU-HAYDEK 2019/16). All procedures were carried out in accordance with the ethical rules and the principles.

Materials

The implant materials were Bioglass 45S5 (80% w/w) and Phospholipon 90 G (20% w/w) paste form (BIOMOLD paste; İDEA Ltd., Pendik, İSTANBUL). The study materials were separately packed and autoclaved as stated in the Animal Care and Use Statement.

Experimental Design

Thirty Sprague-Dawley 3-6 months old female rats with a mean weight of 400 gr were randomly divided into five subgroups according to the sacrifice day. On the basis of results of comparable studies in rats with femoral defects, sample size estimation was performed. To detect significant differences in bone formation between the groups, a group size of at least 6 animals is reported to be required (10). The rats in Subgroup 1 were planned to be sacrificed at 24 hours, Subgroup 2 at 72 hours, Subgroup 3 at the end of the first week, Subgroup 4 at the end of the third week, and Subgroup 5 at the end of the sixth week postoperatively.

Surgical Procedures

The surgical procedure was performed under general anesthesia with the mixture of fentanyl citrate/fluanisone

(Hypnorm, Janssen Pharmaceutica, Inc., Beerse, Belgium) 80 mg/kg/ 2.5 mg/kg, and midazolam (Dormicum, Roche, Basel, Switzerland) 1.25 mg/kg. In addition, cefuroxime (Zinacef, GlaxoSmithKline Manufacturing S.p.A., Verona, Italy) 20 mg/kg was subcutaneously administered to the animals preoperatively. Finally, lateral sites of rats' bilateral thighs were shaved, prepared using a Betadine scrub, and rinsed with 70% ethanol.

Skin, fascia, and muscle tissue were incised and dissected until the left femur's distal condyle was exposed. With a burr, a 5-mm diameter and 6-mm depth critical defect was created in the middle of the condyle throughout the burr's diameter (11). The phosphatidylcholine-carrying bioglass graft [FOS (+)] was placed to fill the defect entirely using micro forceps. The layers were appropriately closed.

The same procedure was performed on the right side. The skin, fascia, and muscle tissue were incised and passed until the right femur's distal condyle was exposed. A 5-mm critical defect was created in the middle of the condyle throughout the burr's diameter using a stainless steel burr. The wound was rinsed with saline. The bioglass graft with no carrier [FOS (-)] was placed to fill the defect completely using micro forceps. The muscles and skin were closed in two layers using absorbable 4.0 sutures (Dexon, Covidien, Mansfield, MA, USA). Buprenorphine (Temgesic, Reckitt & Colman Pharmaceuticals, Inc, Richmond, England) was administered subcutaneously with a dose of 0.01-0.05 mg/kg for postoperative pain relief. Total animal activity was permitted within the cages postoperatively.

The animals in five groups were sacrificed according to their predetermined days of sacrifice. Subgroup 1 was sacrificed at 24 hours, Subgroup 2 at 72 hours, Subgroup 3 at the end of the first week, Subgroup 4 at the end of the third week, and Subgroup 5 at the end of the sixth week postoperatively. Necessary precautions to minimize pain and discomfort were taken during the sacrifice process.

The right and left femurs of the sacrificed rats were disarticulated from their hip and knee joints and placed in 10% neutral buffered formalin after removing the soft tissues.

Histopathological Examination

In the histopathological examination of the defect area, filling volume (FV), newly formed bone (NFB), necrotic bone (NB), fibrous tissue (FT), and residual graft material (RG) were subjectively evaluated under the light microscope (Leica® DM 4000, Germany). The evaluation was performed according to the instructions in the literature (12). In addition, the parameters of integration

(Int), foreign body reaction (FBR), new bone formation at the defect's edge (DNB), and organization (Org) on the defect's surface were evaluated.

The investigated parameters and their evaluation criteria were as follows:

1. Filling volume (%) = $\text{Filling volume of the defect} / \text{Total defect area} \times 100$
2. Newly formed bone (%) = $\text{New bone area} / \text{Total defect area} \times 100$
3. Necrotic bone (%) = $\text{Necrotic bone area} / \text{Total defect area} \times 100$
4. Fibrous tissue, coagulum, granulation tissue (%) = $\text{Fibrous tissue area} / \text{Total defect area} \times 100$
5. Residual graft material (%) = $\text{Residual graft material area} / \text{Total defect area} \times 100$
6. Integration (%) = $\text{Integrated section} / \text{Defect area circumference} \times 100$
7. Foreign body reaction: Absent – 0; present – 1
8. New bone formation at the defect's edge: Absent – 0; present – 1
9. Organization on the defect's surface: Absent – 0; less than 50% – 1; more than 50% – 3; complete (thin-layered, less than 100 microns) – 4; complete (thick-layered, more than 100 microns) – 5.

Statistical Analysis

The R ver.2.15.3 software (R Core Team, 2013) was used for statistical analysis. Median, first quartile, third quartile, frequency, and percentage were used to report the study data. In addition, the Kruskal-Wallis and Dunn-Bonferroni tests were used to make comparisons of the quantitative variables among the time subgroups. The Wilcoxon signed-ranks test made the intergroup comparisons regarding the quantitative variables. The Fisher-Freeman-Halton exact test compared qualitative variables among the time subgroups. The McNemar and McNemar-Bowker tests were used to make two-group comparisons of qualitative variables. A p-value less than 0.05 was considered statistically significant.

RESULTS

Summary of Histopathological Examination Results
According to the Time Subgroups in Groups FOS (+) and FOS (-)

Subgroup 1 (24 hours): Newly formed bone, necrotic bone, integration, foreign body reaction, new bone formation at the defect's edge, and organization on the defect surface were not observed. However, <5% amounts of residual graft material and filling volume were identified in the groups with and without phosphatidylcholine (**Figure 1 and 2**).

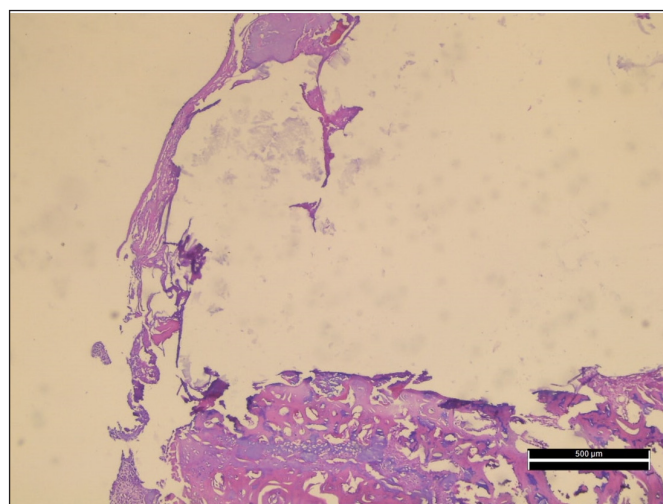


Figure 1. Group FOS (+) – Subgroup 3: granulation tissue forming a full-thickness layer on the surface, fibrinopurulent exudate around the graft particles in the defect area, the appearance of an early organization [7 days–With phosphatidylcholine (H&E, x40 magnification)]

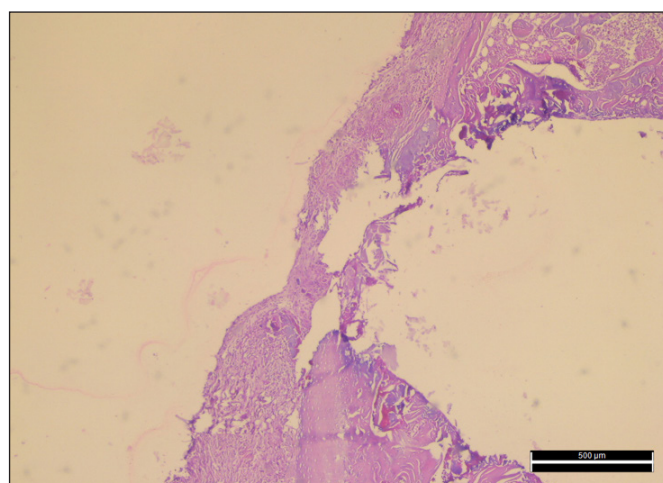


Figure 2. Group FOS (-) – Subgroup 3: granulation tissue forming a full-thickness layer on the surface, fibrinopurulent exudate around the graft particles in the defect area, the appearance of an early organization [7 days–Without phosphatidylcholine (H&E, x40 magnification)]

Subgroup 2 (72 hours): Newly formed bone, necrotic bone, integration, foreign body reaction, new bone formation at the defect's edge were not present. The organization on the defect's surface mainly was a complete (thick layered).

Subgroup 3 (7th day): Newly formed bone and new bone formation at the defect's edge were not observed. The organization on the defect's surface was mainly in a thick layer in both groups. In some samples, necrotic bone was observed together with a surrounding foreign body granulation tissue. Integration was present to a certain degree in all samples. <5% amounts of residual graft material were observed.

Subgroup 4 (3rd week): In some cases, newly formed bone and new bone formation at the defect's edge were present. The organization on the defect's surface was mainly a

thick layer in both groups. In some samples, necrotic bone was observed together with a surrounding foreign body granulation tissue. Full integration was present in all samples. The filling volume was 100% in both groups. Residual graft material was observed, constituting most of the filling volume in all samples.

Subgroup 5 (6th week): Both groups' filling volume percentages were 100%. Newly formed bone was observed in varying degrees in all samples. In both groups, organization on the defect's surface was present as a thick layer. In some samples, necrotic bone was observed, together with surrounding foreign body

reactions. Full integration and residual graft material were present in all cases. Because of the difficulty of histopathological evaluation due to the full integration of the newly formed bone and the old bone, the parameter of new bone formation at the defect's edge could not be evaluated in the sixth week (**Figures 3 and 4**).

The histopathological examination results for investigated parameters in Subgroups 1-5, together with the comparisons of Groups FOS (+) and FOS (-) to each other according to time subgroups and the comparisons of time subgroups within Groups FOS (+) and FOS (-), were presented in **Table 1**.

Table 1. The histopathological examination results for investigated parameters, together with the comparisons of Groups FOS (+) and FOS (-) to each other according to time subgroups and the comparisons of time subgroups within Groups FOS (+) and FOS (-)

	Subgroup 1	Subgroup 2	Subgroup 3	Subgroup 4	Subgroup 5	p
FV%						
FOS (+)	0.5 (0-2)	3.5 (0-5)	20 (12-30)	100 (100-100)	100 (100-100)	a<0.001*
FOS (-)	3.5 (1-15)	2.5 (0-5)	30 (20-40)	100 (100-100)	100 (100-100)	a<0.001*
bp	0.168	0.496	0.293	0.999	0.999	
NFB%						
FOS (+)	0 (0-0)	0 (0-0)	0 (0-0)	0 (0-0)	35 (30-40)	a<0.001*
FOS (-)	0 (0-0)	0 (0-0)	0 (0-0)	0 (0-5)	30 (30-40)	a<0.001*
bp	0.999	0.999	0.999	0.180	0.655	
NB%						
FOS (+)	0 (0-0)	0 (0-0)	0 (0-0)	0 (0-1)	0 (0-0)	a0.271
FOS (-)	0 (0-0)	0 (0-0)	0 (0-1)	0 (0-1)	0 (0-0)	a0.153
bp	0.999	0.999	0.564	0.999	0.999	
FT%						
FOS (+)	0 (0-0)	0 (0-0)	9 (5-20)	40 (30-50)	62.5 (30-67.5)	a0.001*
FOS (-)	0 (0-0)	0 (0-0)	17.5 (15-35)	50 (40-50)	35 (0-70)	a<0.001*
bp	0.999	0.999	0.248	0.096	0.655	
RG%						
FOS (+)	0.5 (0-2)	3 (0-4)	5 (5-10)	60 (50-70)	0 (0-0)	a<0.001*
FOS (-)	3.5 (1-10)	2.5 (0-3)	5 (5-5)	50 (40-50)	0 (0-0)	a<0.001*
bp	0.168	0.581	0.655	0.072	0.999	
Int						
FOS (+)	0 (0-0)	0 (0-0)	30 (20-45)	100 (100-100)	100 (100-100)	a<0.001*
FOS (-)	0 (0-0)	0 (0-0)	45 (25-60)	100 (100-100)	100 (100-100)	a<0.001*
bp	0.999	0.999	0.168	0.999	0.999	
FBR						
FOS (+)	0 (0)	0 (0)	2 (33.3)	1 (16.7)	1 (16.7)	c0.767
FOS (-)	0 (0)	0 (0)	3 (50)	1 (16.7)	2 (33.3)	c0.222
cp	‡-	‡-	0.999	0.999	0.999	
DNB						
FOS (+)	0 (0)	0 (0)	0 (0)	1 (16.7)	0 (0)	c0.999
FOS (-)	0 (0)	0 (0)	0 (0)	1 (16.7)	0 (0)	c0.999
cp	‡-	‡-	‡-	0.999	‡-	
Org						
FOS (+)						c<0.001*
Absent	6 (100)	0 (0)	0 (0)	0 (0)	0 (0)	
Complete-thin	0 (0)	3 (50)	4 (66.7)	0 (0)	0 (0)	
Complete-thick	0 (0)	3 (50)	2 (33.3)	6 (100)	6 (100)	
FOS (-)						c<0.001*
Absent	6 (100)	0 (0)	0 (0)	0 (0)	0 (0)	
Complete-thin	0 (0)	3 (50)	1 (16.7)	0 (0)	0 (0)	
Complete-thick	0 (0)	3 (50)	5 (83.3)	6 (100)	6 (100)	
ep	‡-	0.999	0.250	‡-	‡-	

FV: filling volume; NFB: newly formed bone; NB: necrotic bone; FT: fibrous tissue; RG: residual graft material; Int: integration; FBR: foreign body reaction; DNB: new bone formation at the defect's edge; Org: organization. The results for FV%, NFB%, NB%, FT%, RG%, and Int are presented as median (first quartile, third quartile), and those for FBR, DNB, and Org as frequency (percentage)., a Kruskal-Wallis test; b Wilcoxon signed-ranks test; c Fisher-Freeman-Halton exact test; d McNemar test; e McNemar Bowker test; ‡ Because the number of observations was insufficient, related analyzes could not be performed.

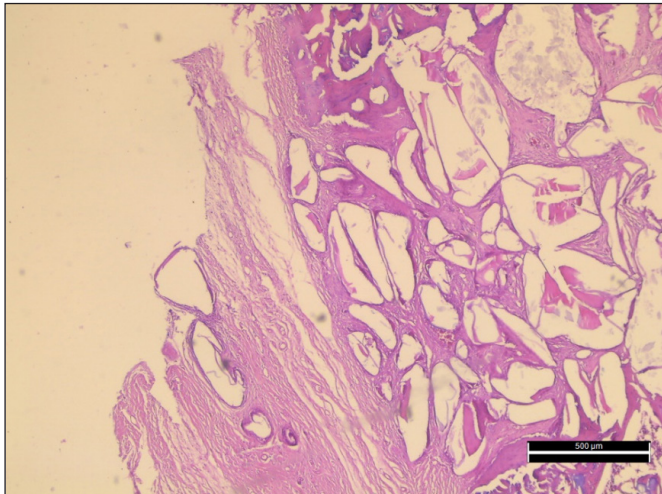


Figure 3. Group FOS (+) - Subgroup 5-In addition to thin fibrous bands, thin trabecular bone formation was observed, together with spaces of graft material pushed outward on the surface [6th week- With phosphatidylcholine (H&E, x40 magnification)]

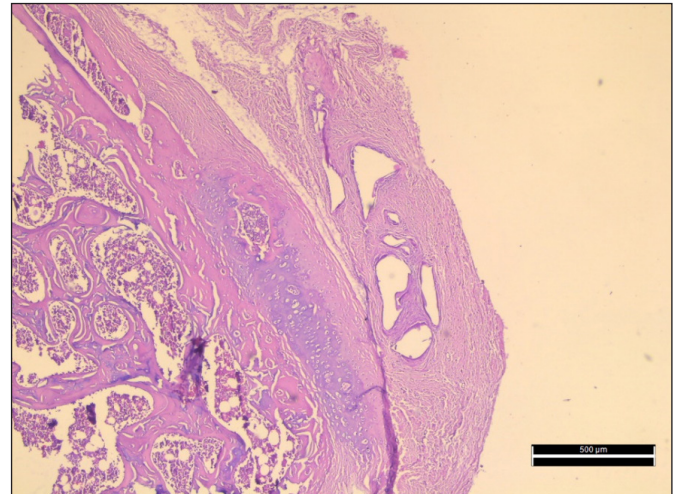


Figure 4. Group FOS (-) - Subgroup 5 -In addition to fibrous bands, trabecular bone formation and mature bone development from the hyaline cartilage were observed, together with spaces of residual graft material pushed outward on the surface [6th week- Without phosphatidylcholine (H&E, x40 magnification)]

DISCUSSION

This study aimed to histopathologically investigate whether BAG would be more effective in filling the critical defects with its osteoconductive effect in the presence of phosphatidylcholine. Femur defects were created bilaterally. BAG without any carrier was grafted to the created femur defect on one side, and BAG with phosphatidylcholine was grafted to the other side. The histopathological evaluation involved parameters of filling volume, newly formed bone, necrotic bone, fibrous tissue, residual graft material, graft integration, foreign body reaction, new bone formation at the defect's edge, and organization in time subgroups of 24 hours, 72 hours, seven days, three weeks, and six weeks. Statistical analysis of histopathological examination results revealed no difference between the group in which BAG was grafted together with phosphatidylcholine and the group that BAG was grafted alone. The defect was repaired similarly with BAG regardless of the presence of phosphatidylcholine as a carrier.

This study was the first study combining the use of BAG with phosphatidylcholine. It showed for the first time that using phosphatidylcholine as a carrier during BAG application neither augmented nor adversely affected bone healing promoted by BAG in a rat femur model. The histopathological examination revealed that bone formation occurred progressively. BAG with/without phosphatidylcholine degraded over time, was biocompatible, attracted osteoblasts, and permitted the new bone formation within the defect.

Various materials have been in clinical use for orthobiologics, either autologous such as bone and cartilage, heterologous such as animal-origin hydroxyapatite, or synthetics such as synthetic hydroxyapatite, calcium phosphate ceramic, and bioglass

(13). For example, silicate bioglass particles have been tested for their porosity as microspheres or their non-porous features in bone grafting (14). Moreover, Bioglass and its composites (particularly with polymers to facilitate the degradation process) are commonly applied because of their osteoinductive/conductive capabilities (15).

A very recent study by Zhang et al. (16) reported that BAG could facilitate wound healing, collagen deposition, and angiogenesis through inhibition of pyroptosis – a newly defined type of programmed cell death when used alone. On the other hand, various BAG composites have been investigated for use in specialties dealing with bone graftings/tissue engineering, such as orthopedics and dentistry. For example, Shi et al. (17) combined the recombinant human bone morphogenetic protein-9 (rhBMP-9) with carriers such as BAG and collagen membranes (BioGide) to utilize in the preservation of tooth extraction site in a very recently published study, and they found a dramatic difference between BAG and BioGide regarding absorption and slow/steady release of rhBMP-9. Another composite of BAG is prepared with chitosan-alginate. A very recently published study reported that, with the increasing amount of sodium alginate in the composite, the mineralization ability of Bioglass was enhanced, and the composite's mechanical strength significantly increased (18). In addition, endogenous bone regeneration was determined by Zheng et al. (19) to be promoted by 3D bioglass-nanoclay scaffolds mimicking hypoxia. A comparative experimental study conducted by Camargo et al. (20) in rabbits demonstrated that BAG was similarly effective regarding bone neoformation when compared to autografting. A recent review article by Karadjian et al. (21) concluded that BAG appeared to be useful for osteogenic differentiation supported the integration of

composites into the bone, enhancing bone formation. In summary, Bioglass has been numerous reported to be useful experimentally and clinically when used alone or combined.

On the other hand, although numerous studies have been conducted with substances added to BAG, we have met no study conducted using BAG in combination with phosphatidylcholine. Phosphatidylcholine has been used as a carrier for various substances, particularly antibiotics (22). Regarding bone induction, studies conducted with phosphatidylcholine are few. For example, in their study evaluating the combined effects of phosphatidylcholine and demineralized bone matrix on bone induction, Han et al. (23) reported that phosphatidylcholine boosted the material's osteoconductivity features besides its enhanced handling properties. Furthermore, a recent study by Harahaliloglu and Kilicay (24) investigated the bone cement impregnated with selenium nanoparticles stabilized by phosphatidylcholine to apply in bone and concluded that it was an effective graft material. However, since we have met no publication using BAG and phosphatidylcholine in combination, we cannot make a detailed comparison with the literature.

CONCLUSION

Our study found no difference between the bioglass groups with and without phosphatidylcholine regarding the evaluated histological parameters. Furthermore, healing proceeded flawlessly and was accomplished regardless of the presence of phosphatidylcholine in the material. These results indicated that Bioglass served efficiently for filling the defect, and the presence of phosphatidylcholine neither augmented nor impaired the healing process, suggesting that when various materials, such as antibiotics, are needed to be added to the grafting process with Bioglass, phosphatidylcholine can be used as a carrier. However, such a suggestion should be tested with further experimental studies until its clinical application is implemented.

ETHICAL DECLARATIONS

Ethics Committee Approval: The study was carried out with the permission of The Animal Experiments Local Ethics Committee in Acibadem University approved the study protocols with the report (Date: 14.02.2019, Decision No: ACU-HAYDEK 2019/16).

Referee Evaluation Process: Externally peer-reviewed.

Conflict of Interest Statement: The author has no conflicts of interest to declare.

Financial Disclosure: The author declared that this study has received no financial support.

Author Contributions: The author declare that they have all participated in the design, execution, and analysis of the paper, and that they have approved the final version.

Acknowledgements: I would like to express my sincere thanks to Prof. Dr. Mustafa Harun Gürsoy for her practical suggestions and constructive criticisms during the creation of the article.

REFERENCES

1. Hench LL. Bioceramics: from concept to clinic. *J Am Ceramic Soc* 1991; 74: 1487–510.
2. Hench LL, Polak JM. Third-generation biomedical materials. *Science* 2002; 295: 1014–7.
3. El-Rashidy AA, Roether JA, Harhaus L, Kneser U, Boccaccini AR. Regenerating bone with bioactive glass scaffolds: A review of in vivo studies in bone defect models. *Acta biomaterialia* 15; 62: 1–28.
4. Romano AM, Ascione T, Casillo P, et al. An evolution of shoulder periprosthetic infections management: MicroDTTect, Bioactive Glass and Tantalum Cones Employment. *Journal of Clinical Medicine* 2020; 9: 3683.
5. Hench LL, Splinter RJ, Allen WC, Greenlee TK. Bonding mechanisms at the interface of ceramic prosthetic materials. *J Biomed Materials Res Part A* 1971; 5: 117–141.
6. Hupa L. Melt-derived bioactive glasses. *Bioactive glasses*. Woodhead Publishing 2011; 3–28.
7. Jones JR. Review of bioactive glass: from Hench to hybrids. *Acta Biomaterialia* 2013; 9: 4457–86.
8. Jennings JA, Carpenter DP, Troxel KS, et al. Novel antibiotic-loaded point-of-care implant coating inhibits biofilm. *Clin Orthopaed Related Res* 2015; 473; 2270–82.
9. Jennings JA, Beenken KE, Skinner RA, et al. Antibiotic-loaded phosphatidylcholine inhibits staphylococcal bone infection. *World J Orthopedics* 2016; 7; 467–74.
10. Klein A, Baranowski A, Ritz U, et al. Effect of bone sialoprotein coating on progression of bone formation in a femoral defect model in rats. *Eur J Trauma Emerg Surg* 2020; 46: 277–86.
11. Fricain JC, Schlaubitz S, Le Visage C, et al. A nano-hydroxyapatite-pullulan/dextran polysaccharide composite macroporous material for bone tissue engineering. *Biomaterials* 2013; 34: 2947–59.
12. Uraz A, Gultekin SE, Senguven B, et al. Histologic and histomorphometric assessment of eggshell-derived bone graft substitutes on bone healing in rats. *J Clin Exp Dent* 2013; 5: 23–29.
13. Sahli-Vivicorsi S, Alavi Z, Bran W, et al. Mid-term outcomes of mastoid obliteration with biological hydroxyapatite versus bioglass: a radiological and clinical study. *Eur Arch Otorhinolaryngol* 2022; 10.1007: s00405-022-07262-5.
14. Towhidul I, Nuzulia NA, Macri-Pellizzeri L, Nigar F, Sarı YW, Iftı A. Evolution of silicate bioglass particles as porous microspheres with a view towards orthobiologics. *J Biomaterials Applicat* 2022; 36: 1427–43.
15. Magri AMP, Fernandes KR, Kido HW, et al. Bioglass/PLGA associated to photobiomodulation: effects on the healing process in an experimental model of calvarial bone defect. *J Mater Sci Mater Med* 2019; 30: 105.
16. Zhang K, Bo C, Hao JJ, et al. Bioglass promotes wound healing by inhibiting endothelial cell pyroptosis through regulation of the connexin 43/reactive oxygen species (ROS) signaling pathway. *J Technical Methods Pathol* 2022; 102: 90–101.
17. Shi P, Zhou W, Dong J, Li S, Lv P, Liu C. Scaffolds of bioactive glass (Bioglass®) combined with recombinant human bone morphogenetic protein -9 (rhBMP-9) for tooth extraction site preservation. *Heliyon* 2022; 8: 08796.

18. Shi C, Hou X, Zhao D, Wang H, Guo R, Zhou Y. Preparation of the bioglass/chitosan-alginate composite scaffolds with high bioactivity and mechanical properties as bone graft materials. *J Mech Behav Biomed Mater* 2022; 126: 105062.
19. Zheng X, Xiaorong Z, Yingting W, et al. Hypoxia-mimicking 3D bioglass-nanoclay scaffolds promote endogenous bone regeneration. *Bioactive Materials* 2021; 6: 3485–95.
20. Camargo De F, Ferrari A, Baptista AM, Natalino R, De Camargo OP. Bioactive glass in cavitary bone defects: a comparative experimental study in rabbits. *Acta Ortopedica Brasileira* 2015; 23: 202–7.
21. Karadjian M, Essers C, Tsitlakidis S, et al. Biological Properties of calcium phosphate bioactive glass composite bone substitutes: current experimental evidence. *Int J Mol Sci* 2019; 20: 305.
22. Zhu CT, Yong Qing XU, Jian SHI, Jun LI, Jing DING. Liposome combined porous β -TCP scaffold: Preparation, characterization, and anti-biofilm activity. *Drug Delivery* 2010; 17: 391–8.
23. Han, B, Tang B, Nimni ME. *Connective Tissue RESEARCH*. Combined effects of phosphatidylcholine and demineralized bone matrix on bone induction. Taylor & Francis. 2003; 44: 160–6.
24. Karahaliloglu Z, Kilicay E. In vitro evaluation of bone cements impregnated with selenium nanoparticles stabilized by phosphatidylcholine (PC) for application in bone. *Journal of Biomaterials Applications* 2020; 35: 385–404.