

## PAPER DETAILS

TITLE: Surgical treatment of liver hydatid cyst and evaluation of cystobiliary fistula: experience of two centers

AUTHORS: Hayrettin DIZEN,Berrin YALINBAS KAYA

PAGES: 942-948

ORIGINAL PDF URL: <https://dergipark.org.tr/tr/download/article-file/2412654>

# Surgical treatment of liver hydatid cyst and evaluation of cystobiliary fistula: experience of two centers

Hayrettin Dizen<sup>1</sup>, Berrin Yalınbaş Kaya<sup>2</sup>

<sup>1</sup>Eskişehir Acıbadem Hospital, Department of General Surgery, Eskişehir, Turkey

<sup>2</sup>Eskişehir City Hospital, Department of Gastroenterology, Eskişehir, Turkey

**Cite this article as:** Dizen H, Yalınbaş Kaya B. Surgical treatment of liver hydatid cyst and evaluation of cystobiliary fistula: experience of two centers. J Health Sci Med 2022; 5(4): 942-948.

## ABSTRACT

**Objective:** Intrabiliary rupture or cystobiliary fistula is the most common complication of hepatic hydatid cyst. In this article, our objective is to evaluate the clinical, laboratory, imaging, surgical treatment and results of cystobiliary fistulas, which is the most common complication of hydatid cysts.

**Material and Method:** In our study, patients who underwent open surgery and were followed up and treated for hydatid cyst in the gastroenterology and general surgery outpatient clinic and service between years 2015-2021 were included. The clinical, laboratory, radiological and surgical results of 171 patients with hydatid cysts were retrospectively analyzed.

**Results:** The mean age of 171 patients who underwent surgery for hydatid cyst was 44.8 (18-71), 68 of whom were men and 103 were women. Bile leakage was present in 50 patients (50 (29.23%)). There were 24 (48%) men and 26 (52%) women with bile leakage. The cyst diameter was 74.2 (36-170) mm and the number of cysts was 1.2 (1-2). The cysts were located in the right lobe of the liver in 116 (79%) patients, in the left lobe in 30 (15%) patients, and in both lobes in 25 (6%) patients. Cystobiliary fistula developed more frequently, especially in cysts located in the right lobe (36 (72%)). Cystobiliary fistula was most common in CE3 (Gharbi type 2) type (30 (60%)). Cystectomy+drainage was performed in 137 (80%) patients in all groups. Cystectomy and drainage were the most common surgical procedures. The cyst diameter was 10 cm in the group with cystobiliary fistula and was significant compared to the group without fistula ( $p<0.001$ ). Aminotransferase (AST and ALT) levels were high in patients with cystobiliary fistula ( $p=0.012$ ,  $p=0.054$ ). However, there was no significant difference between the two groups in alkaline phosphatase, total bilirubin, and gamma glutamyl transferase ( $p=0.231$ ,  $p=0.097$ ,  $p=0.544$ ).

**Conclusion:** Liver hydatid cyst is endemic in our country as well as in many other countries in the world. Complicated hepatic hydatid cysts require timely and appropriate treatment because of their life-threatening complications. Cystobiliary fistula is the most common complication. In the surgical treatment of hydatid cyst disease, the earlier the diagnosis of occult cystobiliary fistulas is made (especially in the preoperative or peroperative period), the easier the treatment is, and the risk of bile leakage and consequently the morbidity and mortality decreases. Our results and experience showed that treatment and complications are related to the location and size of the cyst, occult/large cystobiliary fistula, detectability of occult fistulas, experienced center and surgeon.

**Keywords:** Liver hydatid cyst, surgical treatment, cystobiliary fistula

## INTRODUCTION

Hepatic cystic echinococcosis (HCE), caused by *Echinococcus granulosus* (*E. granulosus*), is a zoonotic parasitic disease and approximately 4000 patients are diagnosed with hydatid cyst per year in Turkey (1-3). It is endemic in Mediterranean countries, the Middle East, Central Asia, South America, Africa, Australia and New Zealand. *E. granulosus* is a parasite that is found as larva in the canine intestine and in cyst forms in nature, dogs are the main host and humans are the intermediate host (4,5). The cycle of the parasite in humans starts

with the opening of orally ingested cysts in the intestine, and then the parasite larvae join the blood circulation through the portal system and settle in the target organs, especially the liver. Echinococcal groups; *E. granulosus*, *E. multilocularis*, *E. oligarthrus* and *E. vogeli*. *E. granulosus* is most frequently responsible for cystic formation. It is usually localized in the liver (68.8-80%) and lungs (10-22.4%). Spleen (0.9-8%), skeleton (0.2-3%), kidney (0.4-3.7%), brain (0.4-1%), cardiac muscle (0.02-1.1%), peritoneum (2-5.2%) are localizations where it is rarely

localized (4-6). The pericyst, the outermost layer of the cyst, is a fibrous layer. Inside, there is acellular, laminar membrane. Cellular germinative membrane covers the inner surface of the laminar membrane. They are cystitic, spherical, fluid-filled, unilocular vesicles. It is usually asymptomatic. Infection and continuous growth of the cyst may cause compression, erosion, and adhesion to adjacent structures. As the intracystic pressure rises from 30-35 cm H<sub>2</sub>O to 80 cm H<sub>2</sub>O, inflammation leads to necrosis, causes rupture or fistulization (7,8). The most common symptoms are abdominal pain, palpable mass in the right upper quadrant, hepatomegaly. Cholangitis, jaundice, fever, anaphylaxis and acute abdominal pain are symptoms of complicated hydatid disease (9,10). The most common complications of hepatic hydatid cyst are fistulization to the intrahepatic bile ducts, pressure on the surrounding organs and infection. The rates of intrabiliary rupture or cystobiliary fistula vary between 2% and 42% in various studies in the literature (11,12). Ultrasonography (USG) is the basic imaging method for the diagnosis of echinococcosis. However, computed tomography (CT) and magnetic resonance imaging (MRI/MRCP) are important in determining the characteristics of the cyst and its relationship with adjacent structures. In addition to imaging methods, serological tests such as enzyme-linked immunosorbent assay (ELISA), immunoblotting (IB) and indirect immunofluorescent antibody test (IFA) are used for diagnosis (13). The World Health Organization's Working Group on Echinococcosis (WHO-IWGE) standardized the classification system for liver hydatid cysts in 2001. The WHO classification is now used for staging and treatment selection. While cysts smaller than 5 cm (WHO stages CE1 and CE3a) are treated with only albendazole, PAIR and albendazole therapies are recommended for cysts larger than 5 cm. There is frequent relapse in PAIR therapy for patients with CE2 and CE3b cysts. While surgical treatment was once the most common treatment modality, it is now largely applied for complicated cysts (such as biliary fistula or perforated cysts) (CE2, CE3b). In addition, surgical treatment is a suitable treatment option for superficial cysts larger than 10 cm or at risk of rupture and for patients who are not suitable for percutaneous treatment. Surgical treatment options include open surgery and laparoscopic surgery (14-16).

Our aim in this study was to compile the frequency of association between hydatid cyst and biliary tract, clinical and laboratory features, diagnosis and treatment results.

## MATERIAL AND METHOD

The study was initiated with the approval of the Eskişehir Osmangazi University Non-interventional Clinical

Researches Ethics Committee (Date: 18.01.2022, Decision No: 05). All procedures were carried out in accordance with the ethical rules and the principles of the Declaration of Helsinki.

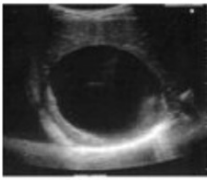






Between years 2015 and 2021 Patients who were followed up and operated due to hydatid cyst in gastroenterology and general surgery were included in the study by screening retrospectively. Age, gender, laboratory data, cyst structure and staging according to imaging, cyst diameter and location (right lobe (V, VI, VII, VIII), left lobe (II, III, IV), bilateral), perioperative results, the operative results of the patients who were operated on for hydatid cysts were documented by examining the records of the patients. Complete blood count and liver function tests (alkaline phosphatase (ALP),  $\gamma$ -glutamyl transferase (GGT), alanine aminotransferase (ALT), aspartate aminotransferase (AST) and bilirubin) of all patients were taken from the system. The type of operation (cystectomy drainage+omentoplasty, cystectomy drainage, resection) and whether there was a biliary fistula during the operation were recorded. The cysts were classified radiologically with the WHO (Gharbi) classification (**Table 1**) (**Figure 1**).

**Table 1.** WHO-IWGE (Gharbi) classification (13,16)

CL. Anechogenic uniloculated cyst, without echo or internal septa
CE 1 (Gharbi type 1). Anechogenic cyst with fine echoes inside
CE 2 (Gharbi type 2). A multivesicular appearance with multiple septums- active cyst
CE 3 (Gharbi type 3). Fluid between the cyst membrane ("waterlily sign") (CE3a) or (Gharbi type 2), Daughter vesicles (CE3b) associated with hypo/hyperechoic images-cyst in the transitional phase
CE 4 (Gharbi type 4). Mixed content, hypo/hyperechogenic, no offspring vesicle cyst-"wool clew" appearance-cyst in degenerative phase
CE 5 (Gharbi type 5). Partial or completely calcified wall cyst-inactive cyst

Patients who were diagnosed with hydatid cyst preoperatively by imaging (CT/MRI, ultrasound) and laboratory (ELISA, biochemistry tests) tests and operated were included in the study. Patients with a lack of imaging and pathological diagnosis and who had a large cystobiliary fistula in the preoperative period who showed cholangitis clinic were excluded from the study. All patients received albendazole treatment for at least 3 months, starting 10 to 15 days before the operation.

The operation procedures were chosen by the surgeons. In all operations, prophylactic antibiotics (cefazolin 1 g) were given to the patients 20 minutes before general anesthesia. All patients were operated on by open surgery method. After entering the abdomen by applying a midline, subcostal or makuuchi incision, abdominal exploration was performed. Liver ligaments were cut and mobilized sufficiently for the exploration

Gharbi	I	II	III	IV	V
					
WHO	CE1	CE3a	CE2	CE4	CE5
					
CL			CE3b		

**Figure 1.** Comparison of Gharbi and WHO-IWGE ultrasound classification (16)

of the cyst cavity and ligation to be performed on the wall. During the evacuation of the cyst, compresses or gas pads impregnated with 3% hypertonic saline solution were placed around the cyst in order to prevent the spread of the parasite. The cyst content was aspirated by puncture into the cyst, and the aspirated cyst content was examined for bile contamination. Three percent hypertonic solution was filled from the puncture site to the cyst until high pressure was created. After waiting for about 10 minutes, the cyst was opened wide from the dome and its contents were evacuated in a controlled manner. If there were areas with apparent bile leakage in the cavity wall, they were sutured with 3/0 prolene. Then, long gas pads impregnated with 3% hypertonic solution were placed into the cavity to control both the repaired areas and detect occult fistulas. After waiting for about 5 minutes, the gas buffers placed in the cavity in a controlled manner were removed and it was checked whether there was bile contamination. Repairs were made to the places where bile contamination was detected until the bile contamination was over. After the cavity wall was sutured for hemostasis with absorbable sutures, a drain was placed into the cyst and the operation was terminated. Patients with apparent cystobiliary fistula of the biliary tract are diagnosed with radiology and laboratory examinations before the operation. However, preoperative diagnosis of occult cystobiliary fistula is very difficult. Occult cystobiliary fistulas can usually be diagnosed by the presence of bile leakage in the cyst cavity during the operation or by the bile flow from the patient's drains after the operation. In patients with large cystobiliary fistulas, if intraoperative bile leakage persisted despite suturing, T-tube drainage and choledochoduodenostomy were performed. A Roux-en-Y type pericystojejunostomy may be preferred

in large fistulas opened to the main biliary tract or if the cavity is large. Patients with high-volume (over 300 cc) biliary drainage were followed up for an average of 7-10 days after surgery. ERCP was planned in cases with no decrease in biliary drainage and bile leakage was treated through ERCP by sphincterotomy, nasobiliary drainage or biliary stent placement. The drains were kept for three days after surgery and were removed when there was no bile leakage. If bile drainage continued, the drains were held in place until drainage stopped.

### Statistical Analysis

SPSS 23.0 package software was used for statistical analysis of the data. Categorical measurements are presented as numbers and percentages, and continuous measurements as mean and standard deviation (median and minimum-maximum when necessary). Chi-square or Fisher's exact tests were used to compare categorical variables. The Mann-Whitney U test was used to compare continuous variables with variables such as the type of surgery. Statistical significance level was accepted as less than 0.05 in all tests.

### RESULTS

The mean age of 171 patients who underwent surgery for hydatid cyst was 44.8 (18-71), 68 of whom were male and 103 were female. Bile leakage was present in 50 patients (50 (29.23%)). There were 24 (48%) male and 26 (52%) female with bile leakage. The cyst diameter was 74.2(36-170) mm and the number of cysts was 1.2 (1-2) (**Table 2**). The cysts were located in the right lobe of the liver in 116 (79%) patients, in the left lobe in 30 (15%) patients, and in both lobes in 25 (6%) patients. Cystobiliary fistula developed more frequently, especially in cysts located in the right lobe (36 (72%)). Cystobiliary fistula was

most common in CE3a (Gharbi type 2) type (30 (60%)). Cystectomy+drainage was performed in 137 (80%) patients in all groups. Cystectomy and drainage were the most common surgical procedures. Demographic, laboratory and clinical features of patients with and without cystobiliary fistula were compared (**Table 3**, **Table 4**). There was no statistically significant difference in age and gender between the two groups, respectively ( $p=0.903$ ,  $p=0.214$ ) (**Table 3**). Nine (18%) patients with cystobiliary fistula were bilateral, 36 (72%) on the right, 5 (10%) on the left, and it was not statistically significant ( $p=0.543$ ). In subgroup analysis, right lobe location was statistically significant compared to left ( $p=0.003$ ). The cyst diameter was 10 cm in the group with cystobiliary fistula and was significant compared to the group without fistula ( $p<0.001$ ). Aminotransferase (AST and ALT) levels were high in patients with cystobiliary fistula ( $p=0.012$ ,  $p=0.054$ ). However, there was no significant difference between the two groups in alkaline phosphatase, total bilirubin, and gamma glutamyl transferase ( $p=0.231$ ,  $p=0.097$ ,  $p=0.544$ ) (**Table 4**).

**Table 3.** Comparison of patient groups with and without cystobiliary fistula

	Cystobiliary fistula, Yes N %	Cystobiliary fistula, No N %	Total N %
*Age	44.9 (18-71)	45.01 (15-70)	44.8 (15-71)
Gender			
Male	24 (48%)	44 (36.4%)	68 (39.8%)
Female	26 (52%)	77 (63.6%)	103 (60.2%)
Total	50 (100%)	121 (100%)	171 (100%)
Cyst location			
Bilateral	9 (18%)	21 (17.4%)	30 (17.5%)
Right	36 (72%)	80 (66.1%)	116 (67.8%)
Left	5 (10.0%)	20 (16.5%)	25 (14.6%)
Total	50 (100%)	71 (100%)	171 (100%)
**Cyst type			
1(CE1)	1 (2.0%)	4 (3.3%)	5 (2.9%)
2(CE3a)	4 (8.0%)	27 (22.3%)	31 (18.1%)
3(CE2;C3b)	30 (60%)	68 (56.2%)	98 (57.3%)
4(CE4)	14 (28%)	22 (18.2%)	36 (21.1%)
5(CE5)	1 (2.0%)	0 (0.0%)	1 (0.6%)
Total	50 (100%)	121 (100%)	171 (100%)
Cyst size(mm)	100 (60-170)	63.92 (36-110)	74.2 (36-170)
Number of cyst	1.41 (1-2)	1.34 (1-2)	1.2 (1-2)
Surgical procedure			
Cystectomy+ -omentoplasty	10 (20.4%)	14 (11.6%)	24 (14.1%)
Cystectomy drainage	38 (77.6%)	99 (81.8%)	137 (80.6%)
Resection	1 (2%)	8 (6.6%)	9 (5.3%)
Total	49 (100%)	121 (100%)	170 (100%)

\*Mean(Max-Min) \*\*Gharbi classification

**Table 2.** Demographic and clinical data of liver hydatid cysts

	N %	Total N	P value
Gender		171	
Male	68 (39.77%)		0.398
Female	103 (60.23%)		0.602
*Age	44.8 (18-71)	171	0.903
Cyst size(mm)	74.2 (36-170)	171	<0.001
*Number of cyst	1.2 (1-2)	171	0.372
Cyst location		171	
Bilateral	30 (17.5%)		0.175
Right	116 (67.8%)		0.678
Left	25 (14.6%)		0.146
Cystobiliary fistula		171	
Positive	50 (29.23%)		0.292
Negative	121 (70.77%)		0.708
**Cyst type		171	
1 (CE1)	5 (2.9%)		0.029
2 (CE3a)	31 (18.1%)		0.181
3 (CE2;C3b)	98 (57.3%)		0.573
4 (CE4)	36 (21.1%)		0.211
5 (CE5)	1 (0.6%)		0.006
Surgical procedure		170	
Cystectomy+ omentoplasty	24 (14.1%)		0.141
Cystectomy drainage	137 (80.6%)		0.806
Resection	9 (5.3%)		0.053

\*Mean(Max-Min) \*\*Gharbi classification

**Table 4 .** Cystobiliary fistula and laboratory results

	Cystobiliary fistula		Total	P value
	Yes	No		
	Median (Min-Max)			
AST (U/L)	44.03 (15-328)	32.9 (11-145)	36.1 (11-328)	0.012*
ALT (IU/L)	45.6 (9-268)	37.1 (10-215)	39.4 (9-268)	0.054
ALP (IU/L)	96.2 (33-281)	105.8 (39-201)	102 (33-281)	0.231
GGT (IU/L)	44.2 (19-95)	46.6 (20-90)	45.7 (19-95)	0.544
Total bilirubin (mg/dl)	2.5 (0.25-9)	4 (0-9)	3.51 (0.25-9)	0.097

## DISCUSSION

Intrabiliary rupture or cystobiliary fistula is the most common complication of hepatic hydatid cyst and occurs in 3-42% of cases (11,12,17). While the pressure of a normal bile duct system is 15-20 cm H<sub>2</sub>O, there is a pressure of about 35 cm H<sub>2</sub>O in the cystic cavity of hydatid cysts. Due to this pressure difference, bile does not fill into the cyst unless the hydatid cyst is drained, even if there is a connection between the hydatid cyst and the bile ducts (11,18,19). If structures belonging to hydatid cysts (membrane fragments, daughter vesicles) ie typical radiological features are seen in the biliary tract, ultrasound and CT are diagnostic for large fistulas, but occult cystobiliary fistulas are usually detected during or after the operation by the discharge of biliary



fluid from their drains (20,21). If cystobiliary fistula is diagnosed before or during surgery, postoperative morbidity and development of bile leakage occur at a lower rate. Cystobiliary fistula may be 3-17% large fistula (major,  $\geq 5$  mm) or 10-37% occult (minor,  $< 5$  mm) (10,19-21). It is known that large fistulas can cause cholangitis, acute pancreatitis, acute cholecystitis and sepsis (19,20-23). The prevalence of cystobiliary fistula was reported as 27% by Kayaalp et al. (25), 28.4% by Demircan et al. (24), 28.1% by Wang et al. (7). A cystobiliary fistula was detected in 29.2% of 171 patients who underwent open surgery. The frequency of cystobiliary fistula in our study was consistent with the results of the studies in the literature.

There was no statistically significant difference between the groups in terms of gender and age in patients with cystobiliary fistula ( $P=0.903$ ,  $p=0.214$ ). However, hydatid cyst operation was performed more frequently in women in the group without cystobiliary fistula (44 (36.4%), 77 (63.6%)). Liver hydatid cyst is common in women. It is usually asymptomatic despite being infected in childhood. The reason for this is that it is determined in decade 3rd-4th due to hydatid cyst grows 1-5 mm per year (14,16, 26-28).

Studies have shown that 85-90% of hydatid cysts involve a single organ and more than 70% of them had a single cyst (27). In our study, the mean number of cysts in the liver was 1.2. Liver hydatid cyst is located in the right lobe in 72%. In our study, the number of hydatid cysts was 116 (67.8%) and cystobiliary fistulas were most frequent in right lobes with the number of 36 (72%). In the literature, cystobiliary fistulas were located in the right lobe in correlation with our study (30-33). Kayaalp et al. (25) reported that cystobiliary fistula was most common (48%) in segments close to the liver hilum (segments I, III, IVb, V and VI), and when Dziri et al. (34) differentiated the cyst according to the position of the cyst relative to the diaphragm (supra-diaphragmatic II, VII, VIII and sub-diaphragmatic III, IV, V, VI), they found cystobiliary fistula under the diaphragm to be common. In addition to cyst localization, cyst diameter was also associated with the development of cystobiliary fistula. The mean cyst diameter was 10 cm in patients with cystobiliary fistula, compared to 6.2 cm in patients without cystobiliary fistula. ( $p=0.001$ ). In the literature, cyst diameter is associated with the risk of cystobiliary fistula even in asymptomatic patients. There is a 79% probability of cystobiliary fistula in cysts larger than 7.5 cm in diameter (35,36).

The main aim of surgical treatment of hepatic hydatid cyst is to treat the existing disease with minimal complications. It is necessary to clean the contents of the cyst and prevent it from spreading into the

abdomen, and to minimize cyst cavity as much as possible. In our clinic, surgical treatment was performed for complicated cysts, large sizes of CE2-CE3b, infected cysts, cysts with intrabiliary rupture, and cysts that cause compression symptoms to adjacent organs (16,37,38). One hundred twenty nine (78.4%) patients those operated on were CE2 CE3b type hydatid cysts. Forty-two (21.6%) cysts were in the CE 1,4,5 group and surgical treatment was applied because there were complicated cysts. Cystobiliary fistula was most frequent in the CE3 patient group (30 (60%)). The reason for this was thought to be related to the fact that the surgical operation indication for hydatid cyst was the most common in the CE3 group. Atlı et al. (21) also stated that Type III cysts are more complicated than other cysts.

Surgical treatments are conservative and radical surgeries (10,39,40). Conservative surgery includes obliteration of the cavity, external or internal drainage, omentoplasty, capitonation and is generally safer than radical surgery. In radical surgery, total or partial pericystectomy and hepatic resection are performed. More intraoperative complications may develop in radical surgery (16,24,41). The choice of surgical technique varies according to the characteristics of the cyst and the experience of the hepatobiliary surgeon. Conservative treatment is the surgical method mostly preferred in endemic areas (10,40). Kayaalp et al. (38) stated that the control of bile leakage during the operation in hydatid cyst surgery reduces biliary complications, especially permanent bile fistulas. Despite conventional methods such as methylene blue, contrast, etc., during the operation, only some of the multiple occult cystobiliary fistulas could be detected. However, in recent years, after our bile leakage controls with lipid solutions in hydatid cyst surgery with cystobiliary fistula, we repaired it with nonabsorbable sutures and no bile leakage was found after the operation. Cystectomy+drainage+omentoplasty, cystectomy+drainage were the most frequently performed surgical procedures in our patients with cystobiliary fistula (10 (20.4%), 38 (77.6%)) (Table 3). In patients with large cystobiliary fistulas, T-tube drainage and choledochoduodenostomy were performed if intraoperative bile leakage persisted despite suturing. A Roux-en-Y type pericystojejunostomy may be preferred in large fistulas opened to the main biliary tract or if the cavity is large. Bile leakage was not detected in any of the follow-ups of the patients who underwent T-tube drainage and choledochoduodenostomy. Biloma, biliary peritonitis, or abscess development which are secondary complications to bile leakage were not recorded in the postoperative follow-ups.

## CONCLUSION

Liver hydatid cyst is endemic in our country as well as in many other countries in the world. Complicated hepatic hydatid cysts require timely and appropriate treatment because of their life-threatening complications. Cystobiliary fistula is the most common complication. In the surgical treatment of hydatid cyst disease, the earlier the diagnosis of occult cystobiliary fistulas is made (especially in the preoperative or peroperative period), the easier the treatment is, and the risk of bile leakage and consequently the morbidity and mortality decreases. Our results and experience showed that treatment and complications are related to the location and size of the cyst, occult/large cystobiliary fistula, detectability of occult fistulas, experienced center and surgeon.

## ETHICAL DECLARATIONS

**Ethics Committee Approval:** The study was initiated with the approval of the Eskişehir Osmangazi University Non-interventional Clinical Researches Ethics Committee (Date: 18.01.2022, Decision No: 05).

**Informed Consent:** Because the study was designed retrospectively, no written informed consent form was obtained from patients.

**Referee Evaluation Process:** Externally peer-reviewed.

**Conflict of Interest Statement:** The authors have no conflicts of interest to declare.

**Financial Disclosure:** The authors declared that this study has received no financial support.

**Author Contributions:** All of the authors declare that they have all participated in the design, execution, and analysis of the paper, and that they have approved the final version.

## REFERENCES

- Salamone G, Licari L, Randisi B, et al. Uncommon localizations of hydatid cyst. Review of the literature. *G Chir* 2016; 37: 180-5.
- Çiçek B, Parlak E, Dişibeyaz S, Oğuz D, Cengiz C, Şahin B. Endoscopic therapy of hepatic hydatid cyst disease in preoperative and postoperative settings. *Dig Dis Sci* 2007; 52: 931-5.
- Altıntaş N. Cystic and alveolar echinococcosis in Turkey. *Ann Trop Med Parasitol* 1998; 92: 637-42.
- Kammerer WS, Schantz PM. Echinococcal disease. *Infect Dis Clin North Am* 1993; 7: 605-18.
- Bayrak M, Altıntaş Y. Current approaches in the surgical treatment of liver hydatid disease: single center experience. *BMC Surg* 2019; 17: 19: 95.
- Akcan A, Sözüer E, Akyıldız H, Öztürk A, Atalay A, Yılmaz Z. Predisposing factors and surgical outcome of complicated liver hydatid cysts. *World J Gastroenterol* 2010; 28: 3040-8.
- Wang Z, Xu J, Pang MQ, et al. nomogram analysis and internal validation to predict the risk of cystobiliary communication in patients undergoing hydatid liver cyst surgery. *World J Surg* 2020; 44: 3884-92.
- Mihmanli M, Idiz MU, Kaya C, et al. Current status of diagnosis and treatment of hepatic echinococcosis. *Rev World J Hepatol* 2016; 8: 1169-81.
- Botezatu C, Mastalier B, Patrascu T. Hepatic hydatid cyst - diagnose and treatment algorithm. *J Med Life* 2018; 11: 203-9.
- Sözüer E, Akyüz M, Akbulut S. Open surgery for hepatic hydatid disease. *Int Surg* 2014; 99: 764-9.
- Ramía JM, Figueras J, De la Plaza R, García-Parreño J. Cystobiliary communication in liver hydatidosis. *Langenbecks Arch Surg* 2012; 397: 881-7.
- Uylas U, Tardu A and Kayaalp C. Bile leakage test in emergency hydatid liver cyst surgery. *Int J Surg Case Rep* 2021; 79: 459-61.
- Wen H, Vuitton L, Tuxun T, et al. Echinococcosis: advances in the 21st century. *Clin Microbiol Rev* 2019; 13: 32
- Romig T, Zeyhle E, Macpherson CN, Rees PH, Were JB. Cyst growth and spontaneous cure in hydatid disease. *Lancet* 1986; 861.
- Wang Y, He T, Wen X, et al. Post-survey follow-up for human cystic echinococcosis in northwest China. *Acta Trop* 2006: 43-51.
- Brunetti E, Kern, P, Vuitton DA. Writing Panel for the WHO-IWGE. Expert consensus for the diagnosis and treatment of cystic and alveolar echinococcosis in humans. *Acta Trop* 2010; 114: 1-16.
- Fancellu A, Perra T, Vergari D, et al. Management of complex liver cystic hydatidosis: challenging benign diseases for the hepatic surgeon: A case series report from an endemic area. *Comparative Study Med* 2020; 25: 99.
- Lewall DB, McCorkell SJ. Rupture of echinococcal cysts: diagnosis, classification, and clinical implications. *AJR Am J Röntgenol* 1986; 146: 391-4.
- Prousalidis J, Kosmidis C, Kapoutzis K, Fachantidis E, Harlaftis N, Aletras H. Intrabiliary rupture of hydatid cysts of the liver. *Am J Surg* 2009; 197: 193-8.
- Zargar SA, Khuroo MS, Khan BA, et al. Intrabiliary rupture of hepatic hydatid cyst: sonographic and cholangiographic appearances. *Gastrointest Radiol* 1992: 1741- 5.
- Atli M, Kama NA, Yuksek YN. Intrabiliary rupture of a hepatic hydatid cyst associated clinical factors and proper management. *Arch Surg* 2001; 136: 1249-55.
- El Malki HO, Mejdoubi Y, Souadka A, Mohsine R, Ifrine L, Abouqal R. Predictive factors of deep abdominal complications after hydatid cysts of the liver: 15 years of experience with 672 patients reply. *J Am Coll Surg* 2010; 206: 629-37.
- Kornaros SE, Aboul-Nour TA. Frank intrabiliary rupture of hydatid hepatic cyst: diagnosis and treatment. *J Am Coll Surg* 1996; 183: 446-70.
- Demircan O, Baymus M, Seydaoglu G, et al. Occult cystobiliary communication presenting as postoperative biliary leakage after hydatid liver surgery: are there significant preoperative clinical predictors. *Can J Surg* 2006; 49: 177-84.
- Kayaalp C, Bostancı B, Yol S, Akoglu M. Distribution of hydatid cysts into the liver with reference to cystobiliary communications and cavity-related complications. *Am J Surg* 2003; 185: 175-9.
- Mihăilă DE, Potecă TD, Potecă A, Pițuru S. Single-centre epidemiological study on the incidence of hepatic hydatid cyst. *Rom J Intern Med* 2015; 53: 170-3.
- Bhutani N, Kajal P. Hepatic echinococcosis: A review. *Ann Med Surg (Lond)* 2018; 36: 99-105.
- Nunnari G, Pinzone MR, Gruttadauria S, et al. Hepatic echinococcosis: clinical and therapeutic aspects. *World J Gastroenterol* 2012; 18: 1448-58.
- Harris JD. Rupture of Hydatid Cysts of the Liver into the Biliary Tracts. *Br J Surg* 1965; 52: 210-14.

30. Atahan K, Küpeli H, Deniz M, Gür S, Cökmez A, Tarcan E. Can occult cystobiliary fistulas in hepatic hydatid disease be predicted before surgery? *Int J Med Sci* 2011; 8: 315-20.
31. Aghayev RM. Liver Echinococcosis complicated with Lesions of Bile Ducts in Azerbaijan. *Euroasian J Hepatogastroenterol* 2016; 6: 125-30.
32. Unalp HR, Baydar B, Kamer E, Yilmaz Y, Issever H, Tarcan E. Asymptomatic occult cysto-biliary communication without bile into cavity of the liver hydatid cyst: a pitfall in conservative surgery. *Int J Surg* 2009;7: 387-91.
33. Kenan E, Dervişoğlu A, Polat C, Senyurek G, Yetim İ, Hokelek M. Intrabiliary rupture: an algorithm in the treatment of controversial complication of hepatic hydatidosis. *World J Gastroenterol* 2005; 11: 2472-6.
34. Dziri C, Paquet JC, Hay JM, et al. Omentoplasty in the prevention of deep abdominal complications after surgery for hydatid disease of the liver: a multicenter, prospective, randomized trial. *J Am Coll Surg* 1999; 188: 281-9.
35. Bedirli A, Sakrak O, Sozuer EM, Kerek M, Ince O. Surgical management of spontaneous intrabiliary rupture of hydatid liver cysts. *Surg Today*. 2002; 32: 594-7.
36. Aydın U, Yazıcı P, Onen Z, et al. The optimal treatment of hydatid cyst of the liver: radical surgery with a significant reduced risk of recurrence. *Turk J Gastroenterol* 2008: 33-9.
37. Zaouche A, Haouet K, Jouini M, El Hachaichi A, Dziri C. Management of liver hydatid cysts with a large biliocystic fistula: multicenter retrospective study. *Tunisian Surgical Association. World J Surg* 2001; 25: 28-39.
38. Kayaalp C, Aydın C, Ölmez A, Işık S, Yılmaz S. Leakage tests reduce the frequency of biliary fistulas following hydatid liver cyst surgery. *Clinics* 2011; 66: 421-4.
39. Ghannouchi M, Rodayna H, Khalifa BM, Nacef K, Boudokhan M. Postoperative morbidity risk factors after conservative surgery of hydatid cyst of the liver: a retrospective study of 151 hydatid cysts of the liver. *BMC Surg* 2022; 22: 120.
40. Akbulut S, Şenol A, Sezgin A, Cakabay B, Dursun M, Satıcı O. Radical vs conservative surgery for hydatid liver cysts: experience from single center. *World J Gastroenterol* 2010; 16: 953-9.
41. Vuitton DA, Azizi A, Richou C, et al. Current interventional strategy for the treatment of hepatic alveolar echinococcosis. *Expert Rev Anti Infect Ther* 2016; 14: 1179-94