

PAPER DETAILS

TITLE: Horizontal bone augmentation using a mixture of cortico-cancellous allograft and bovine bone mineral with a collagen membrane: a retrospective study

AUTHORS: Ugur GÜLSEN

PAGES: 268-272

ORIGINAL PDF URL: <https://dergipark.org.tr/tr/download/article-file/2826106>

Horizontal bone augmentation using a mixture of cortico-cancellous allograft and bovine bone mineral with a collagen membrane: a retrospective study

 Uğur Gülşen

Oral and Maxillofacial Surgery, Department of Oral and Maxillofacial Surgery, Faculty of Dentistry, Bülent Ecevit University, Zonguldak, Turkey

Cite this article as: Gülşen U. Horizontal bone augmentation using a mixture of cortico-cancellous allograft and bovine bone mineral with a collagen membrane: a retrospective study. J Health Sci Med 2023; 6(2): 268-272.

ABSTRACT

Aim: The study aimed to evaluate the clinical outcomes of bone augmentation with a mixture of cortico-cancellous allograft and xenograft with a collagen membrane in horizontal augmentation of knife-edge alveolar crests.

Material and Method: Patients with a ridge thickness of less than 4 mm by preoperative tomography were included in the study. Twelve patients (10 Female, 2 Male) were treated with a mixture of Cortico-Cancellous Allograft and Bovine Bone Mineral with a collagen membrane.

Results: Thirty-nine implants were placed in twelve patients. The initial bone thickness is between 1 and 4 cm (mean: 3 ± 0.89440). Nine months after horizontal augmentation, bone thickness varies between 4.53 and 9.15 cm (mean: 4.62 ± 1.16782). The gained bone thickness varies between 1.27 and 7.72 cm (mean 3.66 ± 1.21041).

Conclusion: Augmentation of alveolar bones knife-edge crestal margins with a mixture of Cortico-Cancellous Allograft and Bovine Bone Mineral with a collagen membrane is simple, successful, and feasible.

Keywords: Alveolar bone grafting, bone regeneration, bone substitutes, guided tissue regeneration

INTRODUCTION

Dental implant treatment in atrophic jaws is becoming more prevalent. Periodontal disease, trauma, and bone resorption cause bone insufficiency in the alveolar crest. This insufficient bone causes aesthetic or functional problems; therefore, bone augmentation is recommended (1).

Autogenous bone is the gold standard in bone augmentation due to its osteogenic and osteoinductive properties (2). Although autogenous bone (AB) is the gold standard, the problem in the donor area and the limited amount of bone collection are the disadvantages of the technique. As an alternative to autogenous bones, bone grafts such as alloplasts, xenografts and allografts have been used successfully in alveolar bone augmentation (3,4). Xenografts are preferred in bone regeneration because they preserve tissue volume with their osteoconductive properties and have a slow resorption rate (5,6).

One of the most used techniques in alveolar augmentation is mixing xenograft and autogenous bone. The high biological features of autogenous bone and the slow

resorption feature of xenograft are utilized with this technique (7,8). In Several clinical studies, bone defects were treated with a ratio of 1:1 xenograft and autogenous bone chips. It shows successful results both clinically and histologically (9). The disadvantage of the technique is the need for autogenous grafts. It causes prolongation of the operation time and the occurrence of postoperative complaints in the donor area.

Another possibility is using a mixture of allograft, an osteoinductive material, with xenograft (10). There are few publications about the usage of allograft and xenograft combinations in implantology (11,12).

The study aimed to evaluate the clinical outcomes of bone augmentation with a mixture of allograft and xenograft.

MATERIAL AND METHOD

This study was conducted with the data obtained from the files of patients who underwent horizontal bone augmentation with a mixture of allograft and xenograft, and collagen membrane. The study was carried out with

the permission of Zonguldak Bülent Ecevit University Faculty of Medicine Non-interventional Clinical Researches Ethics Committee (Date: 26/01/2022. Decision No: 2022/02-22). All procedures were performed in accordance with ethical rules and the principles of the Declaration of Helsinki.

This study includes the patient group who required horizontal bone augmentation for dental implant placement. It includes patients with knife edge alveolar bone (Cawood-Howell Class IV) who applied for dental implant treatment at the Department of Oral and Maxillofacial Surgery of the Faculty of Dentistry of Bülent Ecevit University between 2018-2021. Patients with a ridge thickness of less than 4 mm by preoperative cone beam computed tomography (CBCT) were included in the study (**Figure 1**). Patients who did not smoke, had no systemic disease, and had good periodontal health were included in the study.

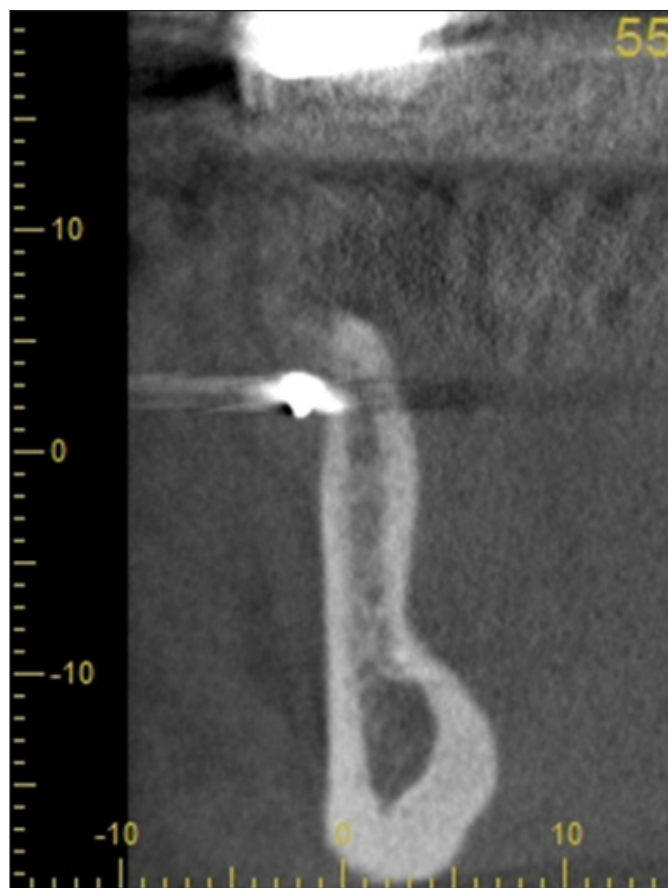


Figure 1. Preoperative CBCT image

Under local anesthesia, a horizontal incision was first made from the crest. In cases with a defect in the palatal aspect of the maxilla, a vestibular shifting incision was performed. Afterward, mesial and distal relaxing incisions were made. After flap dissection, a periosteal relaxing incision was made to stretch the flap. In the mandible, in addition to the buccal relaxing incision, the flap in the lingual region was dissected from the mylohyoid muscle with the help of a periosteal elevator, and the

lingual flap was relieved. To adhere the graft particles and ensure easy manipulation, blood was taken from the patient with an additive-free plastic vacuum type 10 ml tube and centrifuged at 800rpm for 3 minutes in the Process for PRF centrifuge device. Injectable platelet-rich fibrin (iPRF) was obtained. For augmentation, xenograft (Nobel Biocare Creos, Chungcheongbuk-do, Korea) and cortico-cancellous freeze-dried bone allograft (Botiss Maxxgraft, Zossen/Germany) were mixed with injectable platelet-rich fibrin (iPRF) at a ratio of 1:1 and applied on the alveolar crest. A long-lasting membrane (Nobel Biocare Xeno Project, Herzogenrath, Germany) was used over the graft mixture. The membrane is fixed with titanium fixation pins. The flap was closed with 5.0 and 6.0 polyamide sutures without tension. Two weeks after the operation, the sutures were removed.

Antibacterial treatment was started in all patients 24 hours before the operation, including amoxicillin-clavulanate 1gr twice daily (7 days) or azithromycin 500mg once daily (3 days). Diclofenac potassium-containing analgesic and Chlorhexidine gluconate mouthwash were prescribed three times a day.

Nine months after augmentation, CBCT was retaken from the patients, and the newly formed bone thickness was evaluated (**Figure 2**). Implants were placed nine months after augmentation (**Figure 3**).

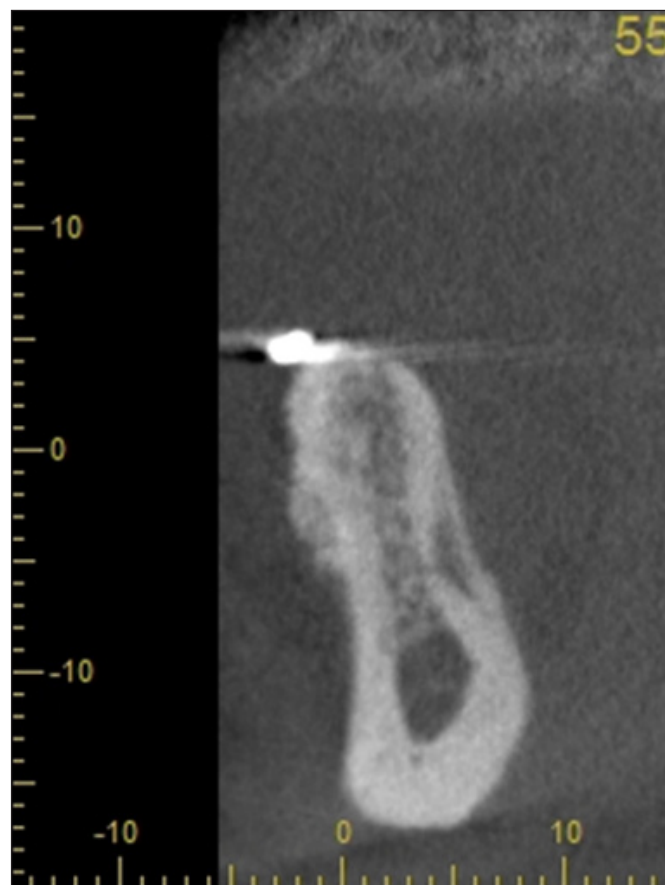


Figure 2. CBCT image of augmentation site nine months after augmentation.

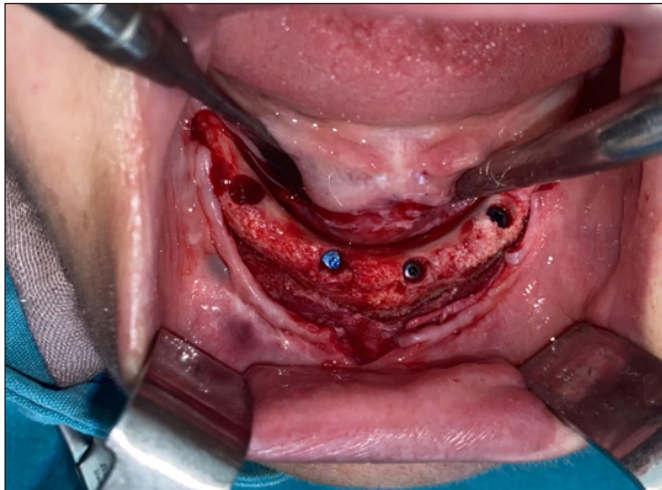


Figure 3. Intraoral view of augmented bone during implant placement.

Statistical analysis was done with SPSS 23.0 for Windows (IBM, Chicago, USA) software. For all the analyzed data, the mean values, standard deviation values for each group were calculated. Normality tests showed a different distribution than normal and Wilcoxon test was used to compare study groups. P values < 0.05 were considered sufficient to indicate statistical significance.

RESULTS

All patients recovered without problems after bone grafting, and complications such as post-op infection and membrane exposure were not observed. Thirty-nine implants with SLA surface TiPurePluss (Bego Semados RSX, BEGO Bremen, Germany) were placed in 12 patients (10 Female, 2 Male with a mean age of 50.9) nine months after augmentation (**Figure 3**). Implant placement sites are shown in **Table 2**. The healing cap was placed four months after the implants had been replaced. There was no implant loss during the healing phase. There was no loss of implant after prosthetic treatment. The initial bone thickness is between 1 and 4 cm (mean: 2.6395 ± 0.89440). Nine months after horizontal augmentation, bone thickness varies between 4.53 and 9.15 cm (mean: 6.3997 ± 1.16782). The gained bone thickness varies between 1.27 and 7.72 cm (mean 3.7574 ± 1.21041). The Post-op thickness median value was significantly higher than the pre-op value ($p < 0.05$) (**Table 3**). When the bone changes in the maxilla and mandible are compared, the average residual bone thickness is 2.69 ± 0.89 mm in the mandible and 2.60 ± 0.92 mm in the maxilla. The newly formed bone thickness is 3.73 ± 0.36 mm in the

mandible and 3.77 ± 0.21 mm in the maxilla. There were no significant statistical differences in bone width gain between maxillary and mandibular regions ($P = 0.901$).

Table 1. Wilcoxon Signed Rank Test

Augmented Bone With – Initial Bone Width	
Z	-5.442 ^a
P-value	.000

a. Based on negative ranks.

Table 2. Implant sites

Implant Site	n:39
Incisors	8 (20.5%)
Canines	5 (12.8%)
Premolars	22 (56.5%)
Molars	4 (10.2%)
Lower jaw	22 (56.4%)
Upper jaw	17 (43.6%)

DISCUSSION

Horizontal augmentation with AB and deproteinized bovine bone mineral (DBBM) mixture is one of the most popular techniques. Mordenfeld et al. (13) evaluated the effects of different ratios of DBBM and autogenous bone mixtures on graft healing and volumetric changes in horizontal bone augmentation. They found the gained crest width as 3.5 (± 1.3) mm in the 60:40 group and 2.9 (± 1.3) mm in the 90:10 group. It was reported that a thicker crest was obtained in the 60:40 group, but there was no histological difference between the two groups. According to the systematic review and meta-analysis by Elnayef et al. (14), the estimated overall mean horizontal bone gain at the time of regeneration was 3.61 ± 0.27 mm for guided bone regeneration (GBR). The present study demonstrated an average bone gain of 3.75 ± 1.2 mm.

Hashemipoor et al. (15) evaluated the histological and radiological effects of a cortico-cancellous freeze-dried bone allograft (FDBA) with and without autogenous bone in horizontal ridge augmentation. They found that including autogenous bone in the allograft particles does not significantly increase the quality and quantity of regenerated bone. Song et al. (16) compared the outcomes after wide horizontal guided bone regeneration using DBBM with or without autogenous bone chips in a canine model of chronic horizontal alveolar ridge defect. The author stated that including autogenous bone chips to DBBM for horizontal ridge augmentation

Table 3. Analyses of patients' age and bone thickness

	Patients age	Initial bone width	Augmented bone width	Gained bone width
Mean(SD)	50.91 (15.06)	2.6395 (0.89440)	6.3997 (1.16782)	3.7574 (1.21041)
Median	54.00	2.6700	6.1100	3.6600
Interquantile range	26.25	1.47	1.40	1.54
Range	48.00	3.00	4.62	6.45

has no advantage. Kloss et al. (17) evaluated the three-dimensional volumetric changes in autogenous and allogenic onlay graft augmentation in single tooth defects. They found that the rate of graft remodeling volume of freeze-dried cancellous bone blocks was similar to autogenous bone. Therefore, we preferred allograft with osteoinductive properties instead of autogenous bone. We thought to shorten the operation time and have a more comfortable post-operative period by not using an autogenous bone graft.

Wang et al. (18) defined major biological principles "PASS" for predictable bone regeneration; Primary wound closure, angiogenesis, space creation/maintenance, and stability. Initial clot stabilization and wound stabilization are essential in guided bone regeneration. Once the bone grafts are mixed with i-PRF, their consistency transforms into a plastic form within 3-4 minutes, making it easier to apply to the defect area and providing stability to the graft (19). To stabilize the bone grafts, i-PRF was used, and titanium fixation pins were used to prevent membrane micro-movements for optimum wound stability.

Although many studies are showing favourable effects of i-PRF on early bone healing, its effects on long-term bone healing are controversial (20,21). Mu et al. (21) evaluated the effects of i-PRF on bone in sinus augmentations by applying DBBM alone and DBBM combined with i-PRF to rabbit sinuses. They concluded that despite increased vascular formation and bone remodelling in the early stages of healing using i-PRF, bone volume did not change significantly in the long term. İrdem et al. (22) evaluated the effectiveness of DBBM combined with i-PRF on new bone formation in patients with bilateral maxillary sinus atrophy requiring maxillary sinus augmentation. The combination of DBBM with i-PRF did not significantly affect new bone formation. Since xenograft healing takes a long time, we think that the effects of i-PRF on the bone formation are limited, but we think that i-PRF has a great effect on the preservation of bone volume by fixing the graft particles and preventing the movement of the particles.

Primary wound closure and soft tissue primary wound healing seem to be key factors for successful outcomes. Soft tissue dehiscence in the early period after augmentation surgery may have a negative effect on the new bone formation process. To minimize the risk of soft tissue dehiscence, flap elongation and passivation must have extremely low residual tension at the flap suture line. While the lingual flap can be easily stretched in the mandible, the palatal flap cannot be stretched in the maxilla due to its dense fibrous structure (23). In our study, mid-crestal incision was used for augmentation in the mandible. Mid-crestal incision was preferred if the

defect was in the buccal side of the maxilla. If the defect was on the palatal side we preferred a vestibular shifted flap for preventing soft tissue dehiscence.

In guided bone regeneration, resorbable (human, porcine, and bovine pericardium membranes, human amnion, chorion tissue, human acellular freeze-dried dermal matrix) and non-resorbable membranes (titanium mesh, titanium-reinforced polytetrafluoroethylene) are used as barrier membranes. Non-resorbable membranes are more rigid than non-resorbable membranes. They provide less micro-movement of the graft and have better space-maintaining properties. Some disadvantages include increased exposure risk, the necessary second surgery to remove it, and the technique-sensitive approach (24). Because of these disadvantages, we preferred resorbable membranes in our study. The collagen membrane showed good soft tissue compatibility, and no membrane exposures occurred in our research.

The limitations of the study are the non-homogeneous gender distribution, the absence of a histological evaluation, and the lack of long-term follow-up of the implants. Future studies should include homogeneous sex distribution, histological assessment, and long-term follow-up.

CONCLUSION

Allograft and DBBM combination with a collagen membrane can be safely and effectively used for horizontal augmentation of knife-edge ridges. Further studies will be necessary to confirm these results.

ETHICAL DECLARATIONS

Ethics Committee Approval: The study was carried out with the permission of Zonguldak Bülent Ecevit University Faculty of Medicine Non-interventional Clinical Researches Ethics Committee (Date: 26/01/2022. Decision No: 2022/02-22).

Informed Consent: Because the study was designed retrospectively, no written informed consent form was obtained from patients.

Referee Evaluation Process: Externally peer-reviewed.

Conflict of Interest Statement: The authors have no conflicts of interest to declare.

Financial Disclosure: The authors declared that this study has received no financial support.

Author Contributions: All of the authors declare that they have all participated in the design, execution, and analysis of the paper and that they have approved the final version.

REFERENCES

- Chiapasco M, Casentini P, Zaniboni M. Bone augmentation procedures in implant dentistry. *Int J Oral Maxillofac Implants* 2009; 24: 237-59.
- Buser D, Dula K, Hess D, et al. Localized ridge augmentation with autografts and barrier membranes. *Periodontology* 2000; 19: 151-63.
- Sheikh Z, Najeeb S, Khurshid Z, et al. Biodegradable materials for bone repair and tissue engineering applications. *Materials* 2015; 8: 5744-94.
- Khojasteh A, Behnia H, Soleymani Shayesteh Y, et al. Localized bone augmentation with cortical bone blocks tented over different particulate bone substitutes: a retrospective study. *Int J Oral Maxillofac Implants* 2012; 27: 6.
- Cardaropoli G, Araújo M, Hayacibara R, et al. Healing of extraction sockets and surgically produced-augmented and non-augmented-defects in the alveolar ridge. An experimental study in the dog. *J Clin Periodontol* 2005; 32: 435-40.
- Carmagnola D, Adriaens P, Berglundh T. Healing of human extraction sockets filled with Bio-Oss®. *Clin Oral Implants Res* 2003;14: 137-43.
- Jensen SS, Broggini N, Hjørtting-Hansen E, et al. Bone healing and graft resorption of autograft, anorganic bovine bone and β -tricalcium phosphate. A histologic and histomorphometric study in the mandibles of minipigs. *Clin Oral Implants Res* 2006; 17: 237-43.
- Lee IK, Lim HC, Lee JS, et al. Layered approach with autogenous bone and bone substitute for ridge augmentation on implant dehiscence defects in dogs. *Clin Oral Implants Res* 2016; 27: 622-8.
- Urban IA, Nagursky H, Lozada JL. Horizontal ridge augmentation with a resorbable membrane and particulated autogenous bone with or without anorganic bovine bone-derived mineral: a prospective case series in 22 patients. *Int J Oral Maxillofac Implants* 2011; 26: 2.
- Serrano CA, Castellanos P, Botticelli D. Use of combination of allografts and xenografts for alveolar ridge preservation procedures: a clinical and histological case series. *Implant Dent* 2018; 27: 467-73.
- Galindo-Moreno P, Moreno-Riestra I, Ávila G, et al. Histomorphometric comparison of maxillary pristine bone and composite bone graft biopsies obtained after sinus augmentation. *Clin Oral Implants Res* 2010; 21: 122-8.
- Poulias E, Greenwell H, Hill M, et al. Ridge preservation comparing socket allograft alone to socket allograft plus facial overlay xenograft: a clinical and histologic study in humans. *J Periodontol* 2013; 84: 1567-75.
- Mordenfeld A, Johansson CB, Albrektsson T, et al. A randomized and controlled clinical trial of two different compositions of deproteinized bovine bone and autogenous bone used for lateral ridge augmentation. *Clin Oral Implants Res* 2014; 25: 310-20.
- Elnayef B, Porta C, Del Amo FS-L, et al. The fate of lateral ridge augmentation: a systematic review and meta-analysis. *Int J Oral Maxillofac Implants* 2018; 33: 3.
- Hashemipour M, Asghari N, Mohammadi M, et al. Radiological and histological evaluation of horizontal ridge augmentation using corticocancellous freeze-dried bone allograft with and without autogenous bone: a randomized controlled clinical trial. *Clin Implant Dent Related Res* 2020; 22: 582-92.
- Song YW, Jung HJ, An YZ, et al. Addition of autogenous bone chips to deproteinized bovine bone mineral does not have additional benefit in lateral ridge augmentation—A preclinical in vivo experimental study. *Clin Oral Implants Res* 2021; 32: 1105-14.
- Kloss FR, Offermanns V, Kloss-Brandstätter A. Comparison of allogeneic and autogenous bone grafts for augmentation of alveolar ridge defects—A 12-month retrospective radiographic evaluation. *Clin Oral Implants Res* 2018; 29: 1163-75.
- Wang H-L, Boyapati L. “PASS” principles for predictable bone regeneration. *Implant Dent* 2006;15: 8-17.
- Shah R, Gowda TM, Thomas R, et al. Biological activation of bone grafts using injectable platelet-rich fibrin. *J Prosth Dent* 2019; 121: 391-3.
- Yuan S, Li Q, Chen K, Mu Z et al. Ridge preservation applying a novel hydrogel for early angiogenesis and osteogenesis evaluation: an experimental study in canine. *J Biol Eng* 2021;15:19.
- Mu Z, Chen K, Yuan S, et al. Gelatin nanoparticleinjectable platelet-rich fibrin double network hydrogels with local adaptability and bioactivity for enhanced osteogenesis. *Adv Healthc Mater* 2020;9:e1901469.
- İrdem HO, Dolanmaz D, Esen A, et al. Evaluation of the effectiveness of liquid platelet-rich fibrin and deproteinized bovine bone mineral mixture on newly formed bone in maxillary sinus augmentation: a split-mouth, histomorphometric study. *Niger J Clin Pract* 2021; 24: 1366-72.
- Luca De S, Tunkel MJ, Fincato MA, et. al. The vestibular shifted flap design for vertical bone augmentation in the maxilla: case report and technical notes. *Int J Periodontics Restorative Dent* 2021; 41: 367-73.
- Soldatos NK, Stylianou P, Koidou VP, et al. Limitations and options using resorbable versus nonresorbable membranes for successful guided bone regeneration. *Quintessence International* 2017; 48: 2.