

PAPER DETAILS

TITLE: The relationship between thoracic CT findings and C-reactive protein and ferritin levels in COVID-19 patients

AUTHORS: Semih SAGLIK,Necip NAS,Bilal ALTUNISIK

PAGES: 662-666

ORIGINAL PDF URL: <https://dergipark.org.tr/tr/download/article-file/2982549>

The relationship between thoracic CT findings and C-reactive protein and ferritin levels in COVID-19 patients

✉ Semih Sağlık¹, ✉ Necip Nas², ✉ Bilal Altunışık³

¹Department of Radiology, Faculty of Medicine, Siirt University, Siirt, Turkey

²Department of Internal Medicine, Faculty of Medicine, Siirt University, Siirt, Turkey

³Department of Internal Medicine, Private Siirt Hayat Hospital, Siirt, Turkey

Cite this article as: Sağlık S, Nas N, Altunışık B. The relationship between thoracic CT findings and C-reactive protein and ferritin levels in COVID-19 patients. J Health Sci Med 2023; 6(3): 662-666.

Received: 01.03.2023

Accepted: 21.05.2023

Published: 31.05.2023

ABSTRACT

Aim: In this study, we aimed to establish the relationship between thoracic computed tomography (CT) findings at initial presentation and CRP and ferritin levels in 232 patients diagnosed with COVID-19.

Material and Method: 232 patients who were diagnosed with COVID-19 and underwent a thoracic CT examination at our hospital between Apr 2020 and Aug 2021 were enrolled in this study. The study group was selected from among individuals aged 18-45 years without any chronic diseases and comorbidities. The patients' complaints, RT-PCR test results and blood biochemistry values from the medical records system, and CT imaging from the PACS system were reviewed retrospectively. Parenchymal lesions, ground-glass area, consolidation and combination of ground-glass area and consolidation observed on thoracic CT were considered typical findings. Blood samples were analyzed in the laboratory using standard methods. Routine blood tests were performed to measure serum C-reactive protein and ferritin levels.

Results: Out of the 232 patients infected with COVID-19, 118 were female and 114 were male. While the mean age of all patients was 34.9, the mean ages of men and women were 34.9 and 35.2, respectively. No significant differences were observed between the ages of patients with and without lung involvement (32.9, 37.9, $p=0.903$, respectively). CT scan showed typical parenchymal findings in 140 patients out of whom 65 were male and 75 were female. With regard to the morphologic features observed on CT, ground-glass density was the most common (74 patients), followed by a combination of ground-glass density and consolidation (34 patients) and finally consolidation (32 patients). In statistical analysis, no significant differences were found in CRP values between patients with and without lung involvement, whereas a significant difference was noted in ferritin values ($p=0.196$ and $p<0.001$, respectively).

Conclusion: We examined the relationship between serum CRP and ferritin levels and lung involvement and established that there is a strong correlation between serum ferritin levels and lung involvement. Considering the radiation exposure caused by CT scans as well as the cost of the procedure, we are convinced that serum ferritin levels may help clinicians in terms of early diagnosis, especially in patients with suspected lung involvement.

Keywords: Thoracic CT, COVID-19, ferritin, ground glass areas, consolidation

INTRODUCTION

Coronavirus disease-19 (COVID-19) is an infectious disease primarily involving the respiratory system that has first emerged in Wuhan, China (1). Following droplet transmission from person to person, a person can become infected via the contact of the virus with the mucosa. The most important clinical findings include infection symptoms such as fever, cough and myalgia (2). The disease, which is asymptomatic for the most part, may result in viral pneumonia, sepsis and even death (3,4). COVID-19 is diagnosed by direct detection of viral genomes in RT-PCR in upper respiratory tract samples. Although RT-PCR is considered as the best technique in diagnosing the disease, radiologic imaging started to be

used more frequently due to false negative results and prolonged test result process brought about the former. In particular, CT with a sensitivity of up to 98% can help diagnose the disease on the basis of some parenchymal findings in the early stage even in asymptomatic patients (5,6). However, CT should not be used as a screening method due to ionizing radiation (7).

Typical findings such as peripherally located ground-glass areas, consolidation, reticular pattern, septal thickening and nodules as well as atypical findings such as lymphadenopathy, pleural and pericardial effusion in the lung parenchyma may be observed during thoracic CT examination (8,9). Although COVID-19 often remains

Corresponding Author: Semih SAĞLIK, drsmhsglk@gmail.com



This work is licensed under a Creative Commons Attribution 4.0 International License.

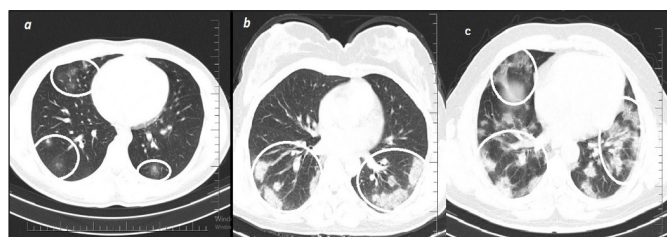
localized and progresses only as a respiratory tract infection, it can sometimes transform into a widespread systemic form involving immunological and inflammatory processes (10). Several biomarkers are required to identify low, intermediate, and high-risk groups in diagnosed patients. Biomarkers measured in laboratory settings are helpful for prognosis and the prevention of serious complications. Studies have shown that elevated serum ferritin, CRP, lactate dehydrogenase, d-dimer, prothrombin time (PT) and IL-6 levels increase the risk of morbidity and mortality (9,11,12).

This article aims to determine the relationship between ferritin and CRP (C-reactive protein) values in COVID-19 patients with lung involvement by using thoracic computed tomography (CT) findings.

MATERIAL AND METHOD

232 patients who were diagnosed with COVID-19 and underwent a thoracic CT examination at our hospital between Apr 2020 and Aug 2021 were enrolled in this study. The study group was selected from among individuals aged 18-45 years without any chronic diseases and comorbidities. The patients' complaints, RT-PCR test results and blood biochemistry values from the medical records system and CT image from the PACS system were retrospectively reviewed. Patients with a history of drug use and active drug use were excluded from the study.

Thoracic CT images of all patients diagnosed with COVID-19 on the basis of clinical examination, laboratory tests and RT-PCR test results were analyzed. All thoracic CT scans were performed in accordance with the appropriate thoracic protocol with a 16-slice CT device (Siemens Scope 16) in the form of axial slices with a thickness of 3 mm and without contrast enhancement. Thoracic CT images were analyzed and recorded at the workstation along with demographic characteristics such as age and gender. Parenchymal lesions, ground-glass area, consolidation and combination of ground-glass area and consolidation observed on thoracic CT were considered typical findings (**Picture**). Patients with atypical findings such as pleural effusion, septal thickening, air bronchogram and mediastinal LAP without any concomitant typical findings were excluded.



Picture. Typical morphologic findings on CT thoracic imaging in patients diagnosed with COVID-19 are shown with a circle; a) ground glass densities b) consolidation c) combination of ground glass densities and consolidation

Blood samples were analyzed in the laboratory using standard methods. Routine blood tests were performed to measure serum CRP and ferritin levels.

Statistical Analysis

SPSS 18.0 software was used for data analysis (Statistical Package for the Social Sciences, Chicago, IL). Comparison of constant variables among independent groups was carried out by using Student's t-test and Mann-Whitney-U test. Categorical values were compared with the Chi-square test. The relationship of categorical variables with each other was examined with the Pearson's correlation coefficient. The level of significance for statistical results was considered $p < 0.05$.

Moreover, the Receiver-operating-characteristic (ROC) curve analysis test was used to establish the diagnostic value of ferritin. The area under the curve (AUC), cut-off, sensitivity and specificity values were established for predicting different models.

RESULTS

Out of the 232 patients diagnosed with COVID-19, 118 were female and 114 were male. While the mean age of all patients was 34.9, the mean ages of men and women were 34.9 and 35.2, respectively. No significant differences were observed between the ages of patients with and without lung involvement (32.9, 37.9, $p = 0.903$, respectively). CT scan showed typical parenchymal findings in 140 patients out of whom 65 were male and 75 were female (**Table**). With regard to the morphologic features observed on CT, ground-glass density was the most common (74 patients), followed by a combination of ground-glass density and consolidation (34 patients) and finally consolidation (32 patients).

Table. Distribution of general characteristics of patients diagnosed with COVID-19

	BT(-)	BT(+)	All patients
No. of patients	92	140	232
Male	49	65	114
Female	43	75	118
Age*	37.9	32.9	34.9
Male	32.4	36.4	34.7
Female	33.5	36.1	35.2
Ferritin ml/ng *	85.7	197.9	153.4
Male	84.2	220.1	161.7
Female	87.3	178.7	145.4
CRP mg/L *	22.7	29.7	26.5
Male	25.1	33.3	29.8
Female	20.1	26.5	24.1

Note: * = mean value

The mean CRP and ferritin values were 26.5 mg/L and 153.4 ml/ng, respectively, in all patients, and 29.7 mg/L and 197.9 ml/ng in patients with lung involvement and 22.7 mg/L and 85.7 ml/ng in patients without lung

involvement. Pearson correlation analysis revealed a significant and positive correlation between CRP and ferritin, $r = .160$, $p < .005$ (Figure 1).

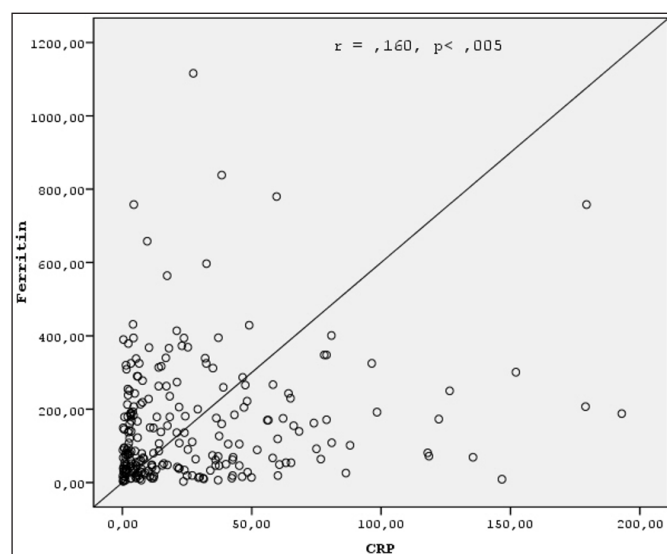


Figure 1. Correlation between serum ferritin and CRP values in COVID-19 patients.

Patients with lung involvement were divided into 3 groups on the basis of CT findings. Group 1 included patients with only ground glass areas while group 2 included patients with only consolidation and group 3 included patients with both ground glass areas and consolidation. In statistical analysis, no significant differences were found in CRP values between patients with and without lung involvement, whereas a significant difference was noted in ferritin values ($p=0.196$ and $p<0.001$, respectively) (Figure 2). There were no significant individual differences between CRP and ferritin values in the patient groups with involvement (CRP; group 1-2 $p=.324$, group 1-3 $p=.933$, group 2-3 $p=.420$ ferritin; group 1-2 $p=.174$, group 1-3 $p=.785$, group 2-3 $p=.332$).

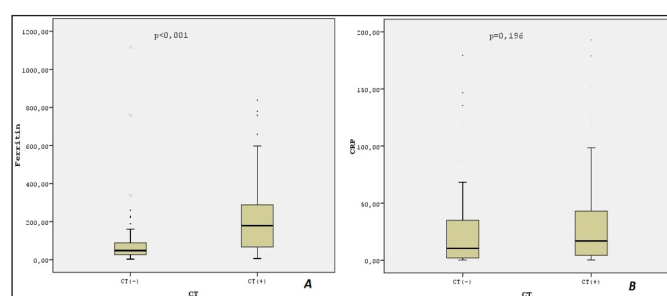


Figure 2. Box plots A and B show the relationship between ferritin and CRP serum values and lung involvement on thoracic CT in COVID-19 patients. The horizontal lines inside each box represent the mean values while the bottom and top rows of each box represent the minimum and maximum values respectively.

In the Receiver operating characteristics (ROC) curve analysis test of ferritin serum value, the AUC value was 0.767 at 95% confidence interval and thus considered to be statistically significant, $p<0.001$ (Figure 3). We established the optimal diagnostic accuracy at selected values for the best odds ratio.

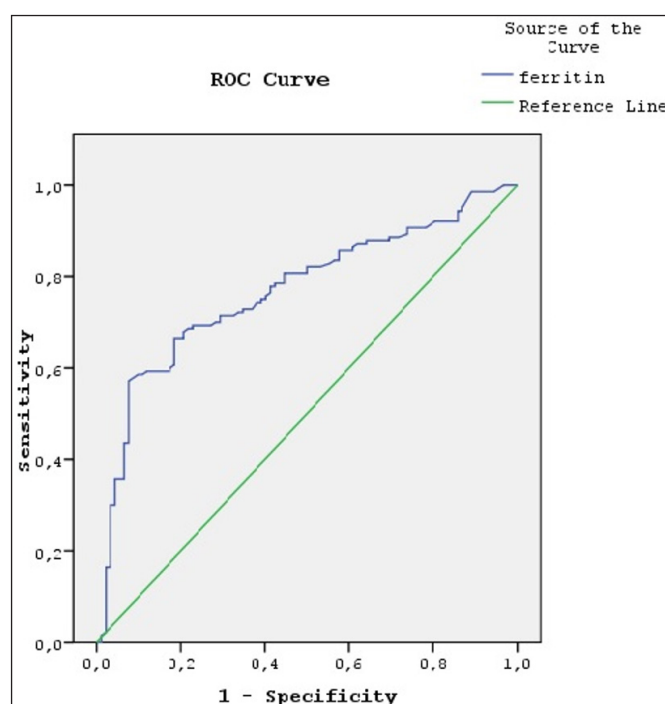


Figure 3. Receiver operating characteristics (ROC) curve analysis of serum ferritin value in the diagnosis of COVID-19.

DISCUSSION

COVID-19 is a usually asymptomatic viral infection that is transmitted primarily through the respiratory system. It may lead to organ damage or even mortality in case of lung involvement. Although RT-PCR test is the best diagnostic method, radiologic imaging is required in some cases as the former is time-consuming, and has low availability as well as low sensitivity in the early stage (13,14). Thoracic CT is one of the first preferred imaging techniques due to its ease of accessibility and high sensitivity in the diagnosis of COVID-19 patients. In some studies, thoracic CT is found to have a sensitivity of 98% in the early stages of the diseases (7). The most common CT finding of COVID-19 pneumonia is ground-glass areas with a mostly bilateral and posterior localization, although unilateral involvement may sometimes be observed (14-16). Consolidation, which is less common, can be present either alone or in combination with a ground-glass area.

Serum ferritin and CRP levels increase in case of excessive inflammation due to infection. Although ferritin reflects normal serum iron levels, the levels of circulating ferritin increase during viral infections (17,18). It was reported in studies that C-reactive protein returns to normal earlier than ferritin in COVID-19 patients, and that the use of CRP in disease follow-up is therefore limited (17,19).

In our study, we examined the relationship between serum CRP and ferritin levels and thoracic CT parenchymal involvement in patients with a diagnosis that was

confirmed clinically and by PCR testing. Thoracic CT examination revealed no evidence of disease in the lung parenchyma in 92 (39.7%) patients, while parenchymal involvement was observed in 140 (60.3%) patients. With regard to the morphologic features of the parenchyma in patients with lung involvement, 74 patients had only ground-glass areas, 32 patients had only consolidation and 34 patients had both ground-glass areas and consolidation. In this study, the most common finding that was consistent with the literature was ground-glass areas (20-23).

It was reported in some studies that COVID-19 patients with high ferritin levels stayed longer in intensive care, that lung involvement was more severe and the mortality rate was higher in these patients (9,19,24,25). Therefore, identifying and treating these patients with a high mortality risk is important for survival. It was suggested in a study that the increase in ferritin serum levels is directly proportional to the severity of COVID-19 (11). Considering that lung involvement is one of the important complications of the disease, serum ferritin values were higher in the patient group with involvement than in the patient group without involvement and there was a statistically significant difference in our study. However, we found no significant difference between the patient groups with involvement at morphologically different periods. Furthermore, our study also demonstrates that ferritin may have diagnostic power with a sensitivity of 72.46% and specificity of 64.2% when the cut-off value of ferritin is considered to be 71.5 ml/ng to differentiate patients with positive CT findings.

It was reported in some studies that serum CRP values increase in the presence or increased severity of pulmonary involvement (9, 26,27). However, we found in our study that there was no statistically significant difference in CRP serum values between patients with and without CT findings. On the other hand, there was a significant and positive, albeit weak, relation between the ferritin and CRP serum according to the result of the Pearson correlation analysis.

CONCLUSION

Laboratory data are crucial in establishing the diagnosis, treatment, and prognosis in COVID-19 patients. Biomarkers such as serum CRP, ferritin, D-dimer, troponin, prothrombin time (PT) and IL-6 are most commonly used to identify these patients. In addition to these markers, radiologic imaging is required due to the primary lung involvement caused by the disease and CT is most commonly preferred thanks to its high sensitivity. In this study, we examined the relationship between serum CRP and ferritin levels and lung involvement in COVID-19 patients and established that there is a

strong correlation between serum ferritin levels and lung involvement. Considering the radiation exposure caused by CT scans as well as the cost of the procedure, we are convinced that serum ferritin levels may help clinicians in terms of early diagnosis, especially in patients with suspected lung involvement. Nonetheless, more research is needed to say that there is a definite relationship. In addition, to the best of our knowledge, this is the first study to evaluate the diagnostic capability of ferritin in detecting COVID-19 pneumonia.

ETHICAL DECLARATIONS

Ethics Committee Approval: The study was carried out with the permission of Siirt University Non-invasive Ethics Committee (Date: 05.01.2023, Decision No: 64349).

Informed Consent: All patients signed the free and informed consent form.

Referee Evaluation Process: Externally peer reviewed.

Conflict of Interest Statement: The authors have no conflicts of interest to declare.

Financial Disclosure: The authors declared that this study has received no financial support.

Author Contributions: All the authors declare that they have all participated in the design, execution, and analysis of the paper, and that they have approved the final version.

REFERENCES

1. Işık Ş. Systemic inflammation indices predict mortality in patients with COVID-19. *J Health Sci Med* 2022; 5(4): 1086-1091.
2. Çolak S, Tekgöz E, Çınar M, et al. Efficacy of tocilizumab in severe COVID-19: a retrospective study. *J Health Sci Med* 2022; 5: 592-9.
3. Zhu N, Zhang D, Wang W, et al. A novel coronavirus from patients with pneumonia in China, 2019. *N Engl J Med* 2020; 382: 727-33.
4. Öztürk Durmaz Ş, Sümer Coşkun A, Yalçın AN. Clinical and prognostic evaluation of patients admitted to the COVID-19 pandemic unit of the emergency department. *J Health Sci Med* 2021; 4: 835-9.
5. Fang Y, Zhang H, Xe J, et al. Sensitivity of chest CT for COVID-19: comparison to RT-PCR. *Radiology* 2020; 200432.
6. İnanc IH, Bursa N, Gültepe A, Sabanoğlu C. The impact of COVID-19 on rural population: A retrospective study. *J Health Sci Med* 2021; 4: 722-7.
7. Ceylan N, Savaş R. COVID-19'un radyolojik bulguları. COVID-19 ve Akciğer: Göğüs Hastalıkları Uzmanlarının Bilmesi Gerekenler' Başlıklı Ek Sayı. *Eurasian J Pulmonol* 2020: 33-44.
8. Nair A, Rodrigues JCL, Hare S, Edey A, et al. A British Society of toracic Imaging statement: considerations in designing local imaging diagnostic algorithms for the COVID-19 pandemic. *Clin Radiol* 2020; 75: 329-334.
9. Sarıcı A, Berber NK, Çağışar Ö, et al. The impact of laboratory features and comorbidities on the prognosis of patients with COVID-19. *J Health Sci Med* 2021;4(2):142-146.
10. Samprathi M, Jayashree M. Biomarkers in COVID-19: an up-to-date review. *Frontiers in Pediatrics* 2021; 8: 607647.

11. Zhou F, Yu T, Du R, et al. Clinical course and risk factors for mortality of adult inpatients with COVID-19 in Wuhan, China: a retrospective cohort study. *Lancet* 2020; 395.10229: 1054-62.
12. Chen CC, Lee IK, Liu JW, Huang SY, Wang L. Utility of C-reactive protein levels for early prediction of dengue severity in adults. *BioMed Res Int* 2015.
13. Huang P, Liu T, Huang L, et al. Use of chest CT in combination with negative RT-PCR assay for the 2019 novel coronavirus but high clinical suspicion. *Radiology* 2020; 295: 22-3.
14. Doğan E, Gürsoy C, Tapan ÖO, Elibol C, Togan T, Demirbilek S. The comparison of chest X-ray and CT visibility according to size and lesion types in the patients with COVID-19. *J Health Sci Med* 2020; 5(4), 1151-1155.
15. Salehi S, Abedi A, Balakrishnan S, Gholamrezanezhad A. Coronavirus disease 2019 (COVID-19): A systematic review of imaging findings in 919 patients. *AJR Am J Roentgenol* 2020; 215: 87-93.
16. Hani C, Trieu NH, Saab I, Dangeard S, Bennani S, Chassagnon G. COVID-19 pneumonia: a review of typical CT findings and differential diagnosis. *Diagnostic Intervent Imag* 2020; 101: 263-68.
17. Li Y, Hu Y, Yu J, Ma T. Retrospective analysis of laboratory testing in 54 patients with severe- or critical-type 2019 novel coronavirus pneumonia. *Laboratory Investigation* 2020; 100: 794-800.
18. Baraboutis IG, Gargalianos P, Aggelonidou E, Adraktas A. Initial real-life experience from a designated COVID-19 Centre in Athens, Greece: a proposed therapeutic algorithm. *SN Compr Clin Med* 2020; 2.6: 689-693.
19. Cheng L, Li H, Li L, et al. Ferritin in the coronavirus disease 2019 (COVID-19): a systematic review and meta-analysis. *J Clin Lab Analysis* 2020; 34.10: e23618.
20. Bernheim A, Mei X, Huang M, et al. Chest CT findings in coronavirus disease-19 (COVID-19): relationship to duration of infection. *Radiology* 2020; 295: 3.
21. Sahin GG, Kurtoglu TI, Sahin A, Ozcaglayan O, Sasani H. Atypical CT findings and clinical correlation of COVID-19 pneumonia. *Namık Kemal Tıp Dergisi* 2020; 8.3: 489-98.
22. Özdemir M, Taydaş O, Öztürk MH. COVID-19 enfeksiyonunda toraks bilgisayarlı tomografi bulguları. *J Biotechnol Strategic Health Res* 2020; 4, 91-6.
23. Sayar M S, Bulut D, Çelik S, et al. The impact and relationship of inflammatory markers and radiologic involvement in the COVID-19 patients. *J Health Sci Med* 2021; 4: 416-21.
24. Qin L, Li X, Shi J, et al. Gendered effects on inflammation reaction and outcome of COVID-19 patients in Wuhan. *J Med Virol* 2020; 92.11: 2684– 2692.
25. Sun L, Shen L, Fan J, et al. Clinical features of patients with coronavirus disease 2019 from a designated hospital in Beijing, China. *J Med Virol* 2020; 395.10223.: 497– 506.
26. Altıntaş DD, Şenol A. Hastaneye yatırılan COVID-19 hastalarında akciğer bilgisayarlı tomografi parankimal bulguları ile C reaktif protein arasındaki ilişki. *Kocaeli Tıp Dergisi* 2021; 10.2, 160-66.
27. Wu J, Wu X, Zeng W, et al. Chest CT findings in patients with coronavirus disease 2019 and its relationship with clinical features. *Investigative Radiol* 2020, 55.5: 257.