

PAPER DETAILS

TITLE: Evaluation of mesiobuccal root canal morphology and interorifice distance in maxillary first molar teeth: a CBCT study on Southeast Anatolian population

AUTHORS: Ibrahim UYSAL,Nevzat KOÇ

PAGES: 763-766

ORIGINAL PDF URL: <https://dergipark.org.tr/tr/download/article-file/3142840>

Evaluation of mesiobuccal root canal morphology and interorifice distance in maxillary first molar teeth: a CBCT study on Southeast Anatolian population

İbrahim Uysal, Nevzat Koç

Department of Endodontics, Faculty of Dentistry, Dicle University, Diyarbakır, Turkey

Cite this article as: Uysal İ, Koç N. Evaluation of mesiobuccal root canal morphology and interorifice distance in maxillary first molar teeth: A CBCT study on Southeast Anatolian population. *J Health Sci Med.* 2023;6(4):763-766.

Received: 15.05.2023

Accepted: 01.07.2023

Published: 30.07.2023

ABSTRACT

Aims: The aim of this study was to evaluate the mesiobuccal root canal morphologies and interorifice distances of maxillary first molars using cone-beam computed tomography (CBCT).

Methods: CBCT images of 477 patients who had undergone CBCT for various reasons were examined and 654 maxillary first molars were included in the study according to the study criteria.

Results: The most common canal configuration observed in mesiobuccal roots was type II ($p < 0.05$). The median interorifice distance was 2.28 mm in roots with type II canal configuration, while it was measured as 2.55 mm in roots with type IV canals, and a significant difference was found depending on the presence of canal in the apical third of the root ($p < 0.001$). The median interorifice distance was found to be 2.58 mm in males and 2.34 mm in females, and a significant difference was detected ($p < 0.001$).

Conclusion: Various canal variations can be observed in the mesiobuccal roots of maxillary first molars, and the length of interorifice distance can predict the canal type. This information can increase the success rate of endodontic treatment.

Keywords: Maxillary first molar, cone-beam computed tomography, MB2, interorifice distance

INTRODUCTION

Root canal treatment depends on the dentist's knowledge of root canal morphology. The presence of an untreated root canal space is strongly related to apical periodontitis as any part of the root canal system that is not properly cleaned carries the risk of harboring microorganisms.¹

Maxillary first molars have the highest clinical failure rate during canal treatment due to the particularly elusive mesiobuccal second Root canal, which is often undetected.² Studies investigating the incidence of the mesiobuccal second (MB2) canal in maxillary molars have reported detection rates ranging from 17.8% to 95.2%.³⁻⁸

The ethnic origin of the population under investigation may have a strong impact on the incidence of canal variations. Clinicians often encounter difficulties in localizing the MB2 canal in maxillary molars due to excessive dentin accumulation at the canal orifice during cavity access opening.⁹ In the presence of undetectable extra canals, root canal treatment cannot be completed properly, leading to failed treatment and persistent pain.¹⁰

Conventional radiography is still commonly used for accurate diagnosis and treatment planning. However, the use of cone-beam computed tomography (CBCT) has enabled clinicians to examine teeth in three dimensions, as periapical radiographs only provide two-dimensional images. In their study evaluating the relationship between canal orifice configuration and MB2 canal morphology in maxillary second molars with fused roots, Keskin et al.¹¹ reported that the distance between orifices was a strong indicator of the presence of the MB2 canal.

The Aim of our study is to examine the incidence and morphology of the MB2 canal in maxillary first molar teeth using CBCT images obtained for general dental examinations.

METHODS

After obtaining approval from the Local Ethics Committee of Dicle University Faculty of Dentistry (Date: 29.09.2021, Decision No: 2021-48), 477 CBCT

Corresponding Author: İbrahim Uysal, ibrahim.uysal@dicle.edu.tr



This work is licensed under a Creative Commons Attribution 4.0 International License.

scans (253 female / 224 male) of patients who met the study criteria were selected from a total of 1271 CBCT scans taken for various reasons (implant planning, trauma, orthodontic treatment planning, etc.) between January 2018 and December 2019 at Dicle University Faculty of Dentistry. A total of 654 (338 female / 316 male) maxillary first molar teeth were analyzed and included in the study. Criteria for teeth not included in the study were (a) excessive crown destruction in the tooth, (b) presence of internal-external resorption in the root canals of the tooth, (c) the tooth having undergone endodontic treatment or having periapical pathology, (d) the tooth being an immature tooth with an open apex, (e) the root canals of the tooth being calcified, (f) the presence of root fracture, (g) the presence of deep restorations, crown-bridge restorations, and dental implants that impair image quality in the examination area and (h) CBCT scans containing artifacts.

In our study, CBCT images obtained with the I-Cat (Imaging Sciences International, Hatfield, PA) CBCT system, which can image the entire upper and lower jaws, were used. The images were obtained at 120 kVp, 5 mA, 9 seconds scanning time, and 0.3 mm voxel size. Measurements and evaluations were performed by two experienced independent researchers.

The three-dimensional images of the upper first molar teeth were examined in three planes (Sagittal, Axial, and Coronal) using I-CAT Vision software (Imaging Sciences International, Hatfield, PA). The presence of the MB2 canal and the canal configuration in the MB root were carefully evaluated in every section from the pulp chamber to the apex in the horizontal (MPR images) plane. The the interorifice distance at the pulp chamber floor level was measured using the distance measurement feature of I-CAT Vision software and recorded (**Figure 1**).

The canals of the mesiobuccal roots evaluated in the scans were classified according to the Vertucci classification (**Figure 2**).

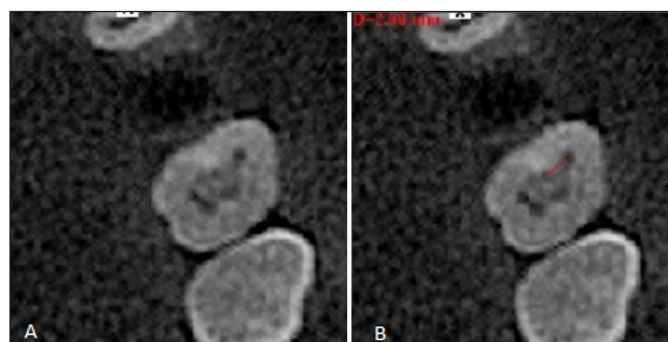


Figure 1. The image of MB2 canal in the axial section and the measurement of the interorifice distance. (A. Pre-measurement image, B. Post-measurement image).

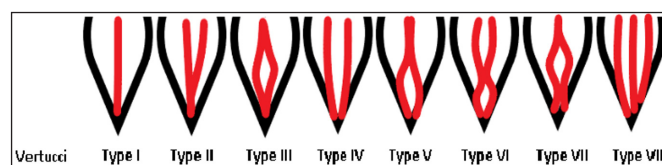


Figure 2. Root canal types according to the Vertucci classification.

Statistical Analysis

The data were analyzed using Rstudio (version 3.6.2 (2019-12-12) – CRAN). Normal distribution suitability was examined with Lilliefors (Kolmogorov-Smirnov) test. Mann Whitney U test was used for comparison of non-normally distributed data between two groups. The analysis results were presented as mean±standard deviation and median (minimum – maximum) for quantitative data, and as frequency and percentage for categorical data. The significance level was set at $p < 0.050$.

RESULTS

A total of 654 (338 female / 316 male) maxillary first molars were analyzed from 477 CBCT images. Of these, it was determined that 108 (57 female / 51 male) had Type-I (16.5%) and one (male) had Type-III (0.1%) canal configuration in their mesiobuccal canals, while the remaining 545 (279 female / 266 male) teeth had MB2 canal configurations with two separate canal orifices in the mesial root, detected as Type-II and Type-IV canal configurations.

Of the 546 teeth with an MB2 canal detected in the mesiobuccal root, 177 had Type-IV (27%) canals that extend to the apical trio, while 369 teeth had Type-II (56.4%) and Type III (0.1%) canal types that end with an isthmus in the middle or apical trio of the mesiobuccal canal.

The median interorifice distance was 2.55 mm for teeth with MB2 canals in the apical trio (Type IV) and 2.28 mm for teeth without MB2 canals (Type II), and the median distance values obtained differed depending on the presence of MB2 canal in the apical trio ($p < 0.001$) (**Table 1**).

When the interorifice distance was evaluated by gender, a statistically significant difference was found between the median distance values of the two genders ($p < 0.001$). The median distance value was 2.34 for females and 2.58 for males (**Table 2**).

When the interorifice distance was evaluated independently of gender, the median distance value was determined as 2.42 and the mean distance value was determined as 2.44 (**Table 3**). Of the scanned teeth, 51.7% were from female patients and 48.3% were from male patients.

Table 1. Comparison of distances according to the presence of MB2 canal in the root apical third

	Present (Tip IV)		Absent (Tip-II)		Test Stats.*	p
	Average±SS	Median (Min.-Maks.)	Average±SS	Median (Min.-Maks.)		
Distance	2,51±0,55	2,55 (1,20-4,50)	2,31±0,54	2,28 (0,95-3,62)	26443,5	<0,001

*Mann Whitney U testi

Table 2. Comparison of interorifice distances by gender.

	Female		Male		Test Stats.*	p
	Average±SS	Median (Min.-Maks.)	Average±SS	Median (Min.-Maks.)		
Distance	2,33±0,54	2,34 (0,95-3,62)	2,56±0,54	2,58 (1,24-4,50)	28378	<0,001

*Mann Whitney U testi

Table 3. Frequency distributions, Vertucci configuration percentages and interorifice distance data

	Frequency (n=654)	Percentage (Total%)
Middle trio		
Canal present	546	83,5 (Type II, III, IV)
Canal absent	108	16,5 (Type I)
Apical trio		
Canal present	177	27 (Type IV)
Canal absent	477	73 (Type I-II-III)
Gender		
Female	338	51,7
Male	316	48,3
	Average±SS	Median (Min.-Maks.)
Interorifice distance	2,44±0,55	2,42 (0,95-4,50)

DISCUSSION

In routine dental practice, visual evaluation, dental operating microscope (DOM), and conservative X-ray are the most commonly used options for detecting the second root canal. The use of CBCT imaging in endodontic diagnosis and treatment planning has enabled the three-dimensional evaluation of root canals before treatment.¹² In this study, the mesial root canal morphologies of the first molars could be examined, and the distance between the mesiobuccal canal and the MB2 canal orifices could be measured clearly.

In our study, the root canal images of 654 maxillary first molars obtained from CBCT scans of 477 patients from the Southeast Anatolian population were examined. The results show that the existence rate of the mesiobuccal second canal in maxillary first molars in this population is 81%. This finding is consistent with the results of various international scientific studies, which show a prevalence between 66% and 87%.¹³⁻¹⁵

Al Mheiri et al.¹⁶ reported in their CBCT studies of maxillary first molar canal morphologies that they most commonly encountered Vertucci Type II (59%) in the mesiobuccal canal, followed by Type I (19.9%), Type IV (15.3%), and Type III (5.7%). Mufadhil et al.¹⁷ reported in a similar study that Type II (25%), Type III (23.1%), and Type I (17.7%) canal configurations were found most frequently. Induja et al.¹⁸ who examined the mesiobuccal canals of maxillary first molars in vitro, detected the

presence of Type II (44%) and Type IV (33.3%) canals most frequently.

The reasons for the different rates and configurations of the MB2 canal in maxillary first molars in different studies are ethnic differences, as well as the structural differences of the CBCT system and software used for the examination, the experience level of the researcher examining the images, and the age range of the patient groups being examined. Kiefner et al.¹⁹ reported in their studies that secondary dentin accumulation in elderly patients can significantly narrow the root canal space and lead to canal calcification. Reis et al.²⁰ reported in their studies of maxillary molars that the prevalence of the MB2 canal decreases with increasing age and the canal progressing towards the apical third. They noted that this may be due to the increased dentin apposition on the root canal walls with advancing age.

Keskin et al.¹¹ reported in their studies that a distance between the mesiobuccal and palatal canal orifices of more than 4 mm is a strong indicator of the presence of the MB2 canal. Zhang et al.²¹ reported in their studies that the ratio of the distance between the mesiobuccal and palatal canal orifices to the distance between the distobuccal and palatal canal orifices has high diagnostic accuracy in predicting the presence of an MB2 canal. Cimilli et al.²² The distance between the mesiobuccal and mesiolingual canal orifices of the mandibular first molars is an important clinical parameter in predicting the formation of Vertucci Type IV canals, and teeth with a distance greater than 3 mm between the orifices tend to have separate canals, as reported by previous studies. Similarly, in our current study, teeth with Vertucci Type IV canal configuration had a greater average distance between the mesiobuccal canal orifices (2.51±0.55 mm) compared to teeth with Vertucci Type II configuration (2.31±0.54 mm).

In a study by Su et al.²³ on maxillary first molars, they found that the distance between the mesiobuccal and MB2 canal orifices was significantly longer in males than in females. Our study also found that the median distance between orifices was 2.58 mm in males and 2.34 mm in females.

CONCLUSION

The incidence of a second mesiobuccal canal in maxillary first molars in the Southeast Anatolian population was found to be 81%. When evaluating the interorifice distance, it was found to be significantly larger in males than females and in Type IV canals compared to Type II canals. Obtaining information about canal morphology through CBCT scans before endodontic treatment can increase the success rate of root canal treatment.

ETHICAL DECLARATIONS

Ethics Committee Approval: The study was carried out with the permission of Dicle University Faculty of Dentistry Clinical Researches Ethics Committee (Date: 29.09.2021, Decision No: 2021-48).

Informed Consent: Because the study was designed retrospectively, no written informed consent form was obtained from patients.

Referee Evaluation Process: Externally peer reviewed.

Conflict of Interest Statement: The authors have no conflicts of interest to declare.

Financial Disclosure: The authors declared that this study has received no financial support.

Author Contributions: All the authors declare that they have all participated in the design, execution, and analysis of the paper, and that they have approved the final version.

REFERENCES

- Karabucak B, Bunes A, Chehoud C, Kohli MR, Setzer F. Prevalence of apical periodontitis in endodontically treated premolars and molars with untreated canal: a cone-beam computed tomography study. *J Endod*. 2016;42:538-541.
- Wolcott J, Ishley D, Kennedy W, Johnson S, Minnich S. A 5 yr clinical investigation of second mesiobuccal canals in endodontically treated and retreated maxillary molars. *J Endod*. 2005;31(4):262-264.
- Kulid, JC, Peters DD. Incidence and configuration of canal systems in the mesiobuccal root of maxillary first and second molars. *J Endod*. 1990;16(7):311-317.
- Weng XL, Yu SB, Zhao SL, et al. Root canal morphology of permanent maxillary teeth in the Han nationality in Chinese Guanzhong area: a new modified root canal staining technique. *J Endod*. 2009;35(5):651-656. doi:10.1016/j.joen.2009.02.010
- Fernandes NA, Herbst D, Postma TC, Bunn BK. The prevalence of second canals in the mesiobuccal root of maxillary molars: A cone beam computed tomography study. *Aust Endod J*. 2019;45(1):46-50.
- Su CC, Huang RY, Wu YC, et al. Detection and location of second mesiobuccal canal in permanent maxillary teeth: A cone-beam computed tomography analysis in a Taiwanese population. *Arch Oral Biol*. 2019;98:108-114. doi:10.1016/j.archoralbio.2018.11.006
- Onn HY, Sikun MSYA, Rahman HADhalival JS. Prevalence of mesiobuccal-2 canals in maxillary first and second molars among the Bruneian population—CBCT analysis. *BDJ Open*. 2022;8(1):32.
- Martins JNR, Marques D, Silva EJNL, Carames J, Mata A, Versiani MA. Second mesiobuccal root canal in maxillary molars—a systematic review and meta-analysis of prevalence studies using cone beam computed tomography. *Arch Oral Biol*. 2020;113:104589.
- Betancourt P, Navarro P, Cantin M, Fuentes R. Cone-beam computed tomography study of prevalence and location of MB2 canal in the mesiobuccal root of the maxillary second molar. *Int J Clin Exp Med*. 2015;8(6):9128.
- Vertucci FJ. Root canal anatomy of the human permanent teeth. *Oral Surg Oral Med Oral Pathol*. 1984;58(5):589-599.
- Keskin, C, Keleş, A, Versiani, MA. Mesiobuccal and palatal interorifice distance may predict the presence of the second mesiobuccal canal in maxillary second molars with fused roots. *J Endod*. 2021;47(4):585-591.
- Aung NM, Myint KK. Diagnostic accuracy of CBCT for detection of second canal of permanent teeth: a systematic review and meta-analysis. *International Journal of Dentistry*. 2021;2021:1-18.
- Al-Habib M, Howait M. Assessment of mesiobuccal canal configuration, prevalence and inter-orifice distance at different root thirds of maxillary first molars: a CBCT study. *Clinical, Cosmetic and Investigational Dentistry*. 2021;105-111.
- Yoshioka T, Kikuchi I, Fukumoto Y, Kobayashi C, Suda H. Detection of the second mesiobuccal canal in mesiobuccal roots of maxillary molar teeth ex vivo. *Int Endod J*. 2005;38(2):124-128.
- Al Shalabi RM, Omer OE, Glennon J, Jennings M, Claffey NM. Root canal anatomy of maxillary first and second permanent molars. *Int Endod J*. 2000;33(5):405-414.
- Al Mheiri E, Chaudhry J, Abdo S, El Abed R, Khamis AH, Jamal M. Evaluation of root and canal morphology of maxillary permanent first molars in an Emirati population: a cone-beam computed tomography study. *BMC Oral Health*. 2020;20:1-9.
- Mufadhal AA, Madfa AA. The morphology of permanent maxillary first molars evaluated by cone-beam computed tomography among a Yemeni population. *BMC Oral Health*. 2023;23(1):1-12.
- Induja, MP, Anjaneyulu K, Kumar MPS. Root canal morphology of the mesiobuccal root of maxillary first molars: CBCT study. *Int J Dentistry Oral Sci*. 2021;8(5):2416-2419.
- Kieffer P, Connert T, ElAyouti A, Weiger R. Treatment of calcified root canals in elderly people: a clinical study about the accessibility, the time needed and the outcome with a three-year follow-up. *Gerodontology*. 2017;34(2):164-170.
- Reis, AGDAR, Soarez RG, Barletta FB, Fontanella VRC, Mahl CRW. Second canal in mesiobuccal root of maxillary molars is correlated with root third and patient age: a cone-beam computed tomographic study. *J Endod*. 2013;39(5):588-592.
- Zhang Y, Xu H, Wang D, et al. Assessment of the second mesiobuccal root canal in maxillary first molars: a cone-beam computed tomographic study. *J Endod*. 2017;43(12):1990-1996. doi:10.1016/j.joen.2017.06.021
- Cimilli H, Mumcu G, Cimilli T, Kartal N, Wesselink P. The correlation between root canal patterns and interorifice distance in mandibular first molars. *Oral Surg Oral Med Oral Pathol Oral Radiol Endod*. 2006;102:e16-21.
- Su CC, Wu YC, Chung MP, et al. Geometric features of second mesiobuccal canal in permanent maxillary first molars: a cone-beam computed tomography study. *J Dent Sci*. 2017;12(3):241-248. doi:10.1016/j.jds.2017.03.002