

PAPER DETAILS

TITLE: Utilizing the MRI findings to diagnose acute appendicitis in pregnant women

AUTHORS: Zeynep Yildiz,Fuldem Mutlu

PAGES: 1387-1392

ORIGINAL PDF URL: <https://dergipark.org.tr/tr/download/article-file/3417989>

Utilizing the MRI findings to diagnose acute appendicitis in pregnant women

 Zeynep Yıldız,  Fuldem Mutlu

Department of Radiology, Sakarya University Training and Research Hospital, Sakarya, Turkey

Cite this article as: Yıldız Z, Mutlu F. Utilizing the MRI findings to diagnose acute appendicitis in pregnant women. *J Health Sci Med.* 2023;6(6):1387-1392.

Received: 19.09.2023

Accepted: 21.10.2023

Published: 29.10.2023

ABSTRACT

Aims: To assess the performance of magnetic resonance imaging (MRI) scale for the diagnosis of acute appendicitis in pregnant women and to determine the added diagnostic value of MRI imaging.

Methods: In this retrospective study, the data of patients who presented to our hospital emergency department between January 2018 and December 2021, had clinical and laboratory findings consistent with acute appendicitis, and were diagnosed with radiological imaging, were extracted from the hospital automation system and used for statistical analysis. Ultrasound (US) was used as the first-line diagnostic method for pregnant patients, and magnetic resonance imaging (MRI) was used as the second-line diagnostic method. The success of US and MRI examinations in diagnosing acute appendicitis was evaluated. In MRI examinations, the mean values of appendix diameter and wall thickness parameters were examined, and the sensitivity, specificity, positive predictive value, and negative predictive value of periappendiceal fat tissue intensity increase, T2A lumen hyperintensity, and periappendiceal fluid parameters were evaluated. Additionally, the frequency of acute appendicitis according to trimesters was examined. SPSS v20.0 (IBM SPSS Statistics for Windows, Version 20.0; Armonk, NY, USA) package program was used for the analysis.

Results: When the medical records of 200 patients diagnosed with appendicitis were retrospectively examined, it was determined that there were 13 pregnant cases diagnosed with MRI during this period. Sensitivity, specificity, positive predictive value, and negative predictive value were evaluated for parameters including intraluminal T2A hyperintensity, wall thickness, periappendiceal fluid accumulation, and periappendiceal fatty tissue intensity increase. Intraluminal T2A hyperintensity and also periappendiceal fatty tissue intensity increase parameter sensitivity was 100%, however the wall thickness parameter had a sensitivity of 60% and the periappendiceal fluid accumulation parameter had a sensitivity of 80%. the periappendiceal fatty tissue intensity increase parameter had a specificity of 33.3%, which is the lowest ratio among the other parameters. there was also no significant difference in the frequency of acute appendicitis according to trimesters

Conclusion: MRI examination has a high success rate and can be used as the primary diagnostic method for pregnant appendicitis cases. In terms of parameter evaluation, the highest positive predictive value (90.9%) is found by the parameter of intraluminal T2 hyperintensity, and the parameter of periappendiceal fluid collection is found to be in the second place. The success of T2A lumen hyperintensity and periappendiceal fat tissue intensity increase parameters, especially in excluding negative cases, was found to be quite high.

Keywords: Magnetic resonance imaging, acute, appendicitis, ultrasonography, pregnant women

INTRODUCTION

Acute appendicitis is one of the most common surgical diseases among pregnant women.^{1,2} Early diagnosis of acute appendicitis in pregnant patients is crucial due to its potential to reduce both fetal and maternal mortality and morbidity. Therefore, timely visualization of the inflamed appendix on a good and appropriate imaging examination is crucial for accurate diagnosis of acute appendicitis in pregnancy to improve the maternal and fetal outcomes.³

Computerized tomography (CT) is very accurate for diagnosis of acute appendicitis.^{4,5} Nonetheless, CT is deemed inappropriate for pregnant women and fetuses because of its ionizing radiation.^{5,6}

Although ultrasound (US) examination is the first recommended diagnostic test in pregnant patients, it becomes challenging, especially in the second and third trimesters, due to the increased size of the uterus leading to a change in the position of the appendix. In the literature, it has been reported that the rate of failure to visualize the appendix with US in pregnant patients can reach up to 97% in the second and third trimesters.⁷

Magnetic resonance imaging (MRI) has been increasingly used as a second-line diagnostic method in recent years. The sensitivities and specificities of MRI on acute appendicitis have been reported to range above 90%.³

Corresponding Author: Fuldem Mutlu, fuldemmutlu@gmail.com



This work is licensed under a Creative Commons Attribution 4.0 International License.

METHODS

The study was carried out with the permission of Sakarya University Faculty of Medicine Non-interventional Ethics Committee (Date: 02.04.2022, Decision No: 123). All procedures were carried out in accordance with the ethical rules and the principles of the Declaration of Helsinki.

This study investigates the success of US and MRI examinations in diagnosing acute appendicitis in pregnant patients. A retrospective study was conducted at our hospital between January 2018 and December 2021. The initial number of appendicitis cases was 200; however, thirteen pregnant patients with clinical, laboratory, and examination findings compatible with acute appendicitis, regardless of age, were included in the study.

All pregnant patients underwent ultrasound (US) examination as the first-line diagnostic method. Regardless of whether a appendicitis diagnosis was suspected by ultrasound, magnetic resonance imaging (MRI) was requested as the second-line diagnostic method for all pregnant patients by the surgeons to confirm the diagnosis. Patients without a histopathological diagnosis and those with inadequate quality US and MRI images were excluded from the study.

All non-contrast-enhanced MRI examinations were performed with a 1.5-Tesla scanner with anterior array body coil. Patient's trimesters were also noted during imaging. For pregnant patients who underwent MRI examination, the mean values of appendix diameter and wall thickness, as well as the sensitivity, specificity, positive predictive value, and negative predictive value of parameters such as T2A lumen hyperintensity, increased intensity of periappendiceal fat tissue, and the presence of periappendiceal fluid, were evaluated. Axial and coronal T2-weighted sequences were obtained for visualizing the appendix. However, diffusion-weighted sequences were not included in our examinations. Contrast agents were not administered to the patients due to their pregnancy. These MRI acquisitions were retrospectively reviewed by experienced radiologists who were blinded to final diagnosis.

Statistical Analysis

Descriptive statistics were presented as number (n) and percentage (%) for categorical variables, and as mean \pm standard deviation and median [1st quartile-3rd quartile] for numerical variables. Pathology results were considered the gold standard diagnostic test. Sensitivity, specificity, positive predictive value, and negative predictive value were calculated for other tests that could be used for diagnosis. Chi-square tests were used to examine the relationship between two different categorical variables in independent groups. In 2x2 tables, Fisher's exact test was used if the smallest expected value was <5 , Yates' corrected chi-square test was used if it was ≥ 5 and ≤ 25 , and Pearson's

chi-square test was used if it was >25 . Pearson's chi-square test was used for tables in the RxC format. When examining the frequency of a categorical variable at two different times within the same group (dependent groups), the Mc Nemar test (2x2 chi-square test for dependent samples) was used if the variable had two groups, and the marginal homogeneity test (2xC) was used if the variable had three or more groups. When examining the difference in numerical variables between two dependent groups, the t-test was used if the data followed a normal distribution, and the Wilcoxon t-test was used if there was no normal distribution. Normal distribution was evaluated using the Shapiro-Wilk test. A statistical significance level of $p < 0.05$ was considered. SPSS v20.0 (IBM SPSS Statistics for Windows, Version 20.0; Armonk, NY, USA) software package was used for the analyses.

RESULTS

In our study, firstly we investigated the success of ultrasound and mri examination in diagnosing acute appendicitis in the pregnant patient group. Ultrasound examination was used as the first-line diagnostic method in our study, and among the 13 patients with clinical and laboratory findings compatible with acute appendicitis, the appendix could be visualized by ultrasound examination in only 3 of them, with all parameters being evaluated. Only 2 patients were diagnosed with acute appendicitis through ultrasound examination, and in 1 patient whose pathology result was compatible with acute appendicitis, the appendix was evaluated as normal by ultrasound examination.

Clinical and laboratory findings were consistent with acute appendicitis, and the diagnosis of acute appendicitis was confirmed through imaging methods in 13 pregnant patients, evaluated according to trimesters. In the first trimester, acute appendicitis was diagnosed in 4 individuals, with 75% (3 individuals) having pathological results consistent with acute appendicitis and 25% (1 individual) not consistent with acute appendicitis. In the second trimester, 100% (2 individuals) had pathology results consistent with acute appendicitis, and in the third trimester, 71.4% (5 individuals) had pathological results consistent with acute appendicitis, while 28.6% (2 individuals) did not. There was no significant difference in the frequency of acute appendicitis between trimesters ($p > 0.001$)

Thirteen pregnant patients underwent MRI examination. According to the radiological diagnosis, the mean appendix diameter value for the 13 patients who underwent MRI examination was 9.23 mm with a standard deviation of 2.38. The median (minimum-maximum) values were calculated as 8.0 (8.00-9.50) (Table 1).

Table 1. Average appendix diameter value in pregnant patients on MRI

	Mean ± Standard Deviation	Median [1 st Quartile - 3 rd Quartile]	Number
MRI-diameter	9.23±2.38	8 [8.00- 9.50]	13

The pregnant patients, suspected by clinical underwent MRI examination regardless of whether an appendicitis diagnosis was made by ultrasound to confirm the diagnosis by the surgeon's request. Sensitivity, specificity, positive predictive value, and negative predictive value were evaluated for parameters including intraluminal T2A hyperintensity, wall thickness, periappendiceal fluid accumulation, and periappendiceal fatty tissue intensity increase. The sensitivity of the intraluminal T2A hyperintensity parameter was 100%, its specificity was 66.7%, and its positive and negative predictive values were 90.9% and 100%, respectively. The wall thickness parameter had a sensitivity of 60%, a specificity of 66.7%, a positive predictive value of 66.7%, and a negative predictive value of 25%. The periappendiceal fatty tissue intensity increase parameter had a sensitivity of 100%, a specificity of 33.3%, and positive and negative predictive values of 83.3% and 33.3%, respectively. The periappendiceal fluid accumulation parameter had a sensitivity of 80%, a specificity of 67.7%, and positive and negative predictive values of 88.9% and 50%, respectively (Table 2) (Table 3) (Table 4) (Table 5) (Table 6).

Table 2. Appendiceal wall thickness values in patients undergoing MRI examination based on radiological diagnosis

	Mean± Standard Deviation	Median [1 st Quartile - 3 rd Quartile]	Number
MRI- Wall Thickness	1.69 ± 0. 63	2 [1.00- 2.00]	13

Table 3. MRI- evaluation of the relationship between T2A lumen hyperintensity and pathology

MRI- T2A Lumen Hyperintensity	Pathology n(%)		p value
	Positive	Negative	
Positive	10 (90.9%)	1 (9.1%)	0.038
Negative	0 (0.0%)	2 (100%)	

Fisher's Exact Test

Table 4. MRI- periappendiceal fluid accumulation and its relationship with pathology evaluation

Periappendiceal Fluid	Pathology n(%)		p value
	Positive	Negative	
Positive	8 (88.9%)	1 (11.1%)	0.203
Negative	2 (50.0%)	2 (50.0%)	

Fisher's Exact Test

Table 5. MRI- evaluation of the relationship between wall thickness parameter and pathology

MRI- Wall Thickness	Pathology n(%)		p value
	Positive	Negative	
Positive	6 (75%)	2 (25%)	
Negative	4(80%)	1(20%)	

Fisher's Exact Test

Table 6. MRI- evaluation of the relationship between periappendiceal fat tissue intensity increase parameter and pathology

MRI- Periappendiceal Fat Tissue Intensity Increase	Patoloji n (%)		p value
	Positive	Negative	
Positive	10 (83.3%)	2 (16.7%)	
Negative	10 (76.9%)	3 (23.1%)	

Fisher's Exact Test

DISCUSSION

Clinical symptoms are nonspecific on pregnant appendicitis cases, also physical examination at later stage of pregnancy can be misleading because typical presentation of appendicitis at Mcburney point is usually not elicited as a result of displaced cecum by an enlarged gravid uterus.⁸ As a result, in our study, similar to the literature, it was concluded that the success of ultrasound examination in diagnosing acute appendicitis and visualizing pathological appendices is quite low to MRI examinations for pregnant cases.

Contrast-enhanced CT is an accurate and rapid tool but is inappropriate for radiosensitive pregnant women.⁹ Ultrasound which is free from radiation hazard is almost as good as CT but the downside of it is operator dependent and can be affected by body habitus.^{10,11}

MRI examination has become an accepted trend to replace CT for appendicitis among pregnant women.¹²⁻¹⁵ Although there is no consensus on which sequences should be used for visualizing the appendix in MRI examinations in the current literature, the most common technical and sequence parameters used for visualizing the appendix in MRI include axial and coronal T2 HASTE, axial STIR, and coronal SPACE sequences. In our study, axial and coronal T2-weighted sequences were obtained for the purpose of visualizing the appendix. Regarding the imaging parameters, the following criteria were considered compatible with acute appendicitis: appendix diameter of 6 mm or greater, wall thickness measurement of 2 mm or greater, intraluminal T2-weighted hyperintensity, increased intensity in surrounding fatty tissue, and the presence of periappendiceal fluid (Figure 1, 2, 3). According to our study, both intraluminal T2 hyperintensity and periappendiceal fatty tissue intensity's sensitivity value is quite high as 100% for appendicitis cases. The most specific sign for appendicitis is periappendiceal fluid accumulation, wall thickness and intraluminal T2 hypersensitivity parameters, respectively. The periappendiceal fatty tissue intensity increase parameter is the least specific parameter for the diagnoses. The highest positive predictive value (90.9%) is found by the parameter of intraluminal T2 hyperintensity, and the parameter of periappendiceal fluid collection is found to be in the second place. Although negative predictive value is quite high (100%) for intraluminal T2 hyperintensity parameter, is the lowest for wall thickness parameter as 25%.

Some studies have also included diffusion-weighted series.¹⁶⁻¹⁸ Our study was retrospective, and diffusion weighted images were not recorded in our routine examinations, hence they could not be evaluated. The absence of diffusion-weighted sequences in the MRI examinations of the patients limits this study. Prospective studies can be conducted in the future to evaluate the contribution of diffusion-weighted sequences in diagnosing acute appendicitis in pregnant patients who present to the emergency department with symptoms suggestive of acute appendicitis.

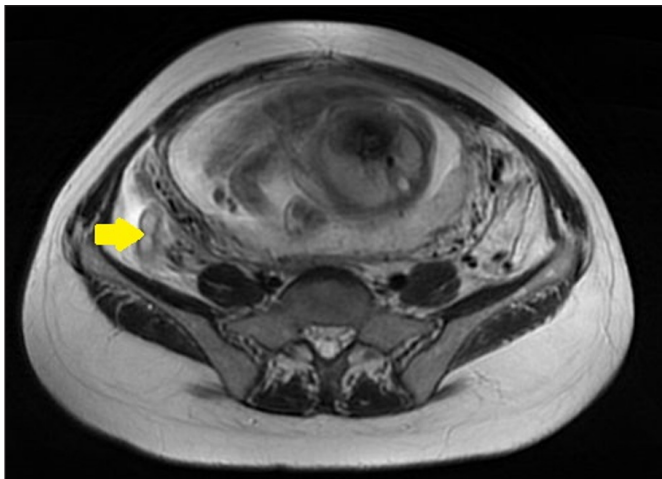


Figure 4.1. MRI Imaging Including Axial T2A Lower Abdominal Sections.

In the MRI imaging containing axial T2A lower abdominal sections; an increase in appendix diameter and wall thickness, as well as intraluminal minimal fluid-related luminal T2A hyperintensity (arrow)

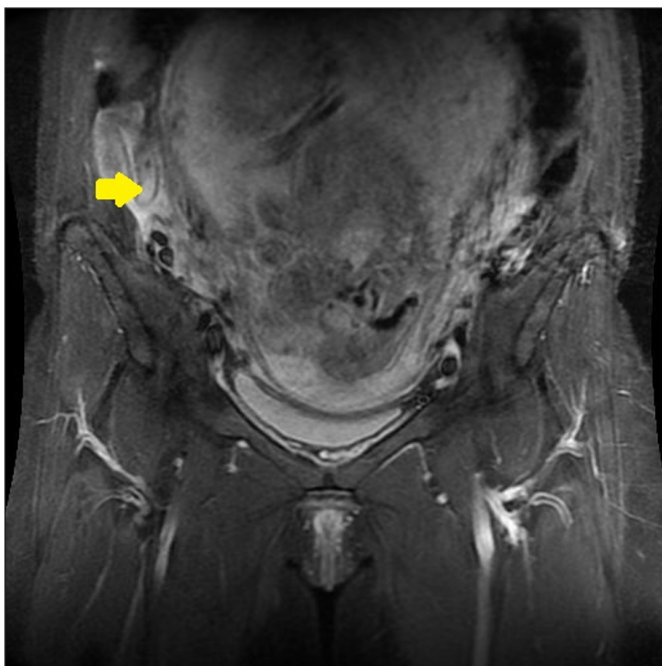


Figure 4.2. Coronal T2A Section Images of the Patient Diagnosed with Acute Appendicitis.

Coronal T2A MRI imaging of the pregnant patient diagnosed with acute appendicitis through histopathological examination; minimal increase in appendix wall thickness, intraluminal fluid-related luminal T2A hyperintensity (arrow), and minimal free fluid around the cecum.

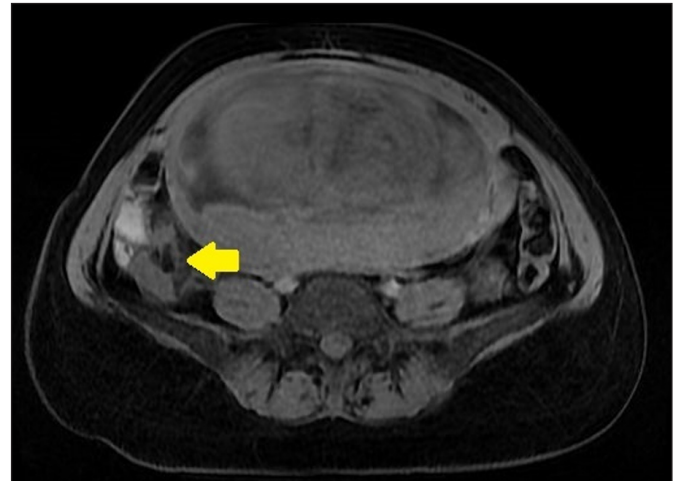


Figure 4.3. Fat-Suppressed T1A MRI Examination of the Patient Diagnosed with Acute Appendicitis.

In the MRI imaging containing axial fat-suppressed T1-weighted lower abdominal sections of the pregnant patient diagnosed with acute appendicitis through histopathological examination; there is an intensity increase, particularly in the periappendiceal fatty tissue, secondary to inflammation using the fat suppression technique

Among the 13 pregnant patients who underwent appendectomy in our study, the histopathological results were evaluated, and it was concluded that MRI examination was a highly accurate diagnostic tool for diagnosing acute appendicitis. Furthermore, it was found that MRI examination was significantly superior to ultrasound examination in diagnosing acute appendicitis, and it could be used as a first-line diagnostic method instead of ultrasound examination.

However, it should be noted that the accessibility and cost of MRI examination and the longer duration of the procedure compared to other diagnostic methods are limiting factors for the widespread use of MRI in diagnosing acute appendicitis. In recent years, many studies have been conducted on the contribution of MRI to the diagnosis of acute appendicitis in pregnant patient groups. These studies have examined the effectiveness of MRI use, its superiority over ultrasound and CT examinations, and its use in patients who cannot be diagnosed with ultrasound. Looking at sample reviews, a study by Sung Uk Cho and colleagues systematically presents the diagnostic accuracy of magnetic resonance imaging in the diagnosis of acute appendicitis in pregnant patients. This study demonstrated that MRI is generally highly accurate in diagnosing acute appendicitis in pregnant patients. Therefore, it was suggested that MRI could be used as the first-line imaging method in cases of suspected appendicitis in pregnant patients.¹⁹ In a meta-analysis study conducted by Mania Kave and colleagues, MRI examination was found to be a reliable method for diagnosing acute appendicitis 1. In our study, similar to the literature, it was concluded that MRI is a highly successful method for diagnosing acute appendicitis in pregnant patients.

There are several limitations to this study. Firstly, the number of patients included in the study is limited. Future studies with larger patient cohorts may increase the reliability of our findings and contribute more to the literature. MRI examination has shown high accuracy in diagnosing acute appendicitis in our study of pregnant patient population. However, the success of ultrasound examination in diagnosis and imaging of pregnant appendicitis cases is quite low. Therefore, MRI examination can be used as the primary imaging method for diagnosing acute appendicitis in pregnant patients. Nevertheless, the use of MRI examination is limited due to its cost, limited accessibility, and, most importantly, the long duration of the scan. Regarding the duration, there is currently no consensus on which sequences should be taken when diagnosing acute appendicitis, as different studies have shown variations. Thus, there is no clear consensus on the duration. Prospective studies to shorten the duration during MRI examinations and to determine the necessary sequences for diagnosing acute appendicitis can be conducted in future studies.

Acute appendicitis was observed in pregnant patients in all trimesters, with the highest frequency in the second trimester.²⁰ In our study, contrary to the literature there was no significant difference in the frequency of acute appendicitis among trimesters in pregnant patients.

CONCLUSION

In summary, MRI examination showed a high success rate in diagnosing acute pregnant appendicitis. In terms of parameter evaluation, the success of T2A lumen hyperintensity and periappendiceal fat tissue intensity increase parameters, especially in excluding negative cases, was found to be quite high. Our findings may provide valuable insights into determining the accuracy and reliability of diagnosing acute appendicitis in pregnant patients. This study may assist in better understanding how imaging methods can be utilized to increase the accuracy of diagnosing acute appendicitis in pregnant patients and reduce unnecessary surgical interventions. Future research is needed to validate and expand upon our findings in this field.

ETHICAL DECLARATIONS

Ethics Committee Approval: The study was carried out with the permission of Sakarya University Faculty of Medicine Non-interventional Ethics Committee (Date: 02.04.2022, Decision No: 123).

Informed Consent: Because the study was designed retrospectively, no written informed consent form was obtained from patients.

Referee Evaluation Process: Externally peer reviewed.

Conflict of Interest Statement: The authors have no conflicts of interest to declare.

Financial Disclosure: The authors declared that this study has received no financial support.

Author Contributions: All the authors declare that they have all participated in the design, execution, and analysis of the paper, and that they have approved the final version.

REFERENCES

1. Kave M, Parooie F, Salarzadei M. Pregnancy and appendicitis: a systematic review and meta-analysis on the clinical use of MRI in diagnosis of appendicitis in pregnant women. *World J Emerg Surg.* 2019;14:37. doi:10.1186/s13017-019-0254-1
2. Franca Neto AH, Amorim MM, Nóbrega BM. Acute appendicitis in pregnancy: literature review. *Rev Assoc Med Bras (1992).* 2015;61(2):170-177. doi:10.1590/1806-9282.61.02.170
3. Wong YC, Wang LJ, Wu CH, et al. Using MRI appendicitis scale and DWI for the diagnosis of acute appendicitis in pregnant women. *Eur Radiol.* 2023. doi:10.1007/s00330-023-10162-9.
4. Basaran A, Basaran M. Diagnosis of acute appendicitis during pregnancy: a systematic review. *Obstet Gynecol Surv.* 2009;64(7):481-499. doi:10.1097/OGX.0b013e3181a714bf
5. Chen MM, Coakley FV, Kaimal A, Laros RK Jr. Guidelines for computed tomography and magnetic resonance imaging use during pregnancy and lactation. *Obstet Gynecol.* 2008;112(2 Pt 1):333-340. doi:10.1097/AOG.0b013e318180a505
6. Pearce MS, Salotti JA, Little MP, et al. Radiation exposure from CT scans in childhood and subsequent risk of leukaemia and brain tumours: a retrospective cohort study. *Lancet.* 2012;380(9840):499-505. doi:10.1016/S0140-6736(12)60815-0
7. Aggenbach L, Zeeman GG, Cantineau AE, Gordijn SJ, Hofker HS. Impact of appendicitis during pregnancy: no delay in accurate diagnosis and treatment. *Int J Surg.* 2015;15:84-89. doi:10.1016/j.ijsu.2015.01.025
8. Brown JJ, Wilson C, Coleman S, Joypaul BV. Appendicitis in pregnancy: an ongoing diagnostic dilemma. *Colorectal Dis.* 2009;11(2):116-122. doi:10.1111/j.1463-1318.2008.01594.x
9. Patel SJ, Reede DL, Katz DS, Subramaniam R, Amorosa JK. Imaging the pregnant patient for nonobstetric conditions: algorithms and radiation dose considerations. *Radiographics.* 2007;27(6):1705-1722. doi:10.1148/rg.276075002
10. Baruch Y, Canetti M, Blecher Y, Yogev Y, Grisaru D, Michaan N. The diagnostic accuracy of ultrasound in the diagnosis of acute appendicitis in pregnancy. *J Matern Fetal Neonatal Med.* 2020;33(23):3929-3934. doi:10.1080/14767058.2019.1592154
11. Kazemini A, Reza Keramati M, Fazeli MS, Keshvari A, Khaki S, Rahnemai-Azar A. Accuracy of ultrasonography in diagnosing acute appendicitis during pregnancy based on surgical findings. *Med J Islam Repub Iran.* 2017;31:48. doi:10.14196/mjiri.31.48
12. Burke LM, Bashir MR, Miller FH, et al. Magnetic resonance imaging of acute appendicitis in pregnancy: a 5-year multiinstitutional study. *Am J Obstet Gynecol.* 2015;213(5):693.e1-693.e6936. doi:10.1016/j.ajog.2015.07.026
13. Burns M, Hague CJ, Vos P, Tiwari P, Wiseman SM. Utility of magnetic resonance imaging for the diagnosis of appendicitis during pregnancy: a canadian experience. *Can Assoc Radiol J.* 2017;68(4):392-400. doi:10.1016/j.carj.2017.02.004
14. Rapp EJ, Naim F, Kadivar K, Davarpanah A, Cornfeld D. Integrating MR imaging into the clinical workup of pregnant patients suspected of having appendicitis is associated with a lower negative laparotomy rate: single-institution study. *Radiology.* 2013;267(1):137-144. doi:10.1148/radiol.12121027

15. Wi SA, Kim DJ, Cho ES, Kim KA. Diagnostic performance of MRI for pregnant patients with clinically suspected appendicitis. *Abdom Radiol (NY)*. 2018;43(12):3456-3461. doi:10.1007/s00261-018-1654-5
16. Ahmed B, Williams J, Gourash W, et al. MRI as First line imaging for suspected acute appendicitis during pregnancy: diagnostic accuracy and level of inter-radiologist agreement. *Curr Probl Diagn Radiol*. 2022;51(4):503-510. doi:10.1067/j.cpradiol.2021.09.001
17. Islam GMN, Yadav T, Khera PS, et al. Abbreviated MRI in patients with suspected acute appendicitis in emergency: a prospective study. *Abdom Radiol (NY)*. 2021;46(11):5114-5124. doi:10.1007/s00261-021-03222-5
18. Mervak BM, Wilson SB, Handly BD, Altun E, Burke LM. MRI of acute appendicitis. *J Magn Reson Imaging*. 2019;50(5):1367-1376. doi:10.1002/jmri.26709
19. Cho SU, Oh SK. Diagnostic accuracy of magnetic resonance imaging for acute appendicitis during pregnancy: a systematic review. gebelikte akut apandisit için manyetik rezonans görüntülemenin tanısal doğruluğu: sistematik bir inceleme. *Ulus Travma Acil Cerrahi Derg*. 2021;27(3):271-277. doi:10.14744/tjtes.2020.02416
20. Çınar H, Aygün A, Derebey M, et al. Significance of hemogram on diagnosis of acute appendicitis during pregnancy. *Ulus Travma Acil Cerrahi Derg*. 2018;24(5):423-428. doi:10.5505/tjtes.2018.62753