

PAPER DETAILS

TITLE: FABRICATION OF A SCREW-RETAINED HYBRID PROSTHESIS FOLLOWING
TREATMENT OF PERI-IMPLANT DEFECTS: A CASE REPORT

AUTHORS: Bebek Serra Oguz Ahmet,Gülsüm Sayin Özel,Hilal Uslu Toygar

PAGES: 57-61

ORIGINAL PDF URL: <https://dergipark.org.tr/tr/download/article-file/235425>

FABRICATION OF A SCREW-RETAINED HYBRID PROSTHESIS FOLLOWING TREATMENT OF PERI-IMPLANT DEFECTS: A CASE REPORT*

Peri-İmplant Defektlerinin Tedavisini Takiben Yapılan Vida Retansiyonlu Bir Hibrid Protez: Olgu Bildirisi

Bebek Serra OĞUZ-AHMET¹, Gülsüm SAYIN-ÖZEL¹, Hilal USLU TOYGAR²

Received: 24/12/2015

Accepted: 22/02/2016

ABSTRACT

The etiology of marginal bone loss around osseointegrated implants is primarily based on the biomechanical and/or microbial factors. If stresses and strains around dental implants under functional loading conditions are expected to exceed the physiologic tolerance thresholds of the alveolar bone, the fixed hybrid prosthesis might be a more reliable treatment of choice instead of fixed metal ceramic restorations. The purpose of this article is to report the 1-year follow-up of the periodontal and prosthetic rehabilitation of a patient who has presented with symptoms of peri-implantitis due to incorrectly planned implant supported fixed metal ceramic bridge which was later replaced with screw-retained hybrid prosthesis following the treatment of peri-implant defects. Treatment helped to maintain patient's self-confidence and comfort, as well as favorable masticatory function. Rehabilitation with screw retained hybrid prosthesis is an ideal treatment of choice for maxillomandibular skeletal discrepancies.

Keywords: Dental implants; occlusal force; hybrid prosthesis; peri-implantitis

ÖZ

Osseointegre implantların etrafındaki kemik kaybının etyolojisi, primer olarak biyomekanik ve/veya mikrobiyal faktörlere dayanır. İnsan çene kemiklerinde oluşan gerilme ve gerilim kuvvetlerinin fizyolojik tolerans eşiğinin üstünde olduğu durumlarda; sabit metal seramik restorasyonların yerine, sabit hibrid protezler daha güvenilir bir tedavi seçeneği olabilir. Bu olgu bildirisinin amacı, yanlış olarak planlanmış implant destekli sabit bir metal seramik köprüye sahip olan ve mevcut implantlarında peri-implantitis bulunan bir hastanın; peri-implant defektlerinin tedavisi sonrasında periodontal ve protetik rehabilitasyonun 1 yıllık takibini sunmaktır. Yapılan tedavi, hastanın hem özgüveninin ve rahatının kazandırılmasını, hem de etkili bir çiğneme fonksiyonuna sahip olmasını sağlamıştır. Vida retansiyonlu hibrid protezler ile yapılan oral rehabilitasyon, maksillomandibular iskeletsel malokluzyonlar için ideal bir tedavi seçeneğidir.

Anahtar kelimeler: Dental implantlar; okluzal kuvvet; hibrid protez; peri-implantitis

¹ Department of Prosthodontics Faculty of Dentistry Istanbul Medipol University

² Department of Periodontology Faculty of Dentistry Istanbul Medipol University

*This article has been presented as a poster in the 22th International Congress of the Turkish Prosthodontics and Implantology Association, 12th-15th November 2015, Antalya, Turkey.



Introduction

The etiology of marginal bone loss around osseointegrated implants is primarily based on biomechanical and/or microbial factors (1). Unfavorable force distribution pattern in peri-implant bone might cause implant loss or mechanical failures in the prosthetic structure when the generated stresses and strains exceed the physiologic tolerance thresholds of the alveolar bone (2). Accordingly, some in- vivo studies conducted in animals have revealed that the stresses beyond this threshold may cause marginal bone loss or complete loss of osseointegration (3-6). Large cantilevers, parafunctional habits, improper occlusal designs and premature contacts may cause excessive loads which adversely affect the survival rate of the implants. Therefore, optimal occlusion within physiologic limits is an important factor to ensure the long-term implant success (7). However, same amount of stress may result in different amount of strain in bones having different mechanical properties (8). In addition, dental implant failure cannot be attributed solely to the occlusal overload, since the formation of plaque-induced peri-implant inflammation may have a prominent role in the etiology of the alveolar bone loss (9). Besides, in a recent animal study, Ignace *et al.* (10) demonstrated that supra-occlusal contacts have negatively affected osseointegration only in the presence of plaque induced inflammation. Consequently, there are conflicting reports concerning the marginal bone level alterations resulting from excessive occlusal load (3, 11-13).

Factors which may lead to the failure of osseointegrated implants are currently a matter of debate. In cases with increased occlusal vertical dimension, Class III skeletal disposition, atrophic jaws or micrognathia, fixed hybrid prosthesis might be a more reliable treatment option when compared to fixed

metal ceramic restorations in order to maintain adequate lip support, phonetics and esthetics. Biomechanical problems related to inconvenient labial moment arm forces can therefore be avoided (14). The purpose of this article is to report the 1-year follow-up of the periodontal and prosthetic rehabilitation of a patient who has presented with symptoms of peri-implantitis due to incorrectly planned implant supported fixed metal ceramic bridge which was later replaced with screw-retained hybrid prosthesis following the treatment of peri-implant defects.

Case Report

A 64 year-old female patient applied to our department with prosthesis related complaints. She had a ten unit fixed porcelain-fused-to-metal framework supported by five implant fixtures (Tapered Screw-Vent®, Zimmer Dental, Carlsbad, CA, USA) in her maxilla which, according to patient's claim, has become decemented multiple times. Other restorations were as follows : a six unit fixed porcelain bridge in the right mandibular region which extends from the second molar to the lateral incisor, two prepared natural teeth and three implants (Tapered Screw-Vent®, Zimmer, USA) in the left mandibular region with no restoration. Due to patient's psychological breakdown, no intra- or extra-oral photographs could be taken at this stage. The patient was also complaining about poor esthetics, the lack of lip support and insufficient mastication. Following clinical and radiographic examinations, marginal bone loss and peri-implantitis were detected around all implants. Since these findings may be caused by excessive force loads resulting from incorrect prosthetic design (Figure 1, Figure 2), patient was informed about screw retained hybrid prosthesis concept and following clinical and laboratory procedures were performed.

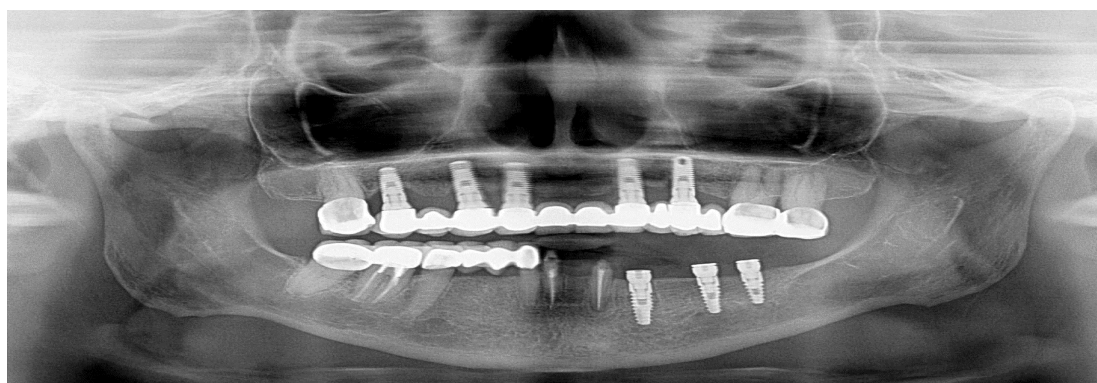


Figure 1. Panoramic radiograph of the patient prior to treatment.

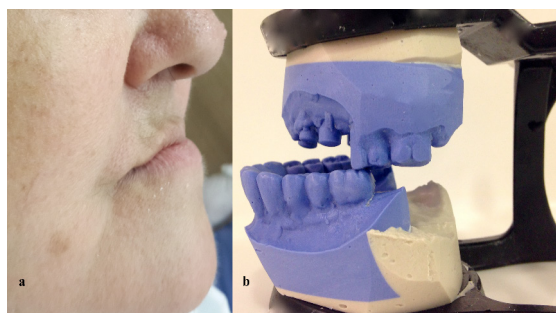


Figure 2. (a) Initial lateral view of the patient (b) Diagnostic casts.

At the first stage, alveolar bone defects around the implants placed in maxilla were treated with guided tissue regeneration techniques using bone grafting material (MinerOss, Medtronic Sofamor Danek USA Inc, Memphis, TN, USA) and collagen membrane (Mem-Lok, Biohorizons Inc., Birmingham, AL, USA). Natural teeth and implants in the mandible were also restored with fixed porcelain bridges. After three months of osseointegration period, the healing caps were removed and impression copings were connected to the implants. Final impression was taken by using customized open-tray technique with polyvinyl siloxane impression material (Honigum Heavy Fast, DMG Chemisch-Pharmazeutische Fabrik GmbH., Hamburg, Germany). Implant analogs were attached to the maxillary impression and type IV dental stone (Elite Master, Zhermack SpA, Rovigo, Italy) was poured. Master casts were recovered and trimmed. A maxillary record base with wax occlusal rim was fabricated conventionally. Patient was recalled to record horizontal and vertical maxillomandibular relations and tooth selection. Master casts were then mounted on a semi-adjustable articulator. (Condylator Simplex, Gerber Condylator Service, Zurich, Switzerland). After positioning denture teeth (Artegral, Merz Dental GmbH, Lütjenburg, Germany), a wax/esthetic try-in was performed to confirm the accuracy of maxillomandibular relations and to obtain patient's approval of esthetics. A laboratory plaster matrix was fabricated on the trial tooth setup to preserve a clearance of the framework with the denture teeth. The framework was waxed, casted with chrome-nickel (Dew-SHS Type 3 Dental Alloys, Eisenbacher Dentalwaren ED GmbH, Bavaria, Germany), recovered and fitted to the implants on the master cast. The patient was recalled for the clinical framework fitting trial. After removing the healing caps, the framework was passively seated on the abutments and each abutment framework interface

was checked for an intimate fit (Figure 3). Following the denture tooth waxing on the metal framework, final evaluation of all maxillomandibular relations was completed. Following the patient's approval of the esthetics, hybrid prosthesis was invested/flasked and processed using a standard curing cycle as recommended by the manufacturer. The prosthesis was finished and polished, a clinical remount was performed to allow for refinement of occlusal contacts, and the screws of the hybrid prosthesis were sequentially tightened using the torque wrench. The access holes were plugged up with cotton pellets and a temporary filling material. Hygiene techniques were reviewed, and the patient was scheduled for recall and maintenance (Figure 4).

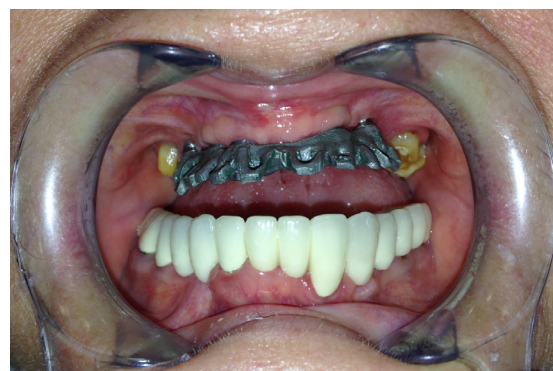

Figure 3. The metal framework passively seating on the abutments.

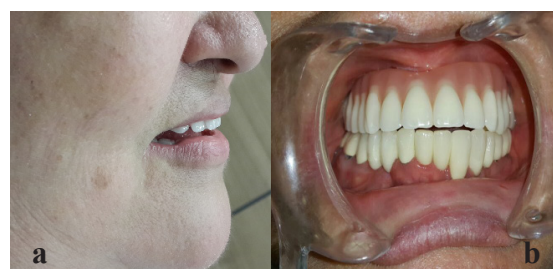

Figure 4. Delivery of definitive maxillary screw-retained hybrid prosthesis: Lateral profile view of the patient (a) and final occlusion (b).

Discussion

Biomechanical implant complications have been related to several factors such as the bone quality, implant surface characteristics, presence of parafunctional habits and prosthetic design (15). Therefore, management of edentulous maxilla with dental implants requires detailed planning and multidisciplinary approach during which all

the participants should discuss whether the patient should be restored with fixed or removable denture (16). Optimal load distribution should be considered when designing the prosthesis. Miyata *et al.* (17) stated that, although all occlusal stresses do not induce bone resorption, the effect of excess occlusal trauma should not be ignored considering the fact that it could possibly cause bone resorption around implants, even in the absence of inflammation in peri-implant tissue (13). Additionally, it is useful to keep in mind that the functional and excessive loads may have different effects. In an experimental study in dogs which was done by Berglundh *et al.* (18), histological analysis has revealed that, when the implants were functionally loaded under certain limits, contrary to bone loss, re-modeling was induced in the peri-implant bone area. Nevertheless, when making an implant retained prosthetic treatment planning, the existing oral conditions of the patient should be considered. Maxillary atrophy in the palatal direction in the edentulous patient often results in class III skeletal malocclusion. Therefore, it is advisable to take precaution against unsuitable forces on the labial arm (14). In the present case, the patient had an implant supported metal ceramic fixed bridge which has likely contributed to the marginal bone loss around the implants caused by the excessive and inadequately distributed masticatory forces. Considering the fact that the patient had maxillary micrognathia accompanied by severe atrophy which resulted in Class III skeletal malocclusion, we preferred to design an implant supported, screw-retained hybrid prosthesis that consists of minimalized framework enclosed in a bulk of acrylic resin denture base and artificial teeth in order to prevent overloading of the implants and to ensure a more acceptable esthetics by providing adequate lip support (19). It was pointed out that, for its esthetic and phonetic superiority, the hybrid prosthesis was preferred to a full-arch implant supported fixed bridge in patients with atrophic maxilla (14, 20). On the other hand, Solá-Ruiz *et al.* (21, 22) proposed an implant-supported overdenture design with horizontal facial path of insertion in the anteroposterior direction, in which the primary structure is screwed to the implants and the secondary structure slides over the first one. They emphasized that their design had significant advantages such as compensation of the negative intermaxillary discrepancy, improved implant prosthetic hygiene and esthetics in severe maxillary atrophy or Class III malocclusion. The lack of experienced dental

laboratory technician and high cost of this technique have led us to prefer screw-retained hybrid prosthesis in our case.

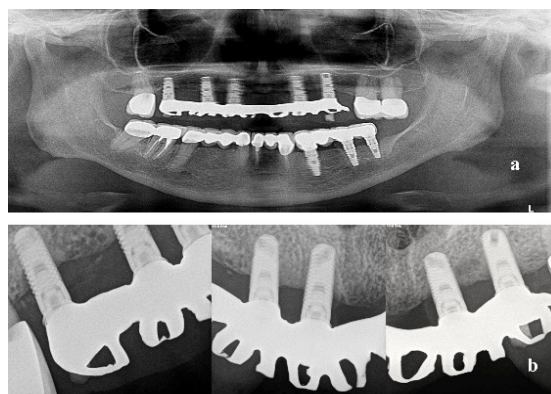


Figure 5. (a) Panoramic radiograph of the patient after one year follow-up period (b) Periapical views of the implants after one year follow-up period.

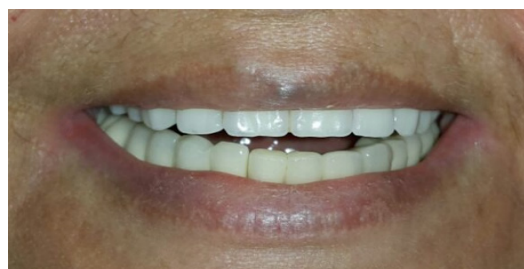

Figure 6. Clinical image of the patient smiling after one year follow-up period.

Conclusion

In the present case, during 1-year follow-up period, the patient was recalled after 7, 21 and 90 days. Gingival tissues around the abutments were found to be in good condition and, despite the lack of standardization, radiographic findings indicated healing of the bone defects (Figure 5). Significant improvement in the esthetics, phonetics and masticatory function have increased patient's self-confidence (Figure 6). There were no complications associated with the hybrid prosthesis and the patient satisfaction was extremely high.

Source of funding

None declared

Conflict of interest

None declared

References

1. van Steenberghe D, Naert I, Jacobs R, Quirynen M. Influence of inflammatory reactions vs. Occlusal loading on peri-implant marginal bone level. *Adv Dent Res* 1999;13:130-135.
2. Sahin S, Cehreli MC, Yalcin E. The influence of functional forces on the biomechanics of implant-supported prostheses--a review. *J Dent* 2002;30(7-8):271-282.
3. Isidor F. Loss of osseointegration caused by occlusal load of oral implants. A clinical and radiographic study in monkeys. *Clin Oral Implants Res* 1996;7(2):143-152.
4. Isidor F. Histological evaluation of peri-implant bone at implants subjected to occlusal overload or plaque accumulation. *Clin Oral Implants Res* 1997;8(1):1-9.
5. Isidor F. Clinical probing and radiographic assessment in relation to the histologic bone level at oral implants in monkeys. *Clin Oral Implants Res* 1997;8(4):255-264.
6. Isidor F. Mobility assessment with the periotest system in relation to histologic findings of oral implants. *Int J Oral Maxillofac Implants* 1998;13(3):377-383.
7. Ali B CE, Meddah HM, Merdji A, Bouiadjra BAB. Effects of overloading in mastication on the mechanical behaviour of dental implants. *Materials and Design* 2013;47(1):210-217.
8. Isidor F. Influence of forces on peri-implant bone. *Clin Oral Implants Res* 2006;17 (Suppl 2):8-18.
9. Chang M, Chronopoulos V, Mattheos N. Impact of excessive occlusal load on successfully-osseointegrated dental implants: A literature review. *J Investig Clin Dent* 2013;4(3):142-150.
10. Naert I, Duyck J, Vandamme K. Occlusal overload and bone/implant loss. *Clin Oral Implants Res* 2012;23 (Suppl 6):95-107.
11. Barbier L, Schepers E. Adaptive bone remodeling around oral implants under axial and nonaxial loading conditions in the dog mandible. *Int J Oral Maxillofac Implants* 1997;12(2):215-223.
12. Heitz-Mayfield LJ, Schmid B, Weigel C, Gerber S, Bosshardt DD, Jonsson J, Lang NP, Jonsson J. Does excessive occlusal load affect osseointegration? An experimental study in the dog. *Clin Oral Implants Res* 2004;15(3):259-268.
13. Miyata T, Kobayashi Y, Araki H, Ohto T, Shin K. The influence of controlled occlusal overload on peri-implant tissue. Part 3: A histologic study in monkeys. *Int J Oral Maxillofac Implants* 2000;15(3):425-431.
14. Norton MR, Ferber C. The nonresilient hybrid removable prosthesis: Treatment of choice for the atrophic maxilla. *Int J Periodontics Restorative Dent* 1999;19(2):189-197.
15. Fu JH, Hsu YT, Wang HL. Identifying occlusal overload and how to deal with it to avoid marginal bone loss around implants. *Eur J Oral Implantol* 2012;5 Suppl:S91-103.
16. Jivraj S, Chee W, Corrado P. Treatment planning of the edentulous maxilla. *Br Dent J* 2006;201(5):261-279.
17. Miyata T, Kobayashi Y, Araki H, Motomura Y, Shin K. The influence of controlled occlusal overload on peri-implant tissue: A histologic study in monkeys. *Int J Oral Maxillofac Implants* 1998;13(5):677-683.
18. Berglundh T AI, Lindhe J. Bone reactions to longstanding functional load at implants: An experimental study in dogs. *J Clin Periodontol*. 2005;32(9):925-932.
19. Drago C, Howell K. Concepts for designing and fabricating metal implant frameworks for hybrid implant prostheses. *J Prosthodont* 2012;21(5):413-424.
20. Small BW. Maxillary immediately loaded fixed hybrid prosthesis: A case report. *Gen Dent* 2009;57(1):10-13.
21. Agustin-Panadero R, Penarrocha-Oltra D, Gomar-Vercher S, Ferreiroa A, Penarrocha-Diago M. Implant-supported overdenture manufactured using cad/cam techniques to achieve horizontal path insertion between the primary and secondary structure: A clinical case report. *J Adv Prosthodont* 2015;7(3):264-270.
22. Sola-Ruiz MF, Agustin-Panadero R, Fons-Font A, Labaig-Rueda C. An implant-supported overdenture design with a horizontal path of insertion. *J Prosthet Dent* 2013;110(4):239-242.

Corresponding Author:

Bebek Serra OĞUZ-AHMET

Department of Prosthodontics Faculty of
Dentistry Istanbul Medipol University
Fatih/Istanbul Turkey
Phone: +90 212 453 49 37
e-mail: serraoguz@gmail.com