

PAPER DETAILS

TITLE: Can SK. 150 Teleradiography unit be used for various evaluations of the Maxillo-Facial Region ?

AUTHORS: Cengiz OKTAY

PAGES: 271-283

ORIGINAL PDF URL: <https://dergipark.org.tr/tr/download/article-file/94458>

Can SK. 150 Teleradiographic unit be used for various evaluations of the Maxillo-Facial Region ?

Dr. Cengiz OKTAY (*)

At present, Teleradiography in dentistry is mainly being used for orthodontic purposes. The evaluations in orthodontics as a common approach seem to be limited to P-A and lateral views.

This study has been undertaken whether or not, different views of the skull can be obtained as a step towards diagnosis.

The equipment used for the study is SK. 150 roentgenologic unit made by Siemens Company, the specifications of this unit is as following. «The unit provides front and lateral exposures of the skull, which by reason of approximately 150 cm focusfilm distance (F. F. D.) and is relatively free of geometric blurring. With the use of cephalometer, which is equipped with appropriate fixing devices, orthodontic treatment, for example requiring diagnostic and comparative exposures over that period of time with identical and exact adjustment can be carried out.»

«The cephalometer can be changed over from front to lateral exposures and vice versa with a very small amount of manipulation».

«The x-ray field can be collimated exactly on the object by means of the double-slot diaphragm with full-field light-beam indicator, whereby the exposure of the patient to radiation can be kept as small as

(*) Faculty of Dentistry, Atatürk University, Erzurum, Turkey.

possible in addition, the SK 150 can also be used for dental spet filming using the special cone». The unit has the capacity of 20 m. amp., 50-90 K. V. P. and adjustable time-exposure device varying between 0.1 - 5.0 second.

The films used in the study are Agfa-Gewart curix M₁ film with polyester base. Reinforcers used in the cassetts are special super high speed reinforcers made by Siemens. The upper reinforcer is R-55, 3261 and the bottom one is R-55, 3016 type.

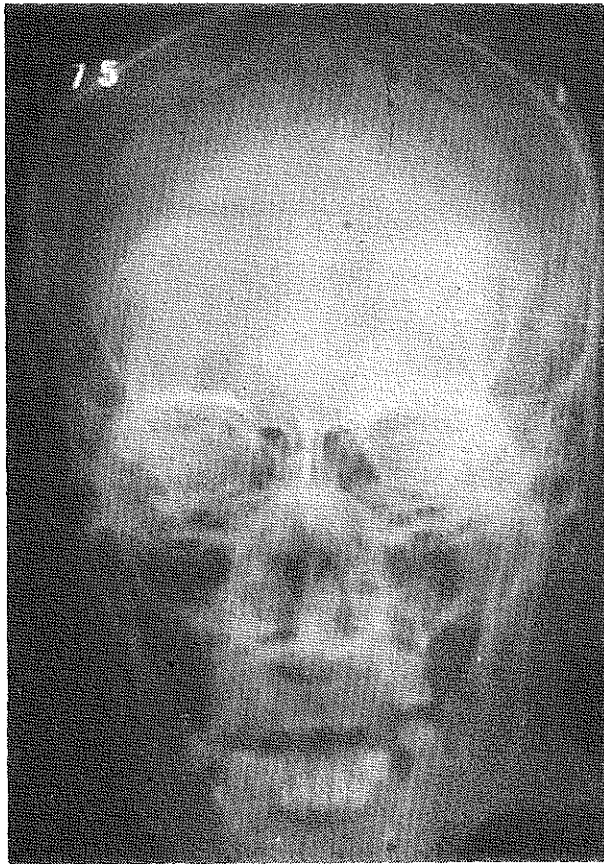
The positionings for various areas and applied film-tube distances, miliamperages, Kilo Volt Peaks exposure times and the angulations have been shown in table 1.

Table 1 :

| Table 1: Position of the skull and roentgenologic factors | | | | | | |
|---|-------------------------|-----------------|---------------|------------------|-----------------------|---------------------|
| Factors Positioning | Film - Tube Distance | MAmp Pec sec | Kvp | Exposure Time | Angulations | |
| | | | | | Horizontal Degrees | Vertical Degrees |
| Skull Anterior (P.A) | 50 cm | 20 | 65 | 3.2 | 90° | 00° |
| Skull Lateral | 50 cm | 20 | 55 | 3.2 | 90° | 90° |
| Skull Basilar (Submentovertex) | 50 cm | 20 | 70 | 3.2 | 90° | 90° |
| Skull -Werticohorizontal | 40 cm | 20 | 70 | 4.0 | 90° | 75° |
| Sinuses, Maxillary (Waters) erect | 40 cm | 20 | 60 | 4.0 | 90° | 90° |
| Sinuses - Lateral | 40 cm | 20 | 55 | 4.0 | 90° | 90° |
| (T.M.J) Lateral mouthclosed and open | 45 45 | 20 20 | 55 50 open | 3.2 3.2 | 90° 90° | 75° 75° |
| Facial bones lateral | 55 | 20 | 55 | 3.2 | 90° | 90° |
| Facial bones: Maxilla - oblique | 45 | 20 | 60 | 2.5 | 100° | 10° |
| Maxilla - inferior (Superoinferior) | 45 | 20 | 60 | 2.5 | 90° | 10° |
| Mandible (Condyles) | 50 | 20 | 60 | 4.0 | 90° | 16° |
| (P.A) Mandible symphysis | 50 | 20 | 60 | 2.5 | 0° | 20° |

1 — Postero-Anterior view of skull :

X — Ray



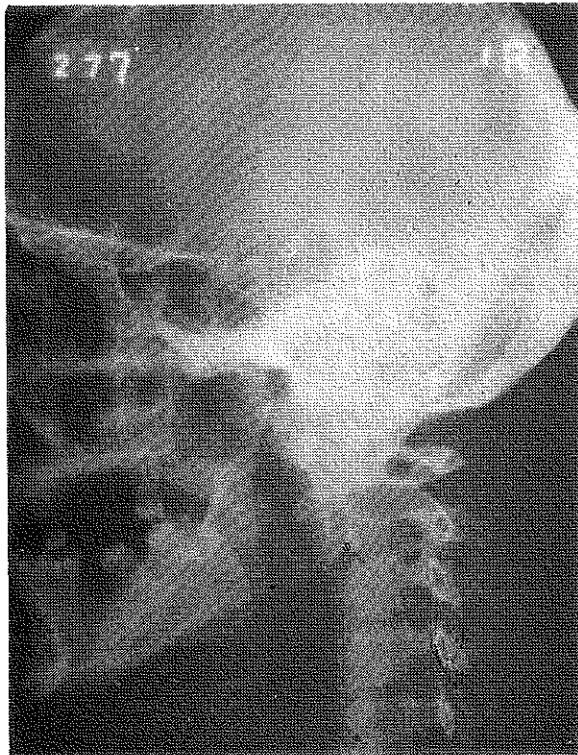
Skull - anterior (P-A) position

The following structures can be viewed in this position

- a) Anterior wall of the cranium
- b) Frontal sinuses
- c) Ethmoid sinuses
- d) Crista galli

2 — Lateral view of skull :

X — Ray



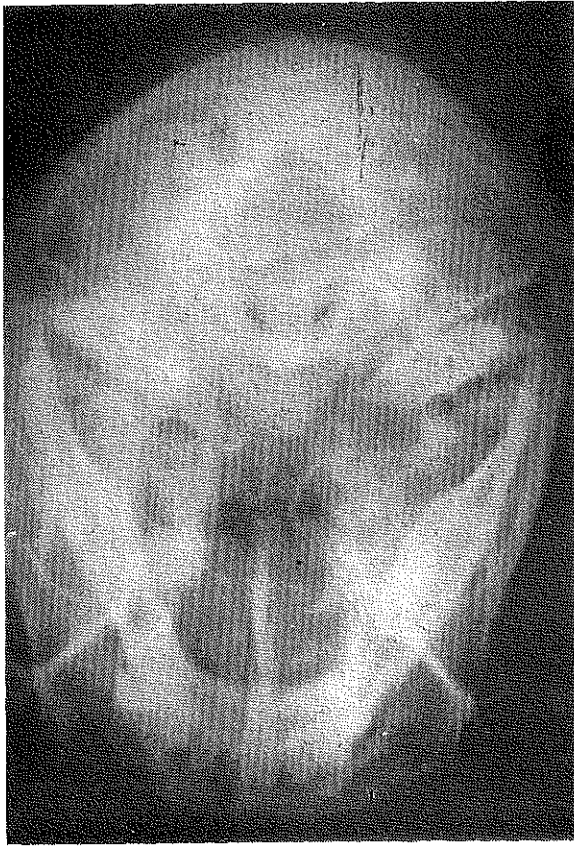
Skull - Lateral position

The structures viewed in this position are

- a) The anterior and posterior clinoid processes
- b) Sella Turcica
- c) Dorsum sella
- d) Superimposed parietal bones

3 — Basilar view of skull (submento-vertex positioning)

X — Ray



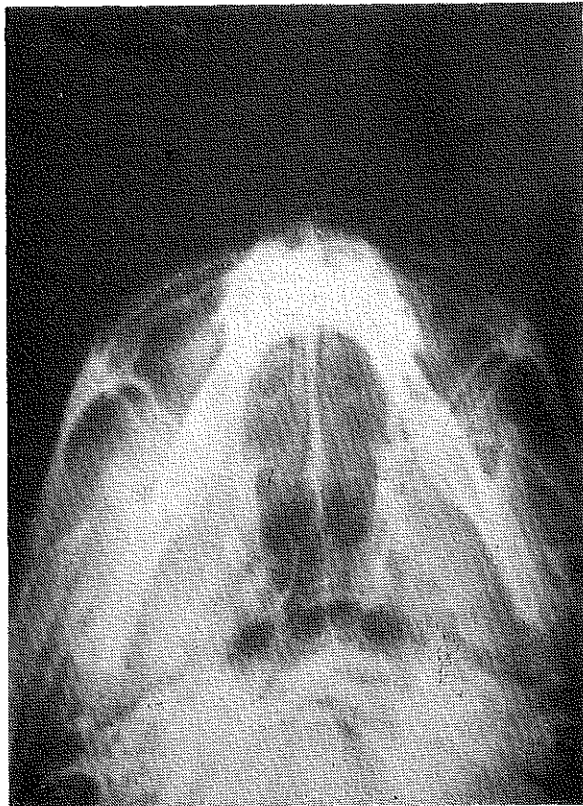
Skull . basilar (submentovertex) position

In this view the following structures can be evaluated :

- a) Bilateral petrous ridges
- b) Mastoid processes
- c) Atlas
- d) Sphenoidal sinuses .
- e) Maxillary sinuses
- f) Mandible
- g) Bilateral zygomatic arches

4 — Vertico submental view of the skull :

X — Ray



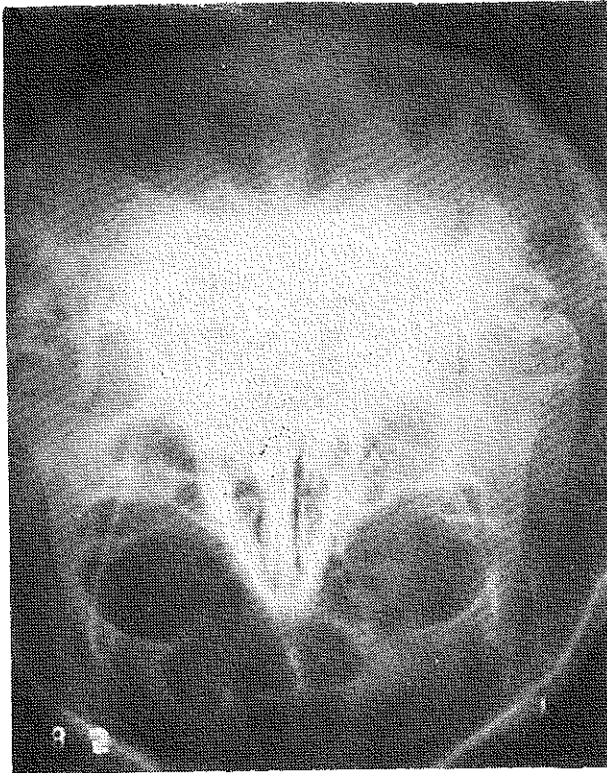
Skull - Verticosubmental position

Structures demonstrated in this view are

- a) Sphenoidal sinuses
- b) Anterior cranial base

5 — Water's position for maxillary sinuses

X — Ray

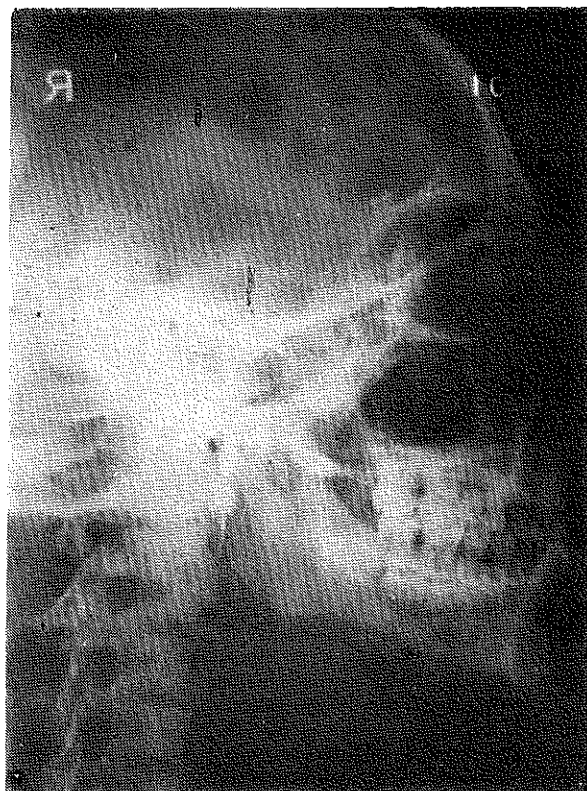


sinuses . maxillary (Waters) erect Position

The maxillary antrums, possible fluid levels, nasal septum, posterior walls of the eye orbit can be viewed in this position.

6 — Lateral view of sinuses :

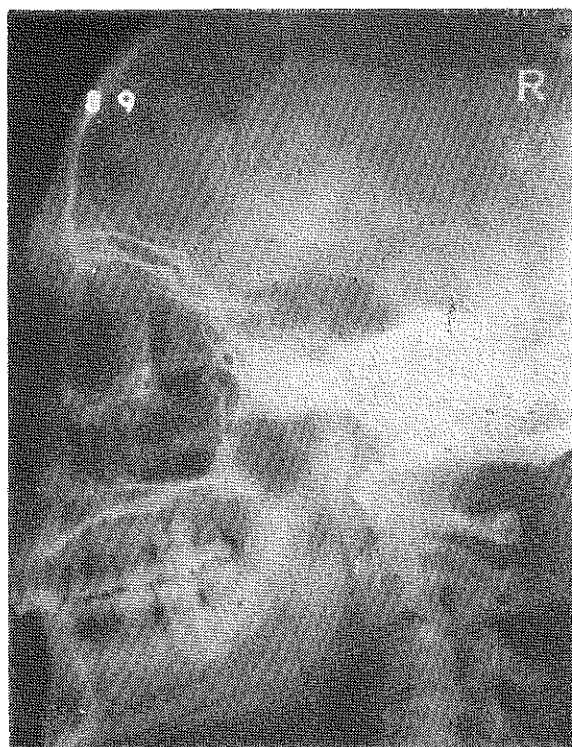
X — Ray



Lateral view of sinuses

7 — Temporomandibular joints lateral view (mouth open and mouth closed)

X — Ray

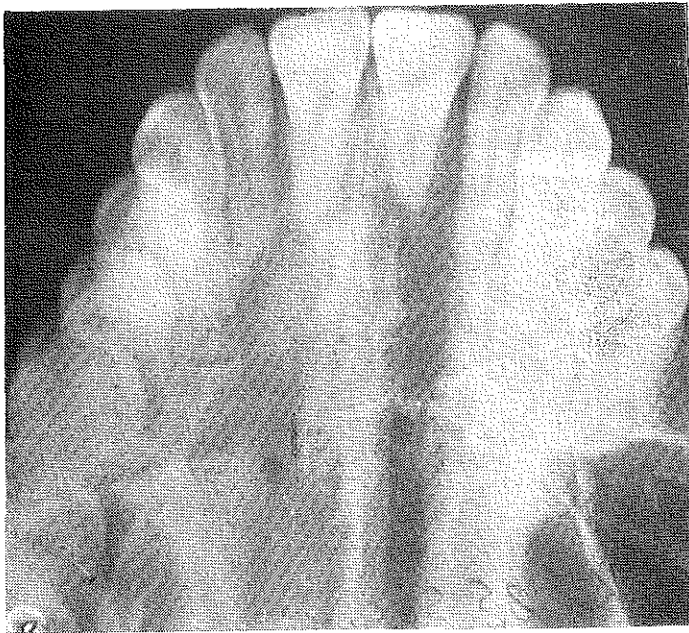


Temporomandibular joint position A-lateral (T.M.S.) position mouthopen

In this position lateral views of condyle in relation to the mandibular fossa can be evaluated.

8 — Maxillae, inferior (super-inferior) views: Film type occlusal-Dental film.

X — Ray

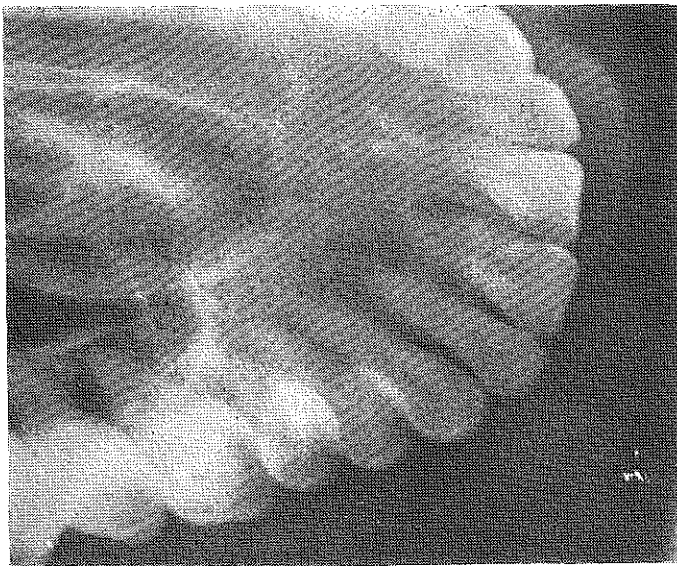


Facial bones : maxillae - inferior (Superoinferior) position

The upper incisors, the alveolar processes and the hard palate can be evaluated with this view.

9 — Oblique view of the alveolar process, hard palate bicuspids and molars of the maxilla being examined can be evaluated in this view.

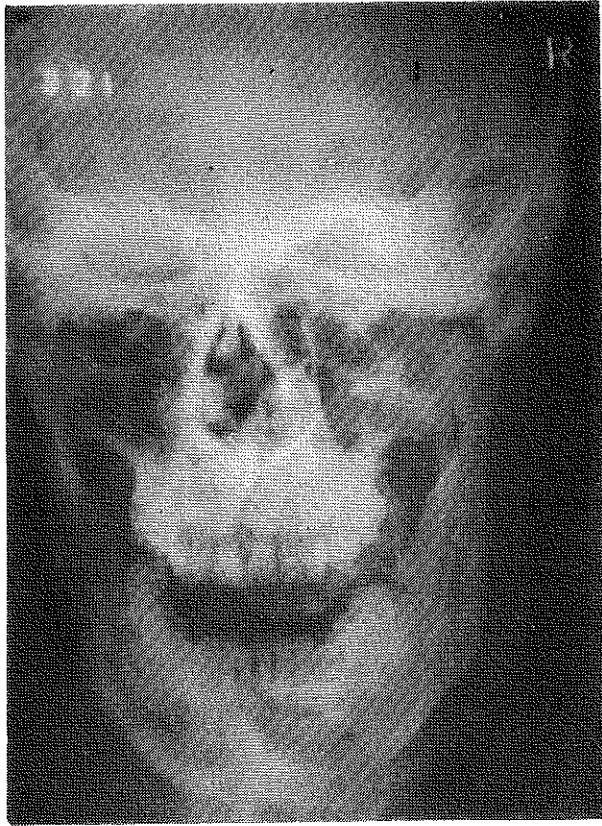
X — Ray



Facial bones : maxilla oblique position

10 — Mandibular condyle P-A view :

X — Ray

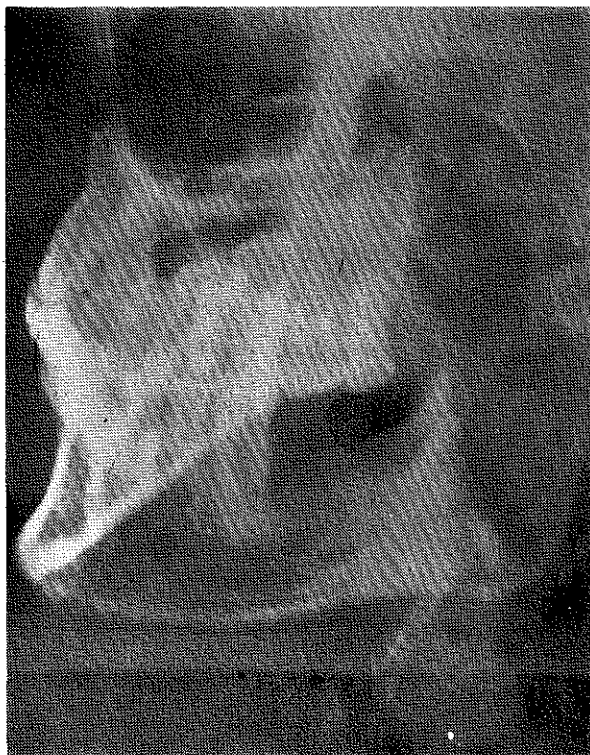

Mandibular condyle P-A

Anterior (P-A) view of mandibular body, rami and condyles can be evaluated in this view.

11 — Mandible lateral view (modified) :

X — Ray

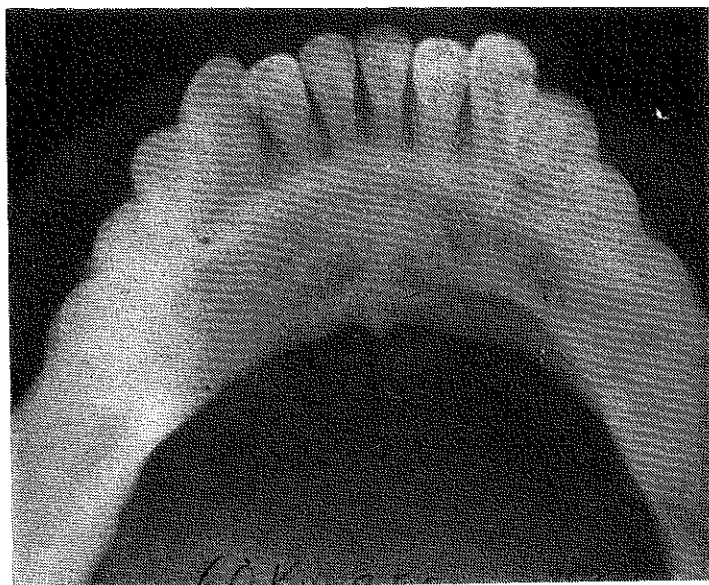


Facial bones : mandible - lateral Position

Medio lateral (lateral) view of the mandibular body, the symphysis and ramus may be demonstrated with a variation in head rotation. In this position, this view may be of great help when panoramic x-ray technique can not be applied, since there is always a superimposition in routine lateral technique it is quite possible to use this technique in evaluations of mandible fractures; pathologic lesions in corpus or ramus, and in cases where intra oral film techniques can not be applied.

12— Mandible (symphysis) submento-vertical view: Film type occlusal- Dental film.

X — Ray



Facial bones : mandible (Symphysis) submentovertical position

Submento vertical view of the mandibular symphysis can be demonstrated with this positioning.

Other maxillo-facial views can undoubtedly be obtained with SK-150 teleradiographic unit, but it is not our intension to demonstrate other views are not relevant to dentistry.

In conclusion, we may accept that, it is quite possible to use SK 150 teleradiographic unit with or without its cephalostat for multiple purposes in evaluation of maxillo-facial areas.

L I T E R A T Ü R

- 1 — **Jacobi, C. A., Paris, D. F.** : Text book of Radiologic technology, the C. V. Mosby Comp., Saint Louis, 1968.
- 2 — Teleradiographic unit «SK-150», booklet prepared by Siemnts comp.