

PAPER DETAILS

TITLE: Molecular Detection of Scrub Typhus Using Nested PCR Analysis in Chennai: A Case Report

AUTHORS: Seethalakshmi Srinivasan,Thangam Menon,Karunakaran N

PAGES: 164-168

ORIGINAL PDF URL: <https://dergipark.org.tr/tr/download/article-file/385307>

CASE REPORT

Molecular Detection of Scrub Typhus Using Nested PCR Analysis in Chennai: A Case Report

Seethalakshmi Srinivasan¹, Thangam Menon¹, Karunakaran N.²

¹Department of Microbiology, Dr. A L Mudaliar Post Graduate Institute of Basic Medical Sciences, University of Madras, Taramani, Chennai, India.

²Department of Internal Medicine, Stanley Medical College and Government Hospital, Royapuram, Chennai, India.

ABSTRACT

Scrub typhus is a mite-borne rickettsial zoonosis caused by *Orientia tsutsugamushi*. We report a case of scrub typhus with Acute Respiratory Distress Syndrome (ARDS) and Diabetic ketoacidosis (DKA) in an adult diabetic male in Chennai. The diagnosis was made initially by serology and subsequently confirmed by detection of the 56 kDa gene. *J Microbiol Infect Dis* 2017; 7(3):164-166

Keywords: Scrub typhus, diabetic ketoacidosis, Acute Respiratory Distress Syndrome, nested PCR

INTRODUCTION

Scrub typhus is an acute febrile illness caused by *Orientia tsutsugamushi* following the bite of infected larval mite. Approximately one million cases are known to occur annually in Asia-Pacific region. Diagnosis is often difficult since most of the clinical manifestations, such as fever, headache, nausea, myalgia, abdominal pain, lymphadenopathy, and maculopapular rash are nonspecific [1]. Eschar formation may not be seen in all cases. Complications of scrub typhus such as jaundice, renal failure, pneumonitis, ARDS, septic shock, myocarditis, and meningoencephalitis usually develop after the first week of illness. [2]. Rapid serological tests have been used, but their use in early diagnosis is not clear [3]. We report a case of scrub typhus diagnosed using nested PCR (nPCR) to amplify the 56 kDa type-specific antigen gene of *Orientia tsutsugamushi*.

CASE

A 43-year-old male with type II diabetes mellitus from Ponneri, Thiruvallur District, North Chennai was referred to Stanley Medical College & Governmental Hospital. The patient presented with complaints of intermittent high-grade fever for 10 days associated with vomiting, myalgia,

headache, body pain and burning micturition. On physical examination, no eschar formation or skin rash was observed.

Laboratory results showed hemoglobin 12.9 g/dl, platelet count 1,00,000 cells/ μ L, mean corpuscular volume (MCV) 83 fL, mean corpuscular hemoglobin (MCH) 26.5pg, mean corpuscular hemoglobin concentration (MCHC) 32.0 g/dl, sodium 128 mEq/L, potassium 4.2 mEq/L, chlorine 98mEq/L, urea 22 mg/dL and creatinine 0.9 mg/dL. The patient was diagnosed with diabetic ketoacidosis. Serological tests for enteric fever and dengue were negative. The chest radiograph was suggestive of ARDS.

Abdominal ultrasonography showed hepatosplenomegaly with normal gallbladder, pancreas and kidney. Blood sample was collected from the patient with informed consent, serum was separated and serological tests for scrub typhus, such as ICT and IgM ELISA were performed. The EDTA blood samples were subjected to DNA extraction using the QIAamp DNA Mini Kit (Qiagen, GmbH, Germany) according to manufacturer's instructions. The purified DNA samples were stored at -20°C . The 626 bp segment gene encoding the 56 kDa protein antigen of *Orientia tsutsugamushi* was amplified by nPCR using a modified protocol of

Correspondence: Dr. Thangam Menon, Department of Microbiology, Dr. A. L. Mudaliar PG Institute of Basic Medical Sciences, University of Madras, Taramani, Chennai, Tamil Nadu, India, E-mail: thangam56@gmail.com

Received: 12 February 2017 Accepted: 17 July 2017

Copyright © JMID / Journal of Microbiology and Infectious Diseases 2017, All rights reserved

Izzard et al. [4] The reaction mixture for first and second round PCR, was made up of 2.5 µl of 10X Taq buffer, 0.8 µl of 10 mM dNTP's, 0.5 µl of 25 mM MgCl₂, 0.5 µl of 10 picomoles forward and reverse primers, 1.5 units Taq DNA polymerase, and 1 µl of DNA template with volume adjusted to 25 µl with Milli-Q water. The cycling conditions for the first round of nested nPCR were 95°C for 3 min, followed by 30 cycles of 94°C for 30 s, 55°C for 1.5 min, 72°C for 2 min, and a final extension at 72°C for 5 min. First round products (~800 bp) were considered template for second round with initial denaturation at 95°C for 3 min, followed by 25 cycles of 94°C for 30 s, 57°C for 1 min, 72°C for 1 min, and final extension at 72°C for 5 min. The PCR products were visualized using the gel documentation system (Carestream Gel Logic 212 Pro, USA) and amplification of 626 bp by nPCR was considered positive (Fig. 1).

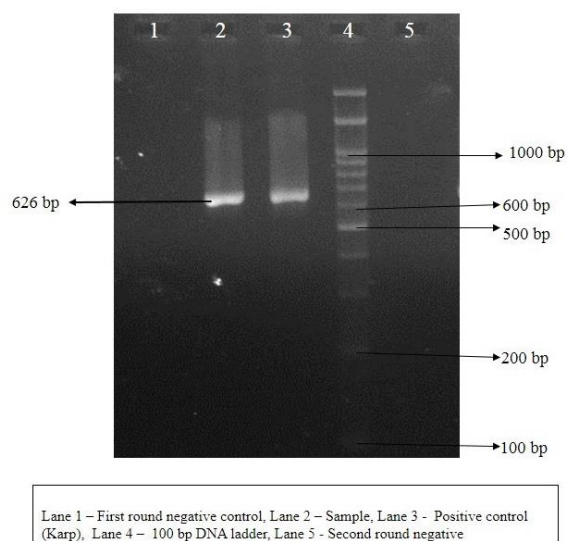


Figure 1. Gel picture of nPCR targeting 56kDa protein antigen gene.

The positive sample was sequenced using Big Dye Terminator v3.1 kit (ABI 3730xl, Xcelris Genomics, India) and analyzed using BioEdit software. A BLAST search (<http://www.ncbi.nlm.nih.gov/BLAST>) of the amplified 56 kDa gene sequence was performed, which showed 99% homology with *Orientia tsutsugamushi* (GenBank accession number KT329432). Sequence details are given in Table 1. The patient was diagnosed as a case of scrub typhus on the basis of positive serology (ICT and IgM ELISA) and confirmed by nPCR.

He was treated with intravenous ceftriaxone (1g, twice a day) and doxycycline (100mg, twice a day) for 7 days. He responded to the treatment and was discharged from the hospital after a week.

Table 1. Sequence details of the isolate

OTS66	TTATTAGCATTGATAATGCAGCAAGCCC AACTACCAAATGCCTCCAATGATCATGGT TATGTATCGCAAAATTTGCAGGCTGCTGT GCTCGCTGCGGTGGATTCCCAGCAGGAT TAGGGTTACCTGTGGAATATTTAACAAT ATCGGATTATAACCATAGGCCCATAGG ATTATTAGGATCTTTACCCTATAGTCAAT ACCAGCACAAATCTTTAACCAAGCGATCC TAGCTGCAGCAGCTGTTCATCATTAAGC GCAGGATTCCGAGCTTGCGCTTGCGCCT GAGGTATGTTACAAATATCAATCCCAAAG TCACGATCAGCTATACTTATAGGCATTAT AGTAGGCTGAGGAGGTGTAAGTTTAAAC CGCTTACGTATAGGAGCATCTGTCCAC CTCCAGAATCTGCCTTTGTCTTACCTCCA GAATCTGCCTTAACTTTACCTTCTTCAAC CTGAGCAGTTATATTGTAAGGTACATAA CCCCCAGCTCTGCTCTAAACCTGGAGC GATTGTCATACCTGCAGCTAATGTACCAC CAAATGGCATCGAGGTTGTTAATGGCAAT TGTTTTTGGCCATCAGCATCAGCTGGATC CAAGCGAGCAGATTCTACACCAGTAA
-------	--

DISCUSSION

Scrub typhus is an acute febrile illness caused by the obligate intracellular organism *Orientia tsutsugamushi*. It is transmitted by trombiculid mites, which feed on human tissue fluid and is endemic to Southeast Asia and Northern Australia [1]. Epidemics of scrub typhus have been reported from various parts of North, East, and South India [5]. Common clinical manifestations of scrub typhus include the unexpected onset of fever, sore throat, cough, myalgia, headache, rash and the eschar formation [6]. Scrub typhus is under-diagnosed in India due to its nonspecific presentations, low index of suspicion and the lack of confirmatory diagnostic tests [7]. The introduction of advanced diagnostic methods would improve detection of the disease [8]. In the present case, the patient presented with high-grade fever for 10 days with myalgia, vomiting, burning micturition, headache, and body pain. Though eschar formation is a useful tool in occasional cases, in this patient both eschar formation and the maculopapular rash were not observed. Diabetic ketoacidosis is a serious life-

threatening complication of diabetes mellitus and is characterized by hyperglycemia and increased ketone bodies. DKA is caused by insulin insufficiency, which leads to decreased glucose utilization, and increased gluconeogenesis and ketone body production through elevated counter-regulatory hormones, including catecholamines, glucagon, and cortisol [9]. ARDS is a rare complication of scrub typhus but there is an increasing incidence of ARDS in scrub typhus in the recent years [10]. A report in 2014 from Maharashtra described two cases of scrub typhus complicated by ARDS, leading to death due to multiorgan failure [11]. The clinical manifestations, along with serological tests (ICT and IgM ELISA) and molecular tests (nPCR) in our patient was strong evidence for the diagnosis of scrub typhus. To the best of our knowledge, this is the first case of scrub typhus complicated by DKA and ARDS to be reported from Chennai. Institutional Human ethics clearance was obtained for the above study (UM/IHEC I 04-2014-I)

In conclusion, Scrub typhus is an important public health problem. Variations in the clinical presentation could complicate diagnosis. Serological and molecular tests are useful to confirm the disease.

ACKNOWLEDGMENTS

We acknowledge Dr. Daniel H Paris, Head of Rickettsiology, Mahidol Oxford Research Unit, Thailand, who provided us the standard strains for this study. We also acknowledge Dr. Priyatharcini, for providing the clinical sample.

Declaration of conflicting interests

The authors declare that they have no conflict of interest.

Financial disclosure

We acknowledge the financial assistance provided by Indian Council of Medical Research (ICMR).

REFERENCES

1. Ha NY, Kim Y, Choi JH, et al. Detection of Antibodies against *Orientia tsutsugamushi* Sca Proteins in Scrub Typhus Patients and Genetic Variation of sca Genes of Different Strains. *Clin Vaccine Immunol* 2012; 19(9):1442-1451.
2. Krishna PV, Chepuri VR, Kanumuri S, Yarram R and Yadalla S. A rare case of scrub typhus masquerading as breast abscess. *Nitte Univ J Healt Sci* 2014; 4:107-9.
3. Sonthayanon P, Chierakul W, Wuthiekanun V, et al. Rapid Diagnosis of Scrub typhus in rural Thailand using Polymerase Chain Reaction. *Am. J. Trop. Med Hyg* 2006; 75(6):1099-1002.
4. Izzard L, Fuller A, Blacksell SD, et al. Isolation of a Novel *Orientia* Species (*O. chuto* sp. nov.) from a Patient Infected in Dubai. *J Clin Microbiol* 2010; 48(12):4404-4409.
5. Narvencar KP, Rodrigues S, Nevrekar RP, et al. Scrub typhus in patients reporting with acute febrile illness at a tertiary health care institution in Goa. *Indian J Med Res* 2012; 136:1020-1024.
6. Goswami D, Hing A, Das A, Lyngdoh M. Scrub typhus complicated by acute respiratory distress syndrome and acute liver failure: a case report from Northeast India. *Int J Infect Dis* 2013; 17(8):644-645.
7. Sinha P, Gupta S, Dawra R, Rijhawan P. Recent outbreak of scrub typhus in North Western part of India. *Indian J Med Microbiol* 2014; 32:247-250.
8. Isaac R, Varghese GM, Mathai E, Manjula J, Joseph I. Scrub typhus: Prevalence and diagnostic issues in rural Southern India. *India Clin Infect Dis* 2004;39:1395-1396.
9. Kanemasa Y, Hamamoto Y, Iwasaki Y, et al. A Case of Diabetic Ketoacidosis Associated with Guillain- Barré Syndrome. *Intern Med* 2011; 50(19):2201-2205.
10. Singh RBS, Vengadakrishnan K, Damodharan J. A Case Report of Scrub Typhus with ARDS in Pregnancy. *Int J Emerg Trends Sci Technol* 2015; 14(1):14-16
11. Saxena A, Khiangte B, Tiewsoh I. Scrub Typhus Complicated by Acute Respiratory Distress Syndrome and Multiorgan Failure; an Unrecognized Alarming Entity in Central India: A Report of Two Cases. *J Family Med Prim Care* 2014; 3(1):80-83.