

## PAPER DETAILS

TITLE: A Rare Clinical Presentation of HIV Infection

AUTHORS: Rahul MAHAJAN,Abhishek JUNEJA,S ANAND

PAGES: 181-182

ORIGINAL PDF URL: <https://dergipark.org.tr/tr/download/article-file/1274321>

LETTER TO EDITOR

## A Rare Clinical Presentation of HIV Infection

Rahul Mahajan, Abhishek Juneja, K. S. Anand

*Department of Neurology, Dr RML Hospital, Delhi, India*

Sir,

We report a case of a 32-year-old female who presented with neck pain followed by weakness of all four limbs for five days. She had neck pain with electric shock like sensation running down the spine on flexing the neck. She developed weakness of all four limbs over few hours. There was no history of preceding fever, headache, seizure or trauma. There was no significant past or family history. She did not have history of high-risk sexual behavior or injection drug use. On neurological examination, her higher mental functions and cranial nerves were normal. Motor system examination revealed hypertonia in bilateral lower limbs. She had grade 3 (Medical Research Council) power in bilateral upper limbs while grade 2 power in bilateral lower limbs. Deep tendon reflexes were brisk. Plantar response was extensor bilaterally. Sensory examination revealed 50% loss of touch and pain sensation below neck region with impaired vibration and proprioception sense. Her routine blood investigations were normal. HIV 1 (Enzyme linked immunosorbent assay) test was reactive while tests for hepatitis B and C viruses were negative.

HIV viral load was 42,547 copies/mm<sup>3</sup>. Chest radiograph and ultrasound abdomen were normal. Magnetic resonance imaging of cervical spine showed intramedullary T2 hyper-intensity extending from cervicomedullary junction to fifth cervical vertebra suggestive of longitudinally extensive transverse myelitis (LETM). (Fig-1,2) Cerebrospinal fluid examination (CSF) showed mild protein elevation (68 mg/dl), two mononuclear cells/mm<sup>3</sup>, and normal sugar level. CSF Gram, Ziehl-Neelsen and India ink stain were negative and culture was sterile. CSF nuclear amplification tests for viruses (Herpes simplex, Varicella zoster, Epstein Barr, and Cytomegalovirus), and Mycobacterium

tuberculosis were negative. Cytology was negative for malignant cells. No oligoclonal bands were detected. Serum antinuclear antibody, c-anca, p-anca, angiotensin converting enzyme and VDRL (Venereal Disease Research Laboratory) tests were negative, so was test for cryptococcal antigen. CD4 count was 178/mm<sup>3</sup>, with CD4/CD8 ratio of 0.7. Neuromyelitis optica (NMO) IgG antibody titers were negative. Visual and brainstem evoked potentials were normal. She was a newly diagnosed case of treatment naive HIV infection with LETM. Patient was started on antiretroviral therapy (ART) with intravenous methylprednisolone pulse therapy (1 gm/day) for five days. Patient improved significantly over next few weeks. She was able to walk with minimal support. Patient was discharged to follow up in ART clinic.

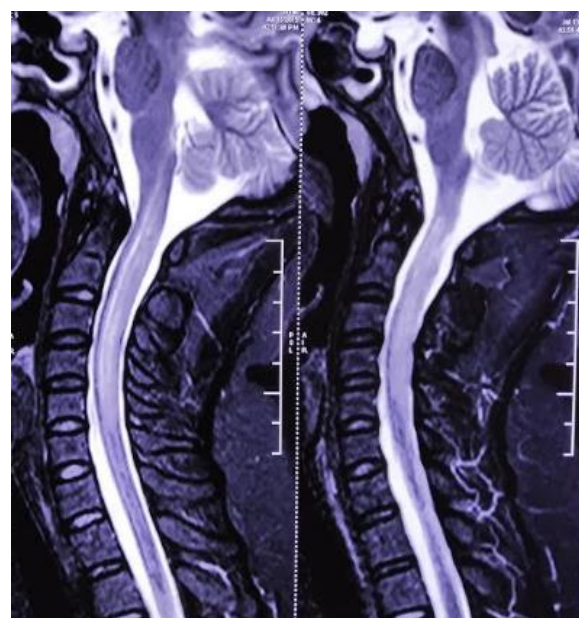


Fig 1. MRI spine T2 sagittal sections showing intramedullary hyperintensity extending from cervicomedullary junction to fifth cervical vertebra.

**Correspondence:** Dr. Abhishek Juneja, Dept of Neurology, Dr RML Hospital, A-15, Old Quarters, Ramesh Nagar, Delhi, India  
E-mail: drabhishekjuneja@gmail.com

Received: 25 November 2019 Accepted: 20 July 2020

Copyright © JMID / Journal of Microbiology and Infectious Diseases 2020, All rights reserved

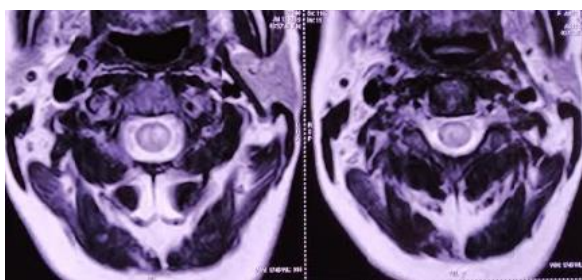


Fig 2. MRI spine T2 axial sections showing central intramedullary hyperintensity.

HIV infection can lead to multiple neurologic complications affecting both central and peripheral nervous system. Neurologic complications can be due to HIV infection per se, or opportunistic infections due to immunodeficiency. [1]. Direct CNS involvement can present as HIV encephalitis, HIV leukoencephalopathy, or vacuolar myelopathy. CNS opportunistic infections include toxoplasmosis, cryptococcosis, tuberculosis and CMV encephalomyelitis. [2]. Rarely, acute or subacute transverse myelitis may be the presenting manifestation of HIV. [3,4]. Anti-retroviral therapy with steroids is recommended in such cases. HIV infection presenting as longitudinally extensive transverse myelitis is even rarer. In our case, although HIV cannot be conclusively shown to be the causative agent but extensive laboratory evaluation did not find an alternative cause. Hence, we treated the patient considering the possibility of HIV myelitis presenting in longitudinally extensive form.

**Correspondence:** Dr. Abhishek Juneja, Dept of Neurology, Dr RML Hospital, A-15, Old Quarters, Ramesh Nagar, Delhi, India

E-mail: drabhishekjuneja@gmail.com

**Conflict of interest:** The authors declare no personal or financial conflict of interest.

**Financial Disclosure:** No financial support was received

## REFERENCES

1. McArthur JC, Brew BJ, Nath A. Neurological complications of HIV infection. *Lancet Neurol* 2005; 14(9):543–555.
2. Trillo-Pazos G, Everall IP. From human immunodeficiency virus (HIV) infection of the brain to dementia. *Genitourin Med* 1997; 14(5):343–347.

3. Denning DW, Anderson J, Rudge P, Smith H. Acute myelopathy associated with primary infection with human immunodeficiency virus. *Br Med J* 1987; 14(6565):143–144.

4. Hamada Y, Watanabe K, Aoki T, et al. Primary HIV infection with acute transverse myelitis. *Intern Med* 2011; 14(15):1615–1617.