

## PAPER DETAILS

TITLE: Gastrointestinal mucormycosis causing an acute intestinal obstruction in neonate patient

AUTHORS: Recep Tekin,Özben Yalçın,Sirin Menekse Yilmaz,Yilmaz Arayici

PAGES: 35-37

ORIGINAL PDF URL: <https://dergipark.org.tr/tr/download/article-file/105040>

**CASE REPORT**

## **Gastrointestinal mucormycosis causing an acute intestinal obstruction in neonate patient**

**Recep Tekin<sup>1</sup>, Özben Yalçın<sup>2</sup>, Şirin Menekşe Yılmaz<sup>1</sup>, Yılmaz Arayıcı<sup>3</sup>**

<sup>1</sup>Children's Hospital, Department of Infectious Diseases and Clinical Microbiology, Diyarbakır, Turkey

<sup>2</sup>Children's Hospital, Department of Pathology, Diyarbakır, Turkey

<sup>3</sup>Dicle University, Medical Faculty, Department of Pediatric Surgery, Diyarbakır, Turkey

### **ABSTRACT**

Neonatal gastrointestinal mucormycosis is a rare, usually fatal, opportunistic fungal infection, which is difficult to diagnose early or preoperatively. Clinically, it may be indistinguishable from the neonatal necrotizing enterocolitis and the diagnosis is usually made on autopsy or histopathology of excised surgical specimen. The treatment should include radical surgical debridement, application of systemic high doses amphotericin B and control of the underlying disease. Herein, we presented a case of neonatal gastrointestinal mucormycosis in a 25 days-old infant. A twenty-five-days-old neonate admitted with the preliminary diagnosis of acute intestinal obstruction that was diagnosed as gastrointestinal mucormycosis and was treated with liposomal amphotericin B. *J Microbiol Infect Dis* 2011;1(1):35-37.

**Key words:** Amphotericin B, gastrointestinal mucormycosis, neonate

## **Yenidoğanda akut bağırsak tıkanıklığına neden olan gastrointestinal mukormikoz**

### **ÖZET**

Neonatal gastrointestinal mukormikoz nadir görülen, genellikle fatal seyreden, erken ya da preoperatif teşhisi zor fırsatçı bir fungal enfeksiyondur. Klinik olarak nekrotizan enterokolit ile karışabilir, teşhis genellikle otopsi veya cerrahi materyalin histopatolojik incelenmesi ile konulur. Tedavide agresif cerrahi debridman yapılmalı, altta yatan hastalık düzeltilmeli ve sistemik yüksek doz amfoterisin B uygulanmalıdır. Biz burada yirmi beş günlük yeni doğan gastrointestinal mukormikoz olgusunu sunduk. Akut bağırsak tıkanıklığı ön tanısı ile başvuran yirmi beş günlük yenidoğana, gastrointestinal mukormikozis tanısı konuldu ve lipozomal amfoterisin B ile tedavi edildi.

**Anahtar kelimeler:** Amfoterisin B, gastrointestinal mukormikoz, yenidoğan

### **INTRODUCTION**

Mucormycosis is a rare opportunistic invasive fungal infection caused by Mucorales of class Zygomycetes that occurs in immunocompromised human hosts.<sup>1</sup> Mucormycosis of the gastrointestinal tract is rare. Although a histological diagnosis of the intestinal zygomycosis may be possible by means of computerised tomography guided biopsy of the abnormal mucosa, it is in most cases extremely difficult to obtain.<sup>2</sup> Here we present a rare case of a female neonate with gastrointestinal mucormycosis in an immunocompetent neonate.

### **CASE REPORT**

A female neonate with birth weight of 3.050 g was born to a 21-year-old multigravida at full term through normal vaginal delivery. There were no identifiable maternal risk factors. She was admitted to our hospital 25 days of age with complaints of abdominal distention and vomiting. Her systemic examination was normal except for diffuse abdominal tenderness. Results of laboratory investigations revealed a white blood cell count of 14,000/mm<sup>3</sup>, platelet count of 281,000/cm<sup>3</sup>, serum hemoglobin 11.9 g/dl, aspartate transaminase 61 IU/L, alanine transaminase 102 IU/L, urea nitrogen 65 mg/dl, creatinine 0.6 mg/dl, serum sodium 129 mEq/L, serum potassium 5.1 mEq/L, and C-reactive protein of 101 mg/L (refer-

**Correspondence:** Dr. Recep Tekin

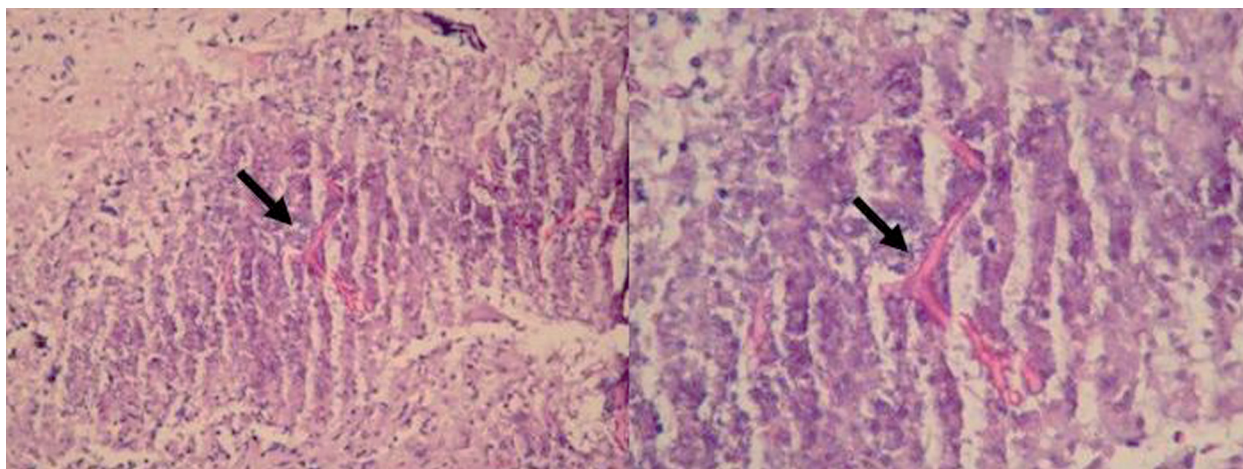
Diyarbakır Çocuk Hastanesi Enfeksiyon Komitesi 21100 Yenisehir, Diyarbakır, Turkey Email: rectek21@hotmail.com

Received: 11.05.2011, Accepted: 30.06.2011

Copyright © Journal of Microbiology and Infectious Diseases 2011, All rights reserved

ence: 0 to 5 mg/L). Her microbiological evaluation for bacteria (blood culture and serology), HIV and hepatitis B and hepatitis C serology were negative. Dilated bowel loops is the view taken in the patient's abdominal ultrasonography, abdominal viewed in the free-mai. Clinical and radiological ileus was thought in patients and the infant underwent an operation. The adhesion was observed in the abdomen and 30 cm ileal resection was performed in the areas of necrosis seen in the ileum of the patient. The affected ileum was resected and a double-barrel ileostomy was performed. Biopsy from the ulcer revealed extensive

necrosis of the gastric mucosa with polymorphonuclear infiltration, hemorrhage and thrombosed blood vessels, and numerous broad aseptate hyaline fungal hyphae branching at right angles suggestive of mucormycosis (Figure 1). The resection margins were free of mucor invasion. The peritoneal fluid culture and the blood culture were negative for microorganisms and fungi. Ileostomy closure was done after 3-week administration of IV liposomal amphotericin B that was well tolerated. The child is thriving well and gaining weight after ileostomy closure.



**Figure 1.** Irregular hyphae is seen as branching at right angle on necrotic ground (H&E, original magnification  $\times 400$ )

## DISCUSSION

Zygomycosis caused by various members of the phycomycetes, such as rhizopus, mucor, and absidia rare invasive fungal infection is most often seen in immunosuppressed patients, particularly during prolonged neutropenia.<sup>3</sup> Mucormycosis of the gastrointestinal tract is rare. It mainly occurs especially in infants or children, who are extremely malnourished. It is thought to arise from ingestion of the fungi. In particular, gastrointestinal mucormycosis (GIM) has been seen in premature neonates, often in association with widespread disseminated disease.<sup>1,4</sup> The stomach, colon, and ileum are the most commonly involved sites and in neonatal the colon is predominantly involved.<sup>5</sup> Although the symptoms are varied and depend on the site affected, nonspecific abdominal pain and distention associated with nausea and vomiting are the most common symptoms. As well as fever and hematochezia may also occur. Because

of these symptoms the patient is often thought to have an intra-abdominal abscess. The certain diagnosis may be made by biopsy of the suspected area during surgery or endoscopy.<sup>6</sup>

Mucorales which hardly show any pathogenicity in normal human host, are present in soil, bread, fruit, and decaying material.<sup>7</sup> Mucormycosis probably had been occurred in our patient due to fed with formula that prepared in non-hygenic conditions sufficiently because of her mother insufficient breast milk.

When mucormycosis is rapidly progressive antifungal therapy alone is often inadequate to control the infection. Surgery is necessary due to the massive amount of tissue necrosis occurring during mucormycosis, which may not be prevented by killing the organism. Prompt tissue diagnosis, surgical debridement, and amphotericin B treatment are important for better survival.<sup>8</sup> The amphotericin B treatment was also successful for our patient.

The risk factors of mucormycosis are low birth weight (LBW), neonates having immature immune system and fragile skin barriers. They are usually treated long in neonatal intensive care units and are administered broad-spectrum intravenous antibiotics and steroids that affect healthy gastrointestinal flora. Interventions such as oro-gastric tube placement, endotracheal intubation, and indomethacin therapy are speculated to increase the risk of developing gastrointestinal mucormycosis by causing mucosal injury.<sup>7,9</sup> Neonates, who survived or died of the disease, had detailed histological examination therefore the incidence of neonatal GIM might be underestimated. Neonates survived after GIM was rare. The first infant reported by Michalak<sup>8</sup> was a 32-week gestation infant with hyaline membrane disease presenting with abdominal distension, stomach perforations, and gangrenous appendix; the second infant reported by Kecskes<sup>10</sup> was a 29-week gestation infant with hyaline membrane disease presenting with abdominal distension and gangrenous colon. Both cases were diagnosed by tissue histology, and survived after gut resection and amphotericin B treatment.<sup>8,10</sup> Our patient was neither premature nor of LBW. Although our patient was an immunocompetent child, occurrence of intestinal mucormycosis is very interesting. These three survivors presented with abdominal distension mimicking NEC. Our patient presented with abdominal distention and vomiting mimicking ileus.

The high mortality results from lack of clinical suspicion coupled with inadequate surgery and

antifungal therapy. To conclude, GIM should be considered in neonates with a clinical picture of ileus and NEC, who not breastfeeding, on enteral feedings and treatment with multiple antibiotics and prolonged neutropenia. Aggressive early surgery followed by intravenous amphotericin B is the mainstay of treatment.

## REFERENCES

1. Agarwal K, Sharma M, Singh S, et al. Antemortem diagnosis of gastrointestinal mucormycosis in neonates: Report of two cases and review of literature. *Indian J Pathol Microbiol* 2006;49:430–432.
2. Lee JH, Ha HK, Yoo E, et al. CT and sonographically guided biopsy in a patient with intestinal mucormycosis. *AJR Am J Roentgenol* 2000;175:129–231.
3. Pagano L, Offidani M, Fianchi L, et al. Mucormycosis in hematologic patients *Haematologica* 2004;89:207–214.
4. Kline MW. Mucormycosis in children: review of the literature and report of cases. *Pediatr Infect Dis* 1985;4:672–676.
5. Dhingra KK, Mandal S, Khurana N. Unsuspected intestinal mucormycosis in a neonate presenting as necrotizing enterocolitis (NEC). *Eur J Pediatr Surg* 2008;18:119–120.
6. Maravi-Poma E, Rodriguez-Tudela JL, de Jalon JG, et al. Outbreak of gastric mucormycosis associated with the use of wooden tongue depressors in critically ill patients. *Intensive Care Med* 2004;30:724–728.
7. Sarin YK. Intestinal mucormycosis in a neonate: A case report and review. *J Indian Assoc Pediatr Surg* 2010;15:98–100.
8. Ibrahim AS, Spellberg B, Avanesian V, Fu Y, et al. *Rhizopus oryzae* adheres to, is phagocytosed by, and damages endothelial cells in vitro. *Infect Immun* 2005;73:778–783.
9. Reimund E, Ramos A. Disseminated neonatal gastrointestinal mucormycosis: A case report and review of the literature. *Pediatr Pathol* 1994;14:385–389.
10. Michalak DM, Cooney DR, Rhodes KH, et al. Gastrointestinal mucormycosis in infants and children: a cause of gangrenous intestinal cellulitis and perforation. *J Pediatr Surg* 1980;15:320–324.