

## PAPER DETAILS

TITLE: Tek Koroner Arteri Olan Bir Hastada Akut Koroner Sendrom

AUTHORS: M Yunus EMIROGLU,Hidayet KAYANÇIÇEK,Mustafa AKÇAKOYUN,Selçuk

PALA,Ramazan KARGİN,Ali Metin Esen

PAGES: 25-26

ORIGINAL PDF URL: <https://dergipark.org.tr/tr/download/article-file/106887>

# Single Coronary Artery In Patient with Acute Coronary Syndrome

M.Yunus Emiroglu MD<sup>1</sup>, Hidayet Kayañççek MD<sup>1</sup>, Mustafa Akçakoyun MD<sup>2</sup>, Selçuk Pala MD<sup>2</sup>, Ramazan Kargin MD<sup>2</sup>, Ali Metin Esen MD<sup>2</sup>

<sup>1</sup>Van Yüksek İhtisas Hospital, Department of Cardiology, Van, Turkey

<sup>2</sup>Kartal Kosuyolu Heart and Education Hospital, İstanbul, Turkey

## ABSTRACT

It is a very rare anomaly in which all three coronary arteries arise from single ostium. The incidence of single coronary artery ranges from 0,02 % to 0,04 % (1) In this anomaly, while some types of this anomaly has no clinical importance, some other types may cause ischaemia and sudden death. In this case report, we present a hypertensive patient who has acute coronary syndrome with single coronary arising from right sinus of Valsalva.

**Key Words:** Single Coronary Arter, Acute Coronary Syndrome.

## ÖZET

### *Tek Koroner Arteri Olan Bir Hastada Akut Koroner Sendrom*

Tüm koroner arterlerin tek ostiumdan çıkması oldukça nadir bir koroner anomalidir. Bu anomaliye %0,02-0,04 oranında rastlanmaktadır. Bu anomalilerin bazı tipleri klinik açıdan önemsizken, bir kısmı da iskemi ve ani ölüme sebep olabilmektedir. Bu vaka sunumunda akut koroner sendromlu hipertansif bir hastada sağ sinus valsalvadan çıkan tek koroner arter anomalisi bildirilmiştir.

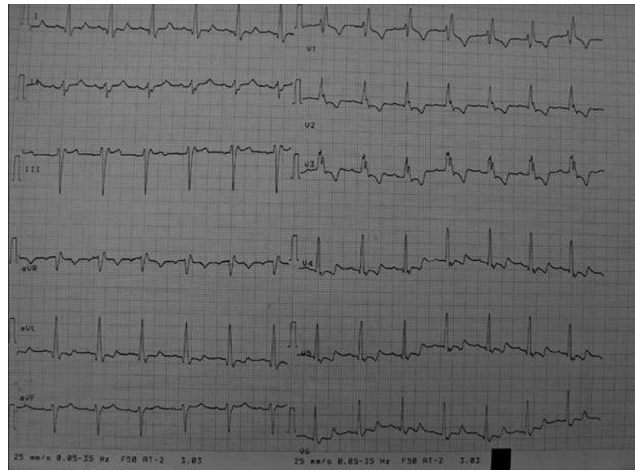**Anahtar Kelimeler:** Tek Koroner Arter Anomalisi, Akut Koroner Sendrom.

## CASE REPORT

65 years old woman presented to emergency clinic with the complaint of chest pain in crushing nature. She had a history of hypertension and hyperlipidemia which were first diagnosed about five years ago. Blood pressure (BP) was measured 200/110 mmHg. Pulse rate was 86/min. Chest XR showed no abnormality. In ECG, rythm was sinus and there was an old right bundle branch block (RBBB) (ECG which was taken two years ago also showed RBBB pattern). Down slope ST segment depressions were seen in leads V16 and biphasic T waves were seen in leads V46 (Fig 1). Troponin I was elevated.

Patient was taken to coronary intensive care unit and routine antithrombotic and antiischemic drugs were started. Two hours later, BP reduced to 150/90 mmHg and chest pain relieved.

Echocardiography which was performed after relief of patient showed grade 1 diastolic dysfunction. Left



**Figure 1:** Electrocardiogram showed RBBB pattern and down slope ST segment depressions in leads DI, aVL and V1-6.

## Address for Reprints

Selçuk PALA MD,

Kartal Koşuyolu Heart and Education Hospital, İstanbul, Turkey

Telephone: 0216 488 35 59 Fax: 0216 459 63 21 e-mail: selcukpalamd@yahoo.com

ventricular segmentary motions and global left ventricular ejection fraction were normal. In angiography, we saw all three coronary arteries arise from right sinus valsalva via single ostium and after a short course, single artery was separated into a dominant right coronary artery (RCA) and left main coronary artery (LMCA). Left main coronary artery traversed the aorta and pulmonary artery anteriorly and then ramified as circumflex (Cx) and left anterior descending artery (LAD) (Fig. 2).

In aortography, no other coronary exit site was found either in left sinus Valsalva or in any other ectopic site.

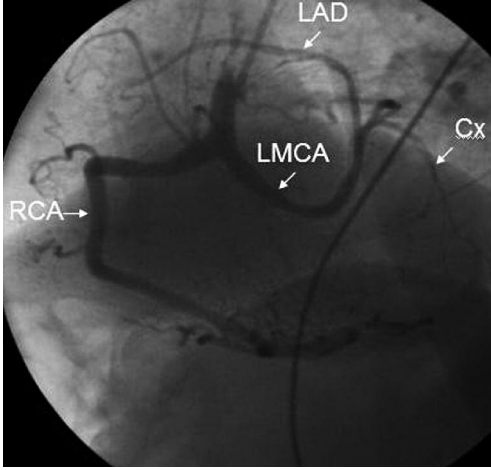


Figure 2: Single coronary artery arising from right sinus of Valsalva in left anterior oblique view.

## DISCUSSION

Single coronary arteries are anomalies in which all coronaries arise from one ostium.(3) There are additional anomalies in 40% of cases. In various angiographic series, the incidence reported as 0,02%0,04% (1). In single coronary artery cases, because there aren't alternative collateral circulation, small lesions which are developed at the orifice affect large myocardial regions and may cause severe ischemia and create important hemodynamic result.(5)

Additionally, when single coronary artery arises from right sinus Valsalva and traverses the root of the heart between aorta and pulmonary artery, it may cause myocardial ischemia, infarction or even sudden death, especially after exercise(6). In our case, uncontrolled hypertension increased left ventricular end diastolic pressure and substantially disturbed subendocardial blood flow. Normalization of symptoms and ST depressions after reducing BP support this opinion. The treatment was started to control BP and to lower cholesterol value to optimal level (LDLC below 70 mg/dl) and precautions were taken to stabilize atherosclerotic plaques. It was

also explained to patient that severe decrease in BP might diminish myocardial blood flow which was severely dependent to one coronary ostium and might also cause myocardial ischemia. It was advised her to monitor BP strictly and not to allow BP to fall under normal values. As a result, single coronary arteries are very rare anomalies and may cause severe ischemia and even sudden death, even in the absence of coronary lesions.

## REFERENCES

1. Shirani J, Roberts WC. Solitary coronary ostium in the aorta in the absence of the major congenital cardiovascular anomalies. *J Am Coll Cardiol* 1993;2:137143.
2. Lipton MJ, Barry WH, Obrez I, Silverman JF, Wexler L. Isolated single coronary artery: diagnosis, angiographic classification, and clinical significance. *Radiology* 1979;130:3947.
3. Angelini, P, Villason, S, AV, Diez, JG: Normal and anomalous coronary arteries in humans. In Angelini P Editör. *Coronary artery anomalies*. Baltimore MA. Lippincott Williams & Wilkins. 1999, pp 5354.
4. Sharbaugh, AH, White, RS: Single coronary artery. Analysis of the anatomic variation, clinical importance and report of five cases. *JAMA* 1974;230:243-6.
5. Spring DA, Thomsen JH. Severe atherosclerosis in the "single coronary artery". Report a previously undescribed pattern. *Am J Cardiol* 1973;31:662-5.
6. Schwarz ER, Hager PK, Uebis R, Hanrath P, Klues HG. Myocardial ischaemia in a case of a solitary coronary ostium in the right aortic sinus with retroaortic course of the left coronary artery: documentation of the underlying pathophysiological mechanisms of ischaemia by intra-coronary Doppler and pressure measurements. *Heart* 1998;80:307-11.