

## PAPER DETAILS

TITLE: Dev mitral kapak vejetasyonu

AUTHORS: Elif TÜKENMEZ TIGEN,Huseyin BILGIN,Beste OZBEN,Kursat TIGEN,Buket ERTÜRK  
SENGEL

PAGES: 213-215

ORIGINAL PDF URL: <https://dergipark.org.tr/tr/download/article-file/2377>

# Giant mitral valve vegetation

## Dev mitral kapak vejetasyonu

Elif TÜKENMEZ TİGEN, Hüseyin BİLGİN, Beste OZBEN, Kursat TİGEN, Buket ERTÜRK SENGEL

### ABSTRACT

We present a case of giant mitral valve vegetation in a 66-year-old woman whose clinical status deteriorated rapidly without allowing time for surgery. She died due to a septic embolism and multi-organ failure. Our aim is to stress that the risk of embolic complications is high in cases of large vegetations. The mortality rates are high and these patients should be managed immediately.

**Keywords:** Giant vegetation, Infective endocarditis, Septic embolism

### ÖZET

Biz burada klinik durumu cerrahi müdahaleye fırsat vermeden kötüleşen ve septik emboli ve çoklu organ yetmezliğine bağlı ölen 66 yaşında mitral kapakta dev vejetasyonu olan bayan hastayı sunuyoruz. Amacımız büyük vejetasyonları olan vakalarda embolik komplikasyon riskinin ve mortalite oranlarının yüksek olduğunu, çok hızlı müdahale edilmesi gerektiğini vurgulamaktır.

**Anahtar Kelimeler:** Dev vejetasyon, Enfektif endokardit, Septik emboli

### Introduction

Infective endocarditis (IE) is the infection of the inner endothelial surface of the heart (including the native heart valves as well as prosthetic valves) with an incidence of 1.9-6.2/100000 [1]. IE may present as a rapidly progressive acute infection or may manifest itself as a subacute or chronic disease. Clinical signs and symptoms include fever, malaise, chills, anorexia and weight loss. A cardiac murmur is present in 85% of patients. The diagnosis is based on physical and echocardiographic examinations. Transthoracic echocardiography has a sensitivity of 40-63% while transoesophageal echocardiography has a sensitivity of 90-100% [2]. The Duke criteria which rely on the clinical, echocardiographic and microbiological findings are useful to establish a diagnosis of IE with a high sensitivity and specificity (generally about 80%) [3]. Some recent changes [4] have been made to these criteria taking into consideration Q-fever (a zoonoses occurring all over the world and caused by *Coxiella burnetii*), and also due to an increase in the prevalence of staphylococcal infections and the widespread use of transoesophageal echocardiography. Currently, the modified Duke criteria [5] have been used for the diagnosis.

In this article, we present an example of giant mitral valve vegetation complicated by a cerebrovascular embolism.

### Case Report

A 66-year-old diabetic female patient was admitted to the emergency department with complaints of fever, fatigue, dizziness, and a speech disorder. She had been symptomatic for 10 days and was at first admitted to another hospital with these complaints. The patient's general condition deteriorated despite antibiotic treatment and she was transferred to our hospital. At the emergency unit her blood

Elif Tükenmez Tigen (✉), Hüseyin Bilgin, Buket Ertürk Sengel  
Department of Infectious Diseases and Clinical Microbiology, Marmara University Hospital, Pendik, Istanbul, Turkey  
e-mail: fetukenmez@yahoo.com

Beste Ozben, Kurşat Tigen  
Department of Cardiology, Marmara University Hospital, Pendik, Istanbul, Turkey

Submitted/Gönderilme: 11.04.2014 Accepted/Kabul: 27.07.2014

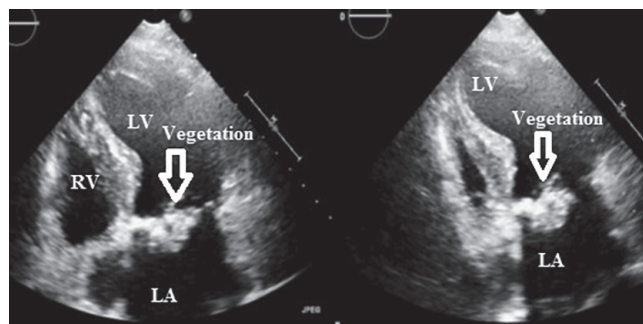
pressure was 90/65 mmHg, her pulse was 100/min and her body temperature was 38.3 °C. She had blurred consciousness. Physical examination revealed normal heart sounds with a systolic murmur of recent onset. The laboratory tests were within normal limits except for the presence of an elevated white blood cell count (24100/mm<sup>3</sup>), as well as increases in the levels of C-reactive protein (84 mg/dL), and amino-terminal pro-B-type natriuretic peptide (8855 pg/ml). There was no history of a prosthetic valve or pacemaker implantation. Relying on the presence of the fever, the cardiac murmur, and the central nervous system signs, infective endocarditis was suspected. Three blood culture sets were obtained from different sites but all were negative.

The patient underwent an echocardiographic examination which revealed a large (2.9x4cm) hyperechoic mobile mass on the mitral valve (Figure 1). Two and three dimensional transoesophageal echocardiography better clarified the mass as a giant vegetation (3.2x4.4 cm) on the posterior leaflet of the mitral valve (Figures 2 and 3). The vegetation was causing severe mitral regurgitation.

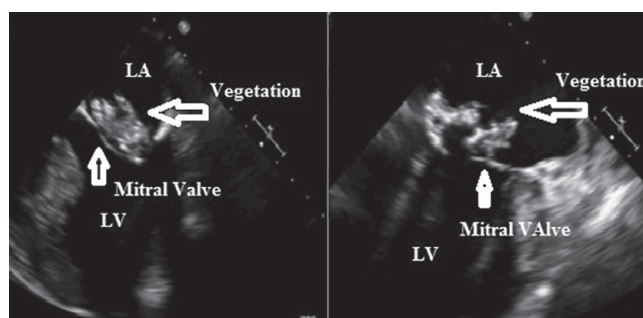
A cranial diffusion magnetic resonance image showed an acute ischemic lesion in the left cerebellar hemisphere which was associated with embolic complication of endocarditis. With these findings, diagnosis was considered as definite IE according to the Duke criteria ([1 major (echocardiographic finding), 3 minor criteria-(fever, vascular phenomenon and serological infection marker)]. Intravenous piperacillin-tazobactam and gentamicin was initiated as antibiotic therapy because of possible sepsis. After that she was transferred to cardiovascular surgeons for early surgery. However, on hemodynamic deterioration she was intubated. The patient's urine output declined and, kidney and liver function tests deteriorated (BUN: 95 mg/dl, creatinine: 7.85 mg/dL, AST: 4785 U/L, ALT: 939U/L). Despite inotropic support, the blood pressure was 70/50 mmHg. The patient was lost due to multi-system organ failure.

## Discussion

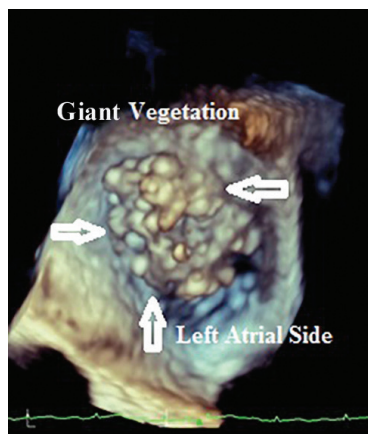
The prognosis of IE depends on four main factors: 1) the patient's characteristics (age above 65, insulin-dependent diabetes mellitus, prosthetic valve endocarditis, concomitant congestive heart failure, chronic renal failure); 2) presence of endocarditis related complications (heart failure, renal failure, stroke, septic shock); 3) associated microorganisms (*S. aureus*, fungi, gram-negative bacilli); 4) and echocardiographic findings (periannular complications, severe mitral or aortic regurgitation, large



**Figure 1.** Apical four and two chamber images of transthoracic echocardiography showing a giant (2.9x4.0 cm) hyperechoic mobile mass on the mitral valve.



**Figure 2 .** Transoesophageal echocardiography (midesophageal two-chamber views) showing the giant vegetation (3.2x4.4 cm) on the posterior mitral leaflet. The mobility and the fibrillary appearance of the mass are predictors of embolization and indication for early surgical approach.



**Figure 3.** Three dimensional transoesophageal echocardiography (surgeons view from left atrial side) showing the vegetation on the mitral valve. A giant vegetation obstructing mitral valve orifice must have interfered with the flow dynamics mimicking mitral stenosis. Fibrillary appearance of the mass is an important predictor of embolic phenomenon in patients with endocarditis

vegetation, pulmonary hypertension, severe prosthetic dysfunction) [6]. The patients with heart failure, periannular complications or *S. aureus* endocarditis have the highest risk of mortality and need surgical treatment during the active phase of the disease [6]. The risk reaches to 79% when all these three factors are present in the same patient [6]. We could not calculate our patient's risk factors

because we did not have positive culture result. But our patient's age, presence of heart failure, septic shock and large vegetation were negative predictive factors for prognosis of IE for our patient. In patients who need surgery urgently, the presence of resistant strains and renal failure are the major risk factors for mortality [7]. The prognosis of the patients who require surgery, but cannot be operated is extremely poor. The main indications for early surgery are heart failure, uncontrolled infection and prevention of embolic events. In-hospital mortality rates range from 9.6% to 26% [8].

Several factors play role in the prognosis of IE. Whether the echocardiographic characteristics of vegetation may predict embolic complications is under debate. While some authors have not found any association between embolic episodes and vegetation size or mobility, others point out that larger vegetations are associated with increased risk of mortality and embolisms [9,10]. Some authors suggest that the causative microorganism is associated with embolic complications rather than the size of the vegetation [11]. The presence of a perivalvular abscess or fistula are also poor prognostic risk factors [12]. Dunne et al. demonstrated that preoperative risk factors associated with mortality that occur at ages over 65 include inotropic requirements, uncontrolled sepsis and cerebral emboli [13].

Costa et al. demonstrated that summation of clinical and echocardiographic scores as the predictors of mortality included: age over 40 years (4 points), New York Heart Association (NYHA) class-IV heart failure or cardiovascular shock (5 points), uncontrolled sepsis (6 points), conduction disorder (5 points), arrhythmia (8 points), a valve with extensive damage or abscess, or a prosthesis (5 points), large and mobile vegetation (4 points) [14]. Mortality rates for scores below 10 were 5.26% and for scores over 20 were 78.9%. According this study our patient was in a group with a mortality rate of 78.9%.

## Conclusion

We have presented a case of infective endocarditis with a giant vegetation on the mitral valve complicated by a cerebrovascular embolism and multi-organ failure. This case stresses that urgent management including removal of a large vegetation must be considered because of the increased risk of mortality or a catastrophic embolism.

## References

1. Van der Meer JT, Thompson J, Valkenburg HA, et al. Epidemiology of bacterial endocarditis in The Netherlands. I. Patient characteristics. *Arch Intern Med* 1992;152:1863-8. doi:10.1001/archinte.1992.00400210087014.
2. Evangelista A, Gonzalez-Alujas MT. Echocardiography in infective endocarditis. *Heart* 2004;90:614-7. doi: 10.1136/hrt.2003.029868
3. Durack DT, Lukes AS, Bright DK. New criteria for diagnosis of infective endocarditis: utilization of specific echocardiographic findings. Duke Endocarditis Service. *Am J Med* 1994; 96:200-9.
4. Fournier PE, Casalta JP, Habib G, Messana T, Raoult D. Modification of the diagnostic criteria proposed by the Duke Endocarditis Service to permit improved diagnosis of Q fever endocarditis. *Am J Med* 1996;100:629-33.
5. Li JS, Sexton DJ, Mick N, et al. Proposed modifications to the Duke criteria for the diagnosis of infective endocarditis. *Clin Infect Dis* 2000;30:633-38.
6. San Roman JA, Lopez J, Vilacosta I, et al. Prognostic stratification of patients with left-sided endocarditis determined at admission. *Am J Med* 2007;120:369.e1-e7. <http://dx.doi.org/10.1016/j.amjmed.2006.05.071>
7. Revilla A, Lopez J, Vilacosta I, et al. Clinical and prognostic profile of patients with infective endocarditis who need urgent surgery. *Eur Heart J* 2007;28:65-71. doi:10.1093/eurheartj/ehl315
8. Hoen B, Alla F, Selton-Suty C, et al. Changing profile of infective endocarditis: results of a 1-year survey in France. *JAMA* 2002;288:75-81. doi:10.1001/jama.288.1.75.
9. De Castro S, Magni G, Beni S, et al. Role of transthoracic and transesophageal echocardiography in predicting embolic events in patients with active infective endocarditis involving native cardiac valves. *Am J Cardiol* 1997;80:1030-4 [http://dx.doi.org/10.1016/S0002-9149\(97\)00598-5](http://dx.doi.org/10.1016/S0002-9149(97)00598-5)
10. Tischler MD, Vaitkus PT. The ability of vegetation size on echocardiography to predict clinical complications: a meta-analysis. *J Am Soc Echocardiogr* 1997;10:562-8. doi: 10.1016/S0894-7317(97)70011-7
11. Cunha BA, Gill MV, Lazar JM. Acute infectious endocarditis: diagnostic and therapeutic approach. *Infect Dis Clin North Am* 1996;10:811-34 doi:10.1016/S0891-5520(05)70328-7
12. Mugge A, Daniel WG. Echocardiographic assessment of vegetations in patients with infective endocarditis: prognostic implications. *Echocardiography*. 1995;12:651-61
13. Dunne B, Marr T, Kim D et al. Infective endocarditis. *Heart Lung Circ* 2014 ;23:628-35. doi: 10.1016/j.hlc.2014.02.010.
14. Costa MA, Wollmann DR Jr, Campos AC, et al. Risk index for death by infective endocarditis: a multivariate logistic model. *Braz J Cardiovasc Surg* 2007; 22: 192-200. doi:10.1590/S0102-76382007000200007