

PAPER DETAILS

TITLE: KORONER ARTER BYPASS CERRAHISINDEN SONRA 73 YASINDAKI BIR ERKEK
HASTADA TOURETTIZM

AUTHORS: Volkan TOPÇUOĞLU,Ayşe RODOPMAN ARMAN,Çağrı YAZGAN,Alper ARMAN,Aylan
GİMİZAL GÖNENTÜR,Duygu SAHİN BİÇER

PAGES: 71-75

ORIGINAL PDF URL: <https://dergipark.org.tr/tr/download/article-file/2449>



CASE REPORT

TOURETTISM IN A 73-YEAR-OLD MAN AFTER CORONARY ARTERY BYPASS SURGERY

Volkan Topçuoğlu¹, Ayşe Rodopman Arman², Çağrı Yazgan³, Alper Arman⁴,
Aylan Gımsal Gönentür¹, Duygu Şahin Biçer⁵

¹Marmara University, School of Medicine, Psychiatry, İstanbul, Türkiye ²Marmara University, School of Medicine, Child Psychiatry, İstanbul, Türkiye ³Ball Memorial Hospital, Muncie, Indiana, USA ⁴Haydarpaşa Numune Education and Research Hospital, Radiology, İstanbul, Türkiye ⁵Foundation of Marmara University, School of Medicine, İstanbul, Türkiye

ABSTRACT

We present a patient who developed motor and vocal tics eight months after coronary artery bypass graft surgery (CABGS). The patient demonstrated a few motor tics like picking, blowing his nose and a vocal tic in the form of shouting. He also described premonitory sensory urges. The significance of our case is the appearance of these tics for the first time after the CABGS in a 73 year-old male patient.

The patient showed ischemic regions in the bilateral basal ganglia in the magnetic resonance imaging (MRI) and his single photon emission tomography (SPECT) examination revealed hypoperfusion in the right caudate nucleus and bilateral frontotemporoparietal cortex, which are the brain regions associated with tic pathogenesis. Although reaching a definitive conclusion is difficult since we do not have preoperative cranial imaging, we suggest that tics might have appeared as a result of a perfusion abnormality he had incurred during the CABGS.

Keywords: Tourettism, Tics, Coronary artery bypass grafting surgery, Elderly

KORONER ARTER BYPASS CERRAHİSİNDEN SONRA 73 YAŞINDAKİ BİR ERKEK HASTADA TOURETTİZM

ÖZET

Koroner arter bypass greft cerrahisinden (KABGC) sekiz ay sonra motor ve vokal tikleri gelişen bir olguyu sunuyoruz. Burnunu karıştırma ve sümürme gibi birkaç motor tik ve bağırma şeklinde bir vokal tik görülen hasta, öncül duyusal uyarılar da tanımladı. Bu tiklerin ilk kez KABGC'den sonra ortaya çıkmış olması olgumuzun önemli özelliğidir. Manyetik rezonans görüntüleme bilateral bazal ganglionlarda iskemik alanlar ve tek foton emisyon bilgisayarlı tomografi incelemesi sağ kaudat nukleusta ve bilateral frontotemporoparietal kortekste hipoperfüzyon göstermiş olup, bu alanlar tik patogenezi ile ilişkili beyin bölgeleridir. KABGC öncesi kraniyal görüntülemelerin olmaması nedeniyle kesin bir çıkarımda bulunmak güç olmakla birlikte, tiklerin KABGC sırasındaki perfüzyon anomalisinin sonucunda ortaya çıktığı öne sürülebilir.

Anahtar Kelimeler: Tourettizm, Tik, Koroner arter bypass greft cerrahisi, Yaşlı

İletişim Bilgileri:

Volkan Topçuoğlu, M.D.
Marmara University, School of Medicine, Department of Psychiatry,
Altunizade, İstanbul, Türkiye
e-mail: voltop67@hotmail.com

Marmara Medical Journal 2009;22(1);071-075



INTRODUCTION

Tics are sudden, repetitive movements, gestures or utterances that mimic some fragment of normal behaviour¹. The most severe tic disorder is known as the Gilles de la Tourette syndrome [TS]. The Tourette syndrome is defined as multiple motor and one or more vocal tics.

Tics have been reported to occur in association with numerous different acquired and congenital neurological and neuropsychiatric disorders or on exposure to a variety of drugs. The term secondary tics or "tourettism" have been applied to these disorders².

The pathogenesis of TS and tourettism is described as a dysfunction of basal ganglia and its related cortical and thalamic structures which constitute the cortico-striato-thalamocortical (CSTC) circuits³. CSTC circuits subserve many of our normal cognitive, behavioural and emotional repertoire. In cases of tourettism, also similarly noticed in TS cases, neuroradiographic studies of the central nervous system (CNS) have revealed abnormalities in the brain regions which constitute the CSTC³.

Neurologic injury, in the form of either stroke or more subtle neurocognitive impairment, is a frequent and potentially devastating complication of coronary artery bypass grafting surgery (CABGS). The etiology of CABGS-associated neurologic injury is likely to be multifactorial, with cerebral hypoperfusion and embolism being the major contributors⁴.

Tourettism is a rare complication of CABGS. Within the literature, only one case, aged 15, has been reported to have a TS-like syndrome after cardiac surgery⁵.

We present an elderly male case that developed motor and vocal tics after the CABGS.

CASE REPORT

A 73 year-old white male who was admitted to our psychiatric ward with complaints of being unable to resist the urge of picking his nose and involuntary startles. He complained of nasal discomfort such as plumpness, dryness, aching and described the sensation as if "a butterfly was flying" inside his nose. As a response to these sensations, he picked or blew his nose into a handkerchief. He said he knew his nose was clean, but he felt as if it was full of mucus. He said his mind was ordering him to rush to his nose. Besides picking his nose, he touched his nose and then his tongue, he shrugged his shoulders, had jerks on his legs and involuntary movements like jumping up suddenly while he was sitting. Sometimes, involuntary startles were accompanied by involuntary voices in the form of shouting. He felt uneasy before these movements, and afterwards he felt relieved for a while. He reported that he was unhappy and had lost interest in life. He described pain in various parts of his body and added that he had lack of appetite and insomnia.

Eight months prior to his current complaints he had had a CABG operation. He had had hypertension and chronic obstructive pulmonary disease for fifteen years and had coronary artery disease. He had smoked 1-2 packs of cigarettes for the past sixty years. He has cut down the amount since the operation but was still smoking 3-4 cigarettes everyday. He did not have any psychiatric illness until the operation including tics, obsessive-compulsive disorder (OCD) or attention deficit hyperactivity disorder (ADHD). A week after the operation, anxiety accompanied by restlessness, shortness of breath, and drowsiness arose. Because of these complaints he went to a doctor and was prescribed alprazolam 1 mg a day. For five months he took alprazolam in recommended dosage; during the first two months some of his complaints improved but later they recurred. While he was tapering the dosage,



nose picking behavior, involuntary movements and shouting restarted. On admission, he had not been taking any psychotropic medication for a month. He was so embarrassed with these complaints that he avoided meeting his friends. In order to prevent himself from picking his nose he had tried to tie his hand, but that did not work.

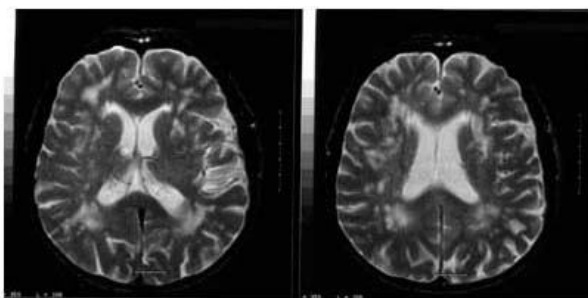
During his admission to the hospital he was agitated, he looked rather anxious and he was in a depressed mood. His thinking process was normal. There was no disturbance in the thought content. No sign of a perceptual disturbance was detected. His short-term memory and concentration were slightly impaired. Other cognitive functions were intact.

In neurological examination, it was detected that his arms did not swing during walking properly. No other disturbance was detected during the examination. EEG was normal.

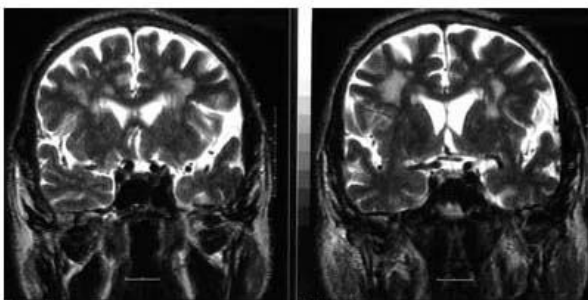
In the carotid artery and vertebral system Doppler ultrasound examination, hemodynamically nonsignificant atheromatous plaques were detected in the right and the left CCA. In the cranial MRI cerebral and cerebellar atrophy; nonspecific focal chronic ischemic regions on the right half of the pons, on the left half of the

medulla oblongata, and patchy ischemic regions in the bilateral basal ganglia, bilateral periventricular white matter and in the centrum semiovale were detected (Fig. 1a and 1b). SPECT examination revealed mild hypoperfusion in the bilateral frontotemporoparietal cortex, decreased activity at the periventricular region and hypoperfusion on the right caudate nucleus (Fig. 2). He did not have preoperative cranial imaging examinations.

For the treatment of his involuntary movements, 1 mg risperidone was prescribed upon his admission to the hospital. It was increased to 2 mg a day and the treatment continued with this dosage. For his depressive symptoms, 25 mg fluvoxamine a day was initiated and it was increased to 200 mg a day. In order to control anxiety, 2 mg clonazepam a day was administered for the first 10 days of the treatment. After the second week of the treatment, the nose picking behaviour disappeared. He was discharged within six weeks and was prescribed 2 mg risperidone and 200 mg fluvoxamine. During his follow-up over the next 12 months, the tics did not reappear. However, anxiety and depressive symptoms persisted in spite of continued administration of his medication.



A



B

Figure 1a ve 1b: Cranial MRI shows ischemic regions in the bilateral basal ganglia.

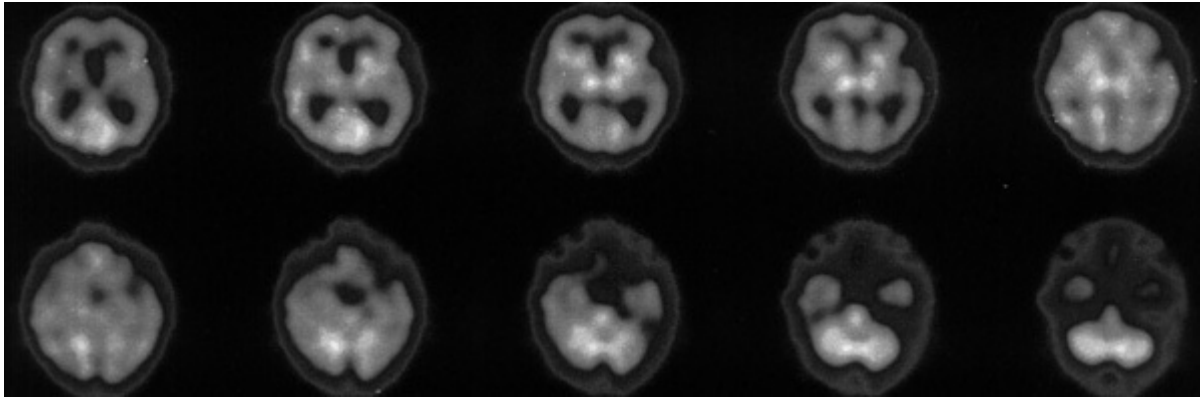


Figure 2: SPECT examination reveals hypoperfusion in the right caudate nucleus and bilateral frontotemporo-parietal cortex.

DISCUSSION

We present here, a 73 year-old male patient who developed motor and vocal tics, anxiety and depression after CABG surgery.

Bouts of picking and blowing his nose, touching his nose followed by his tongue, shrugging his shoulders, jerks in his legs, movements like suddenly jumping while seated were his motor tics. Utterances in the form of shouting were his vocal tics. He clearly defined premonitory sensory urges like dryness, aching, plumpness and a sensation as if “a butterfly was flying” inside of his nose. Premonitory sensory urges are antecedent sensory phenomena, like bodily sensations or an inner tension that cause a major source of distress in some individuals, such as the tics themselves⁶. Premonitory sensory urges are a major source of distress, and were also present in our patient. He felt very uneasy before the involuntary movements and could only find relief after completing them. The presence of motor and vocal tics which were noted to occur in bouts, as well as antecedent sensory phenomena are all considered to present evidence for making a TS like tic syndrome diagnosis in our patient. No personal history of TS or any other tic syndrome, as well as the absence of related disorders like OCD and ADHD, absence of the family history of any tic disorders, argue in favour of a cause and effect relationship of his CABG surgery and the tic syndrome. However, a shorter interval

between the operation and appearance of tics would be more likely to be expected.

Basal ganglia are one of the watershed areas of the brain and are therefore among one of the most vulnerable regions in the brain known to develop vascular insult especially among the elderly patients during the CABG operation. The mechanisms of the injury to the CNS in a CABG operation include hypoperfusion, microembolism, macroembolism or a systemic inflammatory response⁷. It may be suggested that our patient had developed tourettism subsequent to his CABG operation, during which he may have received vascular insult to the basal ganglia and related brain regions. In these particular surgeries, increased age and hypertension are often considered as risk factors causing brain injury, both of which were present in our patient⁷.

Tourettism may be of neurovascular origin⁸. Four reports have described cases of TS-like symptoms secondary to vascular lesions. Bleeker reported a 43 year-old man who developed such symptoms after an angiography⁹. Masso and Obeso described a 66 year-old man with post anoxic hemiballism and coprolalia¹⁰. Ward reported a 62 year-old woman with dysphasia and a suppressible urge to shake her arm¹¹. A CT scan showed lacunar infarcts in the right superior cerebellar peduncle and left basal ganglia. More recently, Kwak and Jankovic described two young men who suffered a



subcortical stroke with hemidystonia and tics; the MRI images showed that both men had infarction in the basal ganglia⁸.

As far as we know, only one case has been reported in the literature that described tourettism after cardiopulmonary by-pass surgery with hypothermia. This adolescent boy, reported by Singer et al, also had inattentiveness and obsessive-compulsive behaviour along with TS⁵. To our knowledge; our case is the first one, where an elderly patient developed tourettism after CABGS.

Although it is not known whether the patient's lesions existed before the surgery or is a result of it, ischemic regions in bilateral basal ganglia and hypoperfusion in the right caudate nucleus and in the frontotemporoparietal cortex might be significant findings implicating the role of these regions in the pathogenesis of TS and other tic disorders¹². In a MRI study done in monozygotic twins with TS abnormalities of the caudate nucleus were found in the more severely affected twin³. Reduced perfusion either of the globus pallidus and putamen or of the basal ganglia as a whole have been reported in TS adults in functional imaging studies. PET studies have shown bilateral symmetrical increases or decreases of glucose utilization within the basal ganglia, and decreased activity in frontal, cingulate and insular cortices¹³.

Diffusion weighted imaging (DWI) has proved to be the most reliable imaging examination in acute stroke to detect small foci of ischemia as well as to differentiate those from chronic nonspecific ischemic gliotic changes^{14,15}. A dedicated MRI examination with DWI which could not be performed in our clinical setting, would have added invaluable data to document the structural as well as the pathophysiological evidence to the disease progression in our case.

As a conclusion, since tourettism and other neuropsychiatric complications might occur post CABG, physicians must keep them in mind particularly with the elderly who carry risk factors for cerebral hypoperfusion and

emboli formation. The recognition and careful study of tourettism cases may help our understanding of the neuroanatomical substrate and the pathogenesis of tic disorders.

REFERENCES

1. Leckman JF, Bradley SP, Pauls DL, Cohen DJ. Tic disorders. *Psychiatr Clin North Am* 1997; 20: 839-861.
2. Kumar R, Lang AE. Secondary tic disorders. *Neurol Clin* 1997; 15: 309-331.
3. Singer HS. Neurobiology of Tourette syndrome. *Neurol Clin* 1997; 15: 357-379.
4. Scarborough JE, White W, Derilus FE, Mathew JP, Newman MF, Landolfo KP. Neurologic outcomes after coronary artery bypass grafting with and without cardiopulmonary bypass. *Semin Thorac Cardiovasc Surg* 2003; 15: 52-62.
5. Singer HS, Dela Cruz PS, Abrams MT, Bean SC, Reiss AL. A Tourette-like syndrome following cardiopulmonary bypass and hypothermia: MRI volumetric measurements. *Mov Disord* 1997; 12: 588-592.
6. Cohen AJ, Leckman JF. Sensory phenomena associated with Gilles de la Tourette's syndrome. *J Clin Psychiatry* 1992; 53: 319-23.
7. Taylor KM. Brain damage during cardiopulmonary bypass. *Ann Thorac Surg* 1998; 65: 20-26.
8. Kwak CH, Jankovic J. Tourettism and dystonia after subcortical stroke. *Mov Disord* 2002; 17: 821-825.
9. Bleeker HE. Gilles de la Tourette's syndrome with direct evidence of organicity. *Psychiatr Clin* 1978; 11: 147-154.
10. Masso JF, Obeso JA. Coprolalia associated with hemiballismus: response to tetrabenazine. *Clin Neuropharmacol* 1985; 8: 189-190.
11. Ward CD. Transient feelings of compulsion caused by hemispheric lesions: three cases. *J Neurol Neurosurg Psychiatry* 1988; 51: 266-268.
12. Sheppard DM, Bradshaw JL, Purcele R, Pantelis C. Tourette's and comorbid syndromes: obsessive compulsive and attention deficit hyperactivity disorder. A common etiology?. *Clin Psychol Rev* 1999; 19: 531-552.
13. Stoetter B, Blesa R, Chase TN. Regional abnormalities in cerebral glucose metabolism in Tourette's syndrome [Abstract]. *Neurology* 1992; 42: 396.
14. Winbeck K, Bruckmaier K, Etgen T, von Einsiedel HG, Rottinger M, Sander D. Transient ischemic attack and stroke can be differentiated by analyzing early diffusion-weighted imaging signal intensity changes. *Stroke* 2004; 35: 1095-1099.
15. Gass A, Ay H, Szabo K, Koroshetz WJ. Diffusion-weighted MRI for the "small stuff": the details of acute cerebral ischaemia. *Lancet Neurol* 2004; 3: 39-45.