

PAPER DETAILS

TITLE: Adenovirus pneumonia in an immunocompetent patient : A case report

AUTHORS: Duygu Vezir,Özlem Alkan,Nihal Merve Çankaya,Zekaver Odabasi,Emel Eryüksel

PAGES: 379-383

ORIGINAL PDF URL: <https://dergipark.org.tr/tr/download/article-file/4320599>

Adenovirus pneumonia in an immunocompetent patient : A case report

Duygu VEZİR¹, Ozlem ALKAN², Nihal Merve CANKAYA³, Zekaver ODABASI³, Semiha Emel ERYUKSEL⁴

¹ Pulmonary and Critical Care Medicine Clinic, Sureyyapasa Teaching and Research Hospital, Istanbul, Turkey

² Department of Endocrinology, School of Medicine, Kocaeli University, Kocaeli, Turkey

³ Department of Internal Medicine, School of Medicine, Marmara University, Istanbul, Turkey

⁴ Department of Pulmonology and Intensive Care, School of Medicine, Marmara University, Istanbul, Turkey

Corresponding Author: Duygu VEZİR

E-mail: duyguvezi01@gmail.com

Submitted: 03.10.2023

Accepted: 15.05.2024

ABSTRACT

Adenoviruses are viruses that typically cause mild infections involving the upper or lower respiratory tract, gastrointestinal tract, or conjunctiva in children and immunocompromised patients. Severe pneumonia progressing to respiratory failure is very rare in healthy adults without underlying immunodeficiency.

In this article, a case of fulminant pneumonia caused by adenovirus in a 26-year-old immunocompetent male patient is presented. The patient, a pediatric resident, applied to our emergency department with cough, pharyngitis, myalgia and fever. He was hospitalized due to the development of tachypnea, dyspnea and somnolence during follow up. Adenovirus was isolated from the nasopharyngeal swab and stool of the patient who developed hypoxemia and had infiltrates on the chest radiograph. The case, that got well and was discharged after an 11-day hospitalization, has been discussed in line with previous studies.

Keywords: Adenovirus, Pneumonia, Immunocompetent, Immunocompromised

1. INTRODUCTION

Adenovirus causes mild, self-limited upper respiratory tract infections gastroenteritis, and conjunctivitis in infants and young children [1]. Occasionally, outbreaks of self-limiting adenovirus infections have been reported in soldiers and children [2]. Severe adenovirus infection resulting in morbidity and mortality is well defined in immunocompromised patients [3]. However, it is very rare in healthy adults without prior immunodeficiency [4]. More than 50 known serotypes and 7 subgroups (A-G) of human adenoviruses have been identified [5].

In this article, a case of severe adenovirus pneumonia in a healthy male patient who presented with rapidly developing respiratory failure and successfully recovered with supportive treatment is presented. The clinical features, radiological findings and results of severe adenovirus pneumonia cases reported in previous studies are summarized.

2. CASE REPORT

A 26-year-old male, a pediatric resident who takes oral antidiabetics due to insulin resistance, was admitted to our emergency department with complaints of fever, cough and shortness of breath. History of fever, cough, sore throat and malaise had started 5 days ago. In the patient's anamnesis there was no hemoptysis, chest pain, difference in diameter between his two legs, color change or swelling and recent long-term travel history. There was no history of exposure to birds or pet feeding. Furthermore, the patient had no abdominal pain or dysuria, but it was learned that he had soft stools 3-4 times a day for the last two days. On admission, the patient was febrile (39.5°C), tachycardic (113/min), and tachypneic (26/min). His blood pressure was 108/72 mm/Hg and oxygen saturation 92%. On physical examination, he had mild pharyngeal and tonsillar hyperemia and his conjunctivas was hyperemic. No rash or lymphadenopathy was detected. No jugular venous distention and pretibial edema were observed. Cardiac examination

How to cite this article: Vezir D, Alkan O, Cankaya MN, Odabasi Z, Eryuksel ES. Adenovirus pneumonia in an immunocompetent patient : A case report. Marmara Med J 2024; 37(3):379-383. doi: 10.5472/marumj.1572504

<http://doi.org/10.5472/marumj.1572504>
Marmara Med J 2024;37(3): 379-383

was normal. Lung auscultation revealed rhonchi and coarse crackles especially in the lower zones of the right lung. No features were seen in the rest of his systemic examination. In the laboratory examinations at admission, high white blood cell and lymphopenia were notable features in the hemogram, while C-Reactive Protein (CRP) was high and procalcitonin was negative, and there was hypoxemia in the blood (Table 1). Posteroanterior (PA) PA chest radiography revealed consolidation in the lower zone of the right lung (Figure I).

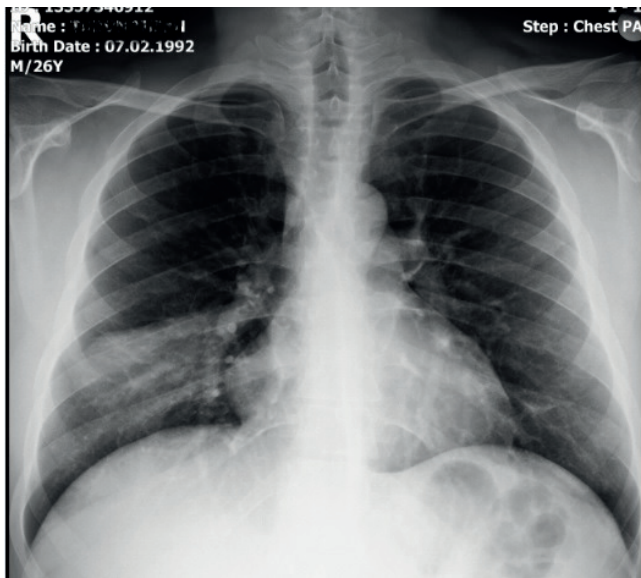


Figure I. PA chest radiography findings at admission

The patient was diagnosed with pneumonia and hospitalized. Blood, urine and sputum cultures were taken. Urine sample was also taken for Legionella and pneumococcal antigen tests. Empirical antibiotic therapy with ampicillin-sulbactam and clarithromycin was initiated. There was no growth in the cultures, urine Legionella and pneumococcal antigen tests were negative. The patient continued having fever in the following days despite treatment with antibiotics and antipyretics. His oxygen saturation decreased to 84%, tachycardia and tachypnea worsened. CRP and liver function tests (LFTs) increased (Table 1). Antibiotic therapy was changed to piperacillin-tazobactam. Considering that the patient was a pediatric resident, nasopharyngeal swab and stool samples were sent in order to study the molecular viral panel. Thorax computerized tomography (CT) scanning (Figure II) was also taken. Consolidation with air bronchograms involving almost the entire middle lobe was observed in the right lung and focal patchy infiltration areas with air bronchograms were observed in the left lung upper lobe's apicoposterior segment and lingula. Focal patchy parenchymal infiltration area was observed at the mediobasal segment of the right lung's lower lobe. An increase in reticular density was observed in the subpleural area posterobasal segment of the right lung's lower lobe. Human adenovirus (HAdV) was positive in the patient's nasopharyngeal swab and stool.

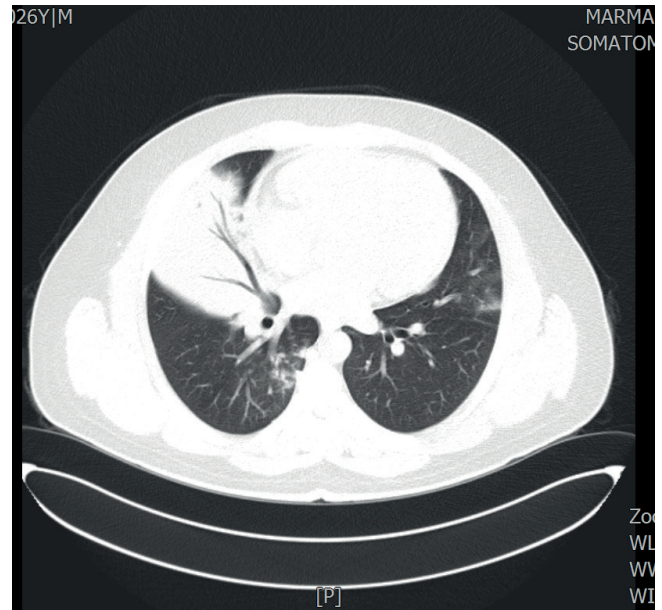


Figure II. Lobar consolidation due to adenovirus pneumonia on thorax CT

The patient was isolated and antibiotics were discontinued. 4-5 lt/min oxygen was given by nasal cannula. Fever was brought under control with supportive treatment, cold application and antipyretics. Eight days after hospitalization, the patient's general condition improved, fever and LFTs regressed. CRP levels and his oxygen requirement also decreased. Vital monitorization was continued. On the eleventh day, a control PA chest radiography (Figure III) was taken. The patient did not require oxygen and had no fever and it was observed that the consolidations had regressed. The patient was discharged successfully with outpatient polyclinic control recommendations.

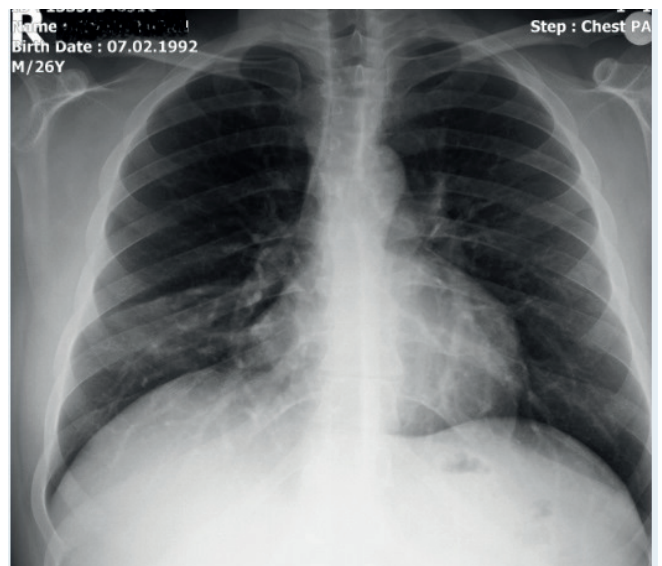


Figure III. Post-treatment PA chest radiography

Table 1. Laboratory values of the patient

	On Admission	3 rd Day of Hospitalization	11 th Day of Hospitalization
Hematology			
White Blood Cell Count (WBC)	13200 μ L	14600 μ L	8200 μ L
Neutrophils	12000 μ L	11300 μ L	4900 μ L
Lymphocytes	700 μ L	2600 μ L	2700 μ L
Eosinophils	0 μ L	0 μ L	100 μ L
Basophils	0 μ L	0 μ L	100 μ L
Monocytes	500 μ L	600 μ L	500 μ L
Hemoglobin (Hb)	13.9 g/dL	12.3 g/dL	13.8 g/dL
Platelets	222000 μ L	212000 μ L	362000 μ L
Serum Biochemistry			
Blood urea nitrogen (BUN)	12 mg/dL	8 mg/dL	8 mg/dL
Creatinine (CRE)	0.89 mg/dL	0.68 mg/dL	0.79 mg/dL
Aspartate aminotransferase (AST)	36 U/L	99* U/L	38 U/L
Alanine aminotransferase (ALT)	39 U/L	78* U/L	82 U/L
Lactate dehydrogenase (LDH)	382 U/L		
Albumin	4.2 g/dL		
Total protein	7.9 g/dL		
Sodium (Na)	140 mEq/L	136 mEq/L	
Potassium (K)	3.8 mEq/L	4.6 mEq/L	
Calcium (Ca)	8.4 mEq/L	8.5 mEq/L	
Glucose	103 mg/dL		
C-reactive protein (CRP)	88.10 mg/L	213* mg/L	5.72 mg/L
Procalcitonin	0.11 ng/mL	0.26 ng/mL	<0.020 ng/mL
Immunoglobulin G (Ig G)	16.33 g/L		
Immunoglobulin A (Ig A)	2.18 g/L		
Immunoglobulin M (Ig M)	2.18 g/L		
Total immunoglobulin E (Ig E)	5.31 IU/ml		
Arterial blood gas (room air)			
pH	7.48	7.43	7.44
Partial pressure of carbon dioxide (PaCO ₂)	33 mmHg	39 mmHg	45 mmHg
Partial pressures of oxygen (PaO ₂)	60 mmHg	50 mmHg	82 mmHg
Arterial oxygen saturation (SaO ₂)	92 %	84 %	96 %
Serum bicarbonate (HCO ₃)	24 mmol/L	25.6 mmol/L	30.2 mmol/L
Lactate	1.7 mmol/L	1 mmol/L	1.6 mmol/L
Base excess	1.3 mmol/L	1.8 mmol/L	5.5 mmol/L

3. DISCUSSION

Adenovirus is a non-enveloped double-stranded linear DNA virus. It can be transmitted to humans by direct contact, fecal-oral or droplet infection. The virus infects mucosal surfaces (gastrointestinal tract, respiratory system, conjunctiva, urogenital system). Fifty percent of adenovirus infections are asymptomatic. Clinical manifestations of symptomatic adenovirus infection includes pharyngoconjunctival fever, cryptictonsillitis, epidemic keratoconjunctivitis, swimming pool conjunctivitis, upper respiratory tract disease, pneumonia, hemorrhagic cystitis, infantile gastroenteritis, hepatitis, myocarditis and meningoencephalitis [2]. In our case, fever, cough, shortness of breath, sore throat and malaise was present and further examination and tests revealed pharyngoconjunctival hyperemia, fever and pneumonia.

Community-acquired pneumonia (CAP) is one of the leading causes of death worldwide. Respiratory viruses account for more than 22% of adult CAP cases. With the help of advances in molecular techniques, HAdV has been found to be increasingly involved in sporadic cases and severe CAP outbreaks in healthy adults [6]. Adenovirus pneumonia is very rare in immunocompetent adults. Even though, it usually shows a mild clinical course that is self-limiting, it can lead to severe epidemics and fatal results even in people with a healthy immune system. Adenovirus is an oncogene in animals but not in humans [7,8]. Outbreaks of adenovirus-related diseases have been described in adults and soldiers. An outbreak of respiratory disease, possibly caused by adenovirus B2 strain, was described in a military camp in Turkey [9].

Although, the immune system of our case was intact, he developed pneumonia. In previous studies, it is stated that adenovirus can cause serious respiratory tract infections in immunocompromised patients, but less is known about severe adenovirus pneumonia in immunocompetent adults. Cederwall et al., in a retrospective study, compared adenovirus-induced respiratory tract infections and pneumonia in immunocompromised and healthy adults in terms of clinical presentation and severity of infection. As a result, they showed that adenovirus can cause serious infections in both immunocompromised and healthy adults and the clinical presentation and the need for hospitalization, mechanical ventilation and antiviral treatment were equal in both groups [10].

Diagnosis of adenovirus infection is made by viral culture, viral antigen test, polimerase chain reaction (PCR) and serology. In our case, we detected adenovirus by PCR in the nasopharyngeal swab and positive viral antigen test in the stool. More than 50 known serotypes and 7 subgroups (A-G) of human adenoviruses have been identified. Adenovirus serotype was not studied in our case [7].

Generally, community-acquired viral pneumonia is caused by influenza, parainfluenza, respiratory syncytial virus, human metapneumovirus and adenovirus. Most of these agents cause bronchiolitis and bronchopneumonia. Lobar pneumonia usually suggests bacterial agents, but unlike other viral agents, adenovirus can cause consolidation [11]. There are studies

showing that the predominant radiological sign of adenovirus pneumonia is consolidation. To date, it is the only virus with a major radiological finding of focal or lobar consolidation that mimicks typical bacterial pneumonia [6,12]. In our patient's thorax CT findings: consolidation, patchy infiltration including air bronchogram was observed.

It is known that advanced age, diabetes, cardiovascular diseases and chronic respiratory diseases cause susceptibility to infectious diseases and a more serious disease course [13]. Many studies show that diabetes is associated with more severe disease and more mortality, especially during the COVID-19 pandemic [14]. Similarly, obesity has been shown to be associated with more severe disease and mortality in COVID-19. Impaired insulin secretion and insulin resistance form the basis of the pathogenesis of Type 2 diabetes [15]. However, there is insufficient evidence that insulin resistance alone causes viral pneumonia and severe disease course. Metformin and lifestyle change have long been used as initial treatment in Type 2 diabetes [16]. Diabetic patients treated with metformin have reduced mortality and complications from COVID-19 compared with patients receiving different or no treatment [17]. Our patient was using metformin due to insulin resistance.

A prospective cohort study that was conducted in China, in respiratory, paediatric, emergency/intensive care wards, participants were followed over 4 weeks for development of clinical respiratory illness. Nasopharyngeal swabs were obtained at baseline and at the end of the study. The primary endpoints were laboratory-confirmed bacterial colonisation and viral respiratory infection. Bacteria were isolated from 76.2% participants at baseline and 57% participants at the end of the study. Among all bacterial positive cases, streptococcus pneumoniae was the most commonly isolated organism at baseline (96%) and at the end of the study (72%). There were 15.7% laboratory confirmed viral infections found at baseline and 9.0% found at the end of the study. Rhinovirus/enterovirus was the most common viral pathogen accounting for 10.8% and 4.5% infections at baseline and at the end respectively. Other viruses detected included adenovirus, coronavirus, H1N1 and H3N2 influenza virus and human metapneumovirus [18]. Being a healthcare provider, our patient was at higher risk of getting respiratory infections.

Treatment of adenovirus may be in the form of supportive treatment and/or antiviral therapy. There are studies reporting positive results after cidofovir and ribavirin administration in immunocompromised patients. In these studies, antiviral therapy was tried in patients with abnormal laboratory findings (leukopenia, thrombocytopenia or elevated liver enzymes), progressive respiratory failure and patients who developed vasopressor and mechanical ventilation requirements and no complications were observed [19, 20]. We applied supportive and symptomatic treatment in our patient and followed up the improvement of his general condition by close vital monitorization without any antiviral therapy.

Conclusion

Today, viral agents, which are among the causes of community-acquired pneumonia, can also cause serious infections in

the normal population. Therefore, in cases where there is no antibiotic response to the treatment of community-acquired pneumonia, it may be appropriate to consider viral causes during diagnosis, even if clinical and radiological findings suggest bacterial agents.

Compliance with Ethical Standards

This research was conducted ethically in accordance with the principles of Helsinki World Medical Association Declaration.

Patient consent: The patient gave his consent for clinical information relating to his case to be reported in a medical publication.

Conflict of interest statement: The authors have no conflict of interest to declare.

Funding sources: This research did not receive any specific grant from funding agencies in the public, commercial, or notfor-profit sectors.

Authors contributions: DV and ZO: Research idea, DV, ZO and SEE: Design of the study, DV, OA and NMC: Acquisition of data for the study, DV: Analysis of data for the study and drafting the manuscript, DV: Interpretation of data for the study, SEE: Revising the manuscript critically for important intellectual content. All authors reviewed the results and approved the final version of the article.

REFERENCES

- [1] Hakim FA, Tleyjeh IM. Severe adenovirus pneumonia in immunocompetent adults: a case report and review of the literature. *Eur J Clin Microbiol Infect Dis* 2008;27:153-8. doi: 10.1007/s10096.007.0416-z.
- [2] Lynch JP 3rd, Fishbein M, Echavarría M. Adenovirus. *Semin Respir Crit Care Med* 2011 ;32:494-511. doi: 10.1055/s-0031.128.3287.
- [3] Pham TT, Burchette JL Jr, Hale LP. Fatal disseminated adenovirus infections in immunocompromised patients. *Am J Clin Pathol* 2003;120:575-83. doi: 10.1309/AWXD-GNC5-D70E-N7YT.
- [4] Hijikata N, Takayanagi N, Sato S, et al. Adenovirus pneumonia in an immunocompetent adult. *J Infect Chemother* 2012;18:780-5. doi: 10.1007/s10156.012.0367-x.
- [5] Rynans S, Dzieciatkowski T, Młynarczyk G. Zakażenia. Adenovirus infection in immunocompromised patients. *Postepy Hig Med Dosw (Polish)* 2013;67:964-72. doi: 10.5604/17322.693.1066199.
- [6] Tan D, Zhu H, Fu Y, et.al. Severe community-acquired pneumonia caused by human adenovirus in immunocompetent adults: A multicenter case series. *PLoS One* 2016 ;11:e0151199. doi: 10.1371/journal.pone.0151199.
- [7] Lion T. Adenovirus infections in immunocompetent and immunocompromised patients. *Clin Microbiol Rev* 2014;27:441-62. doi: 10.1128/CMR.00116-13.

- [8] DeCaprio JA. How the Rb tumor suppressor structure and function was revealed by the study of Adenovirus and SV40. *Virology* 2009;384:274-84. doi: 10.1016/j.virol.2008.12.010.
- [9] Chmielewicz B, Benzler J, Pauli G, Krause G, Bergmann F, Schweiger B. Respiratory disease caused by a species B2 adenovirus in a military camp in Turkey. *J Med Virol* 2005; 77:232-7. doi:10.1002/jmv.20441.
- [10] Cederwall S, Pählman LI. Respiratory adenovirus infections in immunocompetent and immunocompromised adult patients. *Epidemiol Infect* 2020;147:e328. doi: 10.1017/S0950268819002176.
- [11] Febbo J, Revels J, Ketai L. Viral pneumonias. *Radiol Clin North Am* 2022;60:383-97. doi: 10.1016/j.rcl.2022.01.010.
- [12] Zhang P, Liu M, Zhang L, et.al. Clinical and CT findings of adenovirus pneumonia in immunocompetent adults. *Clin Respir J* 2021;15:1343-51. doi: 10.1111/crj.13439.
- [13] Cillóniz C, Pericàs JM, Rojas JR, Torres A. Severe infections due to respiratory viruses. *Semin Respir Crit Care Med* 2022;43:60-74. doi: 10.1055/s-0041.174.0982.
- [14] Aggarwal G, Lippi G, Lavie CJ, Henry BM, Sanchis-Gomar F. Diabetes mellitus association with coronavirus disease 2019 (COVID-19) severity and mortality: A pooled analysis. *J Diabetes* 2020;12:851-5. doi: 10.1111/1753-0407.13091.
- [15] Robertson RP. Antagonist: diabetes and insulin resistance—philosophy, science, and the multiplier hypothesis. *J Lab Clin Med* 1995;125:560-4.
- [16] Davies MJ, Aroda VR, Collins BS, et al. Management of hyperglycaemia in type 2 diabetes, 2022. A consensus report by the American Diabetes Association (ADA) and the European Association for the Study of Diabetes (EASD). *Diabetologia* 2022;65:1925-66. doi: 10.1007/s00125-022-05787-2.
- [17] Petrelli F, Grappasonni I, Nguyen CTT, et al. Metformin and COVID-19: a systematic review of systematic reviews with meta-analysis. *Acta Biomed* 2023;94:e2023138. doi: 10.23750/abm.v94iS3.14405.
- [18] Raina MacIntyre C, Chughtai AA, Zhang Y, et al. Viral and bacterial upper respiratory tract infection in hospital health care workers over time and association with symptoms. *BMC Infect Dis* 2017;17:553. doi: 10.1186/s12879-017-2649-5.
- [19] Yoon BW, Song YG, Lee SH. Severe community-acquired adenovirus pneumonia treated with oral ribavirin: a case report. *BMC Res Notes* 2017 ;10:47. doi: 10.1186/s13104-016-2370-2.
- [20] Zhao J, Yap A, Wu E, Low CY, Yap J. Severe community acquired adenovirus pneumonia in an immunocompetent host successfully treated with IV Cidofovir. *Respir Med Case Rep* 2020;30:101037. doi: 10.1016/j.rmcr.2020.101037.