

## PAPER DETAILS

TITLE: Rare Skin Localization of the Mite: Can it be a house dust mite?

AUTHORS: Yasemin KAYA,Özgür ENGİNYURT,Ülkü KARAMAN

PAGES: 276-279

ORIGINAL PDF URL: <https://dergipark.org.tr/tr/download/article-file/1267175>

## CASE REPORT

# Rare Skin Localization of the Mite: Can it be a house dust mite?

Yasemin Kaya<sup>1</sup>, Özgür Enginyurt<sup>2</sup>, Ülku Karaman<sup>3</sup>

<sup>1</sup>Department of Internal Medicine, Faculty of Medicine, Ordu University, Ordu, Turkey.

<sup>2</sup>Department of Family Medicine, Faculty of Medicine, Ordu University, Ordu, Turkey

<sup>3</sup>Department of Parasitology, Faculty of Medicine, Ordu University, Ordu, Turkey

Received: 31 May 2020, Accepted: 17 August 2020, Published online: 31 August 2020

© Ordu University Institute of Health Sciences, Turkey, 2020

## Abstract

The word “allergy” has been used to describe unexpected reactions occurring in human body at the beginning of the 20th century. House dust mites are known as an important source of allergens that are found in house dust. Different studies on patients with positive skin test, who were monitored for allergic complaints have shown 35% to 99% mite positivity in house dust. This study evaluated a case of patient with long term (six months) severe itching and mite identified in standard skin biopsy sample. So, it was thought that it might be a house dust mite.

**Key words:** Dust mite, Allergy, Ectoparasites

**Suggested Citation:** Kaya Y, Enginyurt O, Karaman U. Rare Presentation of House Dust Mite: Skin Localization. Middle Black Sea Journal of Health Science, 2020; 6(2):275-278.

## Address for correspondence/reprints:

Yasemin Kaya

**Telephone number:** +90 452 225 23 42

**ORCID-ID** 0000-0001-7360-8090

**E-mail:** ysmnkcmmz@gmail.com

**DOI:** 10.19127/mbsjohs.746015

**Note:** A part of this study was presented as “Poster Presentation” at the “16th International Eastern Mediterranean Family Medicine Congress (11-14 May 2017)”.

## Introduction

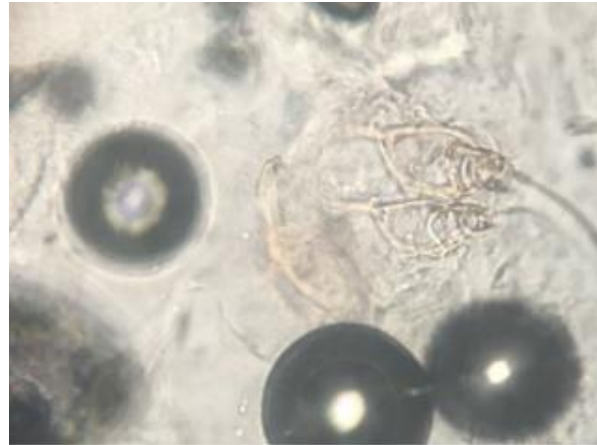
The word “allergy”, derived from the Greek word “allos” meaning “other”, has been used to describe unexpected reactions occurring in human body at the beginning of the 20th century. Allergens have antigenic structure along with protein or glycoprotein structure and create reactions via IgE in the organism. The mechanism of allergic reactions is complicated, and many factors play a role in formation of the allergic reactions and determining the severity. These include factors like genetic tendency, exposure route, allergen dose and structural characteristics of the person (Cekic and Sapan, 2015; Reithofer and Jahn-Schmid, 2017). Additionally, common allergen sources include feces of dust mites and cockroaches, hair from cats and dogs and mould spores (Reithofer and Jahn-Schmid, 2017; Sokol et al., 2017; Raap et al., 2011; Pravettoni et al., 2014).

With the determination of house dust mites as an important source of allergens found in dust, studies have focused on their distribution in a variety of places around the world, determination of species, allergic complaints, and correlation with various

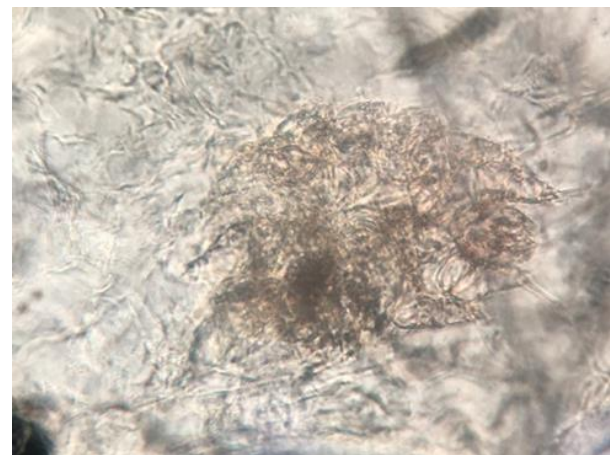
diseases. Several studies have found that patients with positive skin test monitored for allergic complaints have 35% to 99% mite positivity in their house dust (Atambay et al., 2006) This study evaluated a case of a patient with long term (six months) severe itching and house dust mite identified in standard skin biopsy sample.

## Case

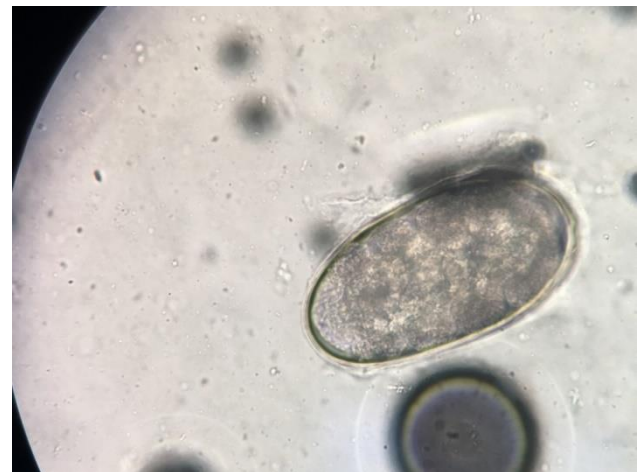A 67-year-old female patient was brought directly to the Ordu University Parasitology laboratory with a complaint of widespread itching on the body by a relative of her (medical faculty student). The anamnesis of the patient included submission to various clinics due to widespread and severe itching on the abdomen, groin, hip, shoulder and chest regions beginning 6 months previously, with blood, urine and stool analysis completed and no pathology was found to explain itching. In light of this, the patient was given oral steroids and scabies treatment for her complaints, but the symptoms were not resolved. When questioned about food and medications that may cause allergies, we learned that the patient's itching was not related to food, and she did not use any medication other than given drugs for itching and the patient had no any chronic disease. When the itchy regions on the patient's body were investigated, no other pathology was identified, except for excoriation lesions linked to scratching. When the patient was admitted to the laboratory, the standard skin biopsy method was used to obtain samples from the calf and abdominal region, and these were investigated under a light microscope. Investigation of the samples revealed encountered adult mites and mite eggs. The mite was identified and photographed in the light of the relevant literature (Hart and Fain, 1988; Gülkan, 2004). Besides, it was determined that there were no *Sarcoptes scabiei* according to the morphological structure of the mite. (Figures 1-3).



**Figure 1.** A Part of Adult Mite (20X)



**Figure 2.** Adult Mite (20X)



**Figure 3.** Mite Eggs (20X)

With large amounts of mites identified on the body, the patient was asked to bring dust samples from 4 different areas of her house. The patient was told to place all dust obtained in a closed large container after vacuuming the living room, bedroom, hall and kitchen with an electric vacuum cleaner, and to bring it to the parasitology laboratory immediately.

The dust samples were investigated with the lactic acid precipitation method and the mites were identified. To begin treatment, the patient was sent to the internal medicine clinic. The patient was administered 5% permethrin treatment for one month. She was called for check-up at the end of the treatment, and the patient's complaints had resolved and no more mites were identified on the skin.

### Discussion

Mites are found in all locations from the polar regions to deserts, and in all types of living environments, and they can live as parasites on a variety of plants and animals just as they can live free in nature (Demirsoy, 1998; Unat et al., 1995). In this presented case, they were determined as ectoparasites on the human body.

The density and variety of mite species in a given region are linked to several factors like humidity, elevation, socioeconomic level, and seasons. At a humidity level  $\leq 50\%$ , the life cycle of house dust mites is shortened. In regions with elevation  $\geq 1000$  m, the density decreases and the incidence falls. Living conditions due to socioeconomic situation affect the incidence of mites on a household basis. Additionally, they are observed more commonly in houses in rural areas, with old furniture, without ventilation or exposure to sunlight. It is known that house dust mites are common in the fall season due to the variations in humidity and temperature (Arlian, 1992; Aygan and Ozcelik, 2002). Dust samples obtained from the house of our patient were found to contain *Dermatophagoides pteronyssinus*.

Studies of different venues like houses, hotels, student dormitories, hospitals and libraries have shown that house dust mites are most observed in houses. The rate of mites observed in libraries was close to that of houses; however, in places like hospitals and hotels, the house dust mite incidence has been found to be nearly half of those found in houses (Budak, 1984). In studies about identification of species, genus, and family levels of mites in Turkey, unidentified species have been mentioned. Studies have found that *Dermatophagoides pteronyssinus* is the dominant species followed by *Lepidoglyphus destructor*. In order of incidence, Cheyletus and Tarsonemus genera and families without species identification from Glycyphagidae, Polyaspididae and Histiotomatidae have been found (Kalyoncu, 1995; Ozcelik, 1997).

House dust mites have been correlated to allergies since 1960 and reported to cause diseases related to the respiratory tract (Arachnida and Kgv Ed, 1973). Feces, secretions, and body parts of mites have been

reported to rank the first place for allergens, and not only living mites but also dead ones to be allergic. Each mite defecates 20-25 times per day. These contact the body through the respiratory tract or skin and have been reported to cause allergic reactions (Varma, 1996). The most important allergen found on *D. Pteronyssinus* is a glycoprotein called Der p I, and Der p II for *D. Farinae*. These antigens are used in skin tests; however, it should be noted that positivity on skin tests does not identify species found in dust, while negativity does not mean that there is no allergic reactions due to house dust mites. Mite allergens are found in secretions, mite fragments and especially in feces, with emphasis that more than 95% of allergens are due to mite feces (Schnyder, 2000). In our present case, the patient presented with severe itching complaint on the abdomen, groin, hip, shoulder, and chest regions, beginning 6 months ago and the vector was identified as house dust mites on skin. With treatment, the patient's complaints were resolved.

For treatment, the use of antihistamine medications is recommended, although preventive methods are more important. In this way, preventing the ideal environment for mites is recommended to protect against mites and to reduce complaints of allergic diseases due to house dust mites (Bernhard, 1986). In this case, we used creams containing antihistamines and 5% permethrin.

### Conclusion

This study was presented with the aim of attracting attention to the fact that, contrary to the general literature, mites may live on the human body, thus causing allergic reactions

---

**Ethics Committee Approval:** Ethics committee approval was not received. Verbal and written consent was obtained from the patient.

**Peer-review:** Externally peer-reviewed.

**Author Contributions:** Concept- Y.K.; Design- Y.K., O. E, U.K.; Materials- Y.K, U.K.; Data Collection and Processing- Y.K., O.E, U.K.; Literature Review- O.E.; Writing- Y.K, O.E., U.K.; Critical Review- Y.K, O.E., U.K

**Conflict of Interest:** No conflict of interest was declared by the authors.

**Financial Disclosure:** The authors declared that this study hasn't received no financial support.

---

# References

- Arachnida S.J, Kgv Ed S. Insects and Another Arthropods of Medical Importance. London: The Trustees of The British Museum (Natural History).1973; 17-462.
- Arlian Lg. Water Balance and Humidity Requirements of House Dust MitesExp Appl Acarol. 1992;16(1-2):15-35
- Atambay M, Aycan OM, Yologlu S, Karaman U, Daldal N. The Relationship between the Skin Allergy Test and House Dust Mites. Acta Parasitologica Turcica, 30 (4): 327-329, 2006
- Aygan C, Ozcelik S. The Prevalence of House Dust Mites in Sivas Region and Its Role in Atopic Allergy.Acta Parasitologica Turcica, 2002; 26(2):186-191
- Bernhard K, Karg W, Steinbrink H. House Dust Mites İn Bed Dust and On the Body. Angewandte Parasitologie, 1986; 27(1):49-52
- Budak S. The Distribution of Dermatophagoides Pteronyssinus with Medicinal Importance in the Aegean Region. Acta Parasitologica Turcica,1984; 8(12):145-152
- Demirsoy A. Basic Rules of Life (Invertebrates = Invertebrae) Volume-II / Part pp:772-781, 1998.
- Hart BJ, Fain A. Morphological and biological studies of medically important house-dust mites. Acarologia 1988;29:284-95.
- Gülkan B. Hatay ilinde ev tozu akarları. Cumhuriyet Üniv. Sağ. Bil. Enst. Yüksek Lisans Tezi. Sivas, 2004.
- Kalyoncu AF, Coplu L, Selcuk ZT, Emri AS, Kolacan B, Kocabas A,Akkoclu A, Erkan L, Sahin A, Baris YI. Survey of The Allergic Status of Patients with Bronchial Asthma In Turkey: A Multicenter Study. Allergy 1995; 50; 451–455
- Ozcelik S. Mites That May Cause Allergy and Dermatitis. Arthropod Diseases in Parasitology Vectors (Ozcel Ma, Daldal N Ed.). Acta Parasitologica Turcica Association, 1997; 13: 355-361
- Pravettoni V, Primavesi L, Piantanida M. Shiitake Mushroom (Lentinusedodes): A Poorly Known Allergen in Western Countries Responsible for Severe Work-Related Asthma.Int J Occup Med Environ Health, 2014; 27(5):871-4.
- Raap U, Wagenmann M, Pfaar O. Allergen-Specific Immunotherapy In Pet Allergy - An Update. Hautarzt., 2011; 62(9):657-62.
- Reithofer M, Jahn-Schmid B. Allergens with Protease Activity from House Dustmites. Int. J. Mol. Sci, 2017; 18: 1368
- Schnyder B, Schweri T, Thomann B,Pichler C. Allergy To House Dust Mite. Schweiz Med Wochenschr, 2000; 130(12):443-7
- Sokol Wn, Wunschmann S, Agah S. Grasshopper Anaphylaxis In Patient Sallergic To Dust Mite, Cockroach, And Crustaceans: Is Tropomyos In The Cause?Ann Allergy Asthma Immunol., 2017; 119(1):91-92.
- Sukru Cekic, Nihat Sapan. Alerjen Spesifik İmmunoterapi (Allergen Specific Immunotherapy). J Curr Pediatr, 2015;13:46-55
- Unat EK, Yucel A, Altas K, Samastı M. Medicine Parasitology 5th Edition, İ.U. Cerr. Faculty of Medicine. Pub. No:15 S:193-197, 1995. İstanbul.
- Varma M. Ticks and Mites. Manson's Tropical Diseases (Ed. Manson-Bahr P.E.C) 20 Th. Ed. W.B. Saunders Com. 1996; 1649-1659