

PAPER DETAILS

TITLE: A Rare Complication in an Untreated Horizontal Root Fracture Case

AUTHORS: Fatih TULUMBACI,Volkan ARIKAN,Aylin AKBAY OBA,Fethi ATIL

PAGES: 396-399

ORIGINAL PDF URL: <https://dergipark.org.tr/tr/download/article-file/888044>

CASE REPORT

A rare complication in an untreated horizontal root fracture case

Fatih Tulumbacı(0000-0003-0102-3223)^α, Volkan Arıkan(0000-0002-9331-0969)^β, Aylin Akbay Oba(0000-0001-8820-8671)^β, Fethi Atıl(0000-0002-8286-4819)^γ

Selcuk Dent J, 2019; 6: 396-399 (Doi: 10.15311/selcukdentj.357968)

Başvuru Tarihi: 25 Kasım 2017
Yayına Kabul Tarihi: 24 Ocak 2019

ABSTRACT

A rare complication in an untreated horizontal root fracture case

Intra-alveolar root fractures in permanent teeth are rare following dental traumatic injuries. The diagnosis of root fractures depends on careful clinical and radiographic examination. The successful treatment of a root-fractured tooth involves repositioning and fixation. Although the outcome of a root fracture is generally favourable, complications such as pulpal necrosis, radicular resorption and pulpal canal obliteration can arise. A radicular cyst is an inflammatory cyst that develops as a result of untreated dental caries, with pulp necrosis and periapical infection following chemical, physical or bacterial injury. In this case report, the diagnosis and treatment of a rare case of a radicular cyst, which occurred as a result of pulp necrosis following horizontal root fracture, and an apical root fragment, which was displaced by the cystic lesion to the base of the nasal cavity, are presented.

KEYWORDS

Cone-beam computed tomography, radicular cyst, root fractures

ÖZ

Tedavi edilmeyen horizontal kök kırığı olgusunda nadir bir komplikasyon

Travmatik diş yaralanmalarından sonra daimi dişlerde intra-alveolar kök fraktürleri nadir olarak görülmektedir. Kök kırıklarının tanısı dikkatli klinik ve radyografik muayanelere bağlıdır. Kök kırığı olan bir dişin başarılı bir şekilde tedavisi yeniden konumlandırmayı ve fiksasyonu gerektirir. Kök kırığının sonucu genellikle olumlu olmasına rağmen, pulpal nekroz, radiküler rezorpsiyon ve pulpa kanal obliterasyonu gibi komplikasyonlar ortaya çıkabilir. Radiküler kist, tedavi edilmemiş diş çürüğü, kimyasal, fiziksel veya bakteriyel hasar sonrası pulpa nekrozu ve periapikal enfeksiyon sonucu gelişen bir inflamatuvar kisttir. Bu olgu sunumunda, yatay kök kırığı sonrası pulpa nekrozu sonucu ortaya çıkan nadir bir radiküler kist olgusunun ile kistik lezyonla burun tabanı arasında yer değiştiren apikal kök kırığı parçasının tanı ve tedavisi sunulmaktadır.

ANAHTAR KELİMELER

Konik ışınlı bilgisayarlı tomografi, kök kırıkları, radiküler kist

Horizontal root fractures are relatively rare in occurrence and comprise approximately 0.5–7.0 % of all dental injuries. These injuries, which involve the cementum, dentine, pulp and supportive tissues, including the periodontal ligament and alveolar bone¹, commonly occur in the anterior maxillary region and in teeth in which complete root formation are affected. Root fractures are diagnosed by radiographic and clinical examinations. Clinically, the fractured tooth is slightly extruded and displaced palatally.² Horizontal root fractures occur most commonly in the middle third of the root (57 %), followed by the apical third (34 %) and the coronal third (9 %).³ Treatment usually involves repositioning and stabilizing the coronal segment into its correct position and monitoring the tooth. The healing process of horizontal fractures depends on the

mobility of the coronal fragment, the location of the root fracture, the stage of root formation and the age of the patient.² Four types of healing patterns have been reported in root fractures: (a) healing with calcified tissue, (b) interposition of connective tissue, (c) interposition of bone and connective tissue and (d) interposition of granulation tissue.^{4,5} Although the outcome of a root fracture is generally favourable, complications, including pulpal necrosis, radicular resorption and pulpal canal obliteration, can arise.⁶

Radicular cysts are the most frequent type of cysts found in the jaw, accounting for 38–68 % of all jaw cysts. It is an inflammatory cyst and develops as a result of untreated dental caries, with pulp necrosis and periapical infection, following chemical, physical or bacterial injury. It is clinically asymptomatic and

^α Ankara Yıldırım Beyazıt University Faculty of Dentistry, Department of Pediatric Dentistry, Ankara, Turkey

^β Kırıkkale University Faculty of Dentistry, Department of Pediatric Dentistry, Kırıkkale, Turkey

^γ Kırıkkale University Faculty of Dentistry, Department of Oral and Maxillofacial Surgery, Kırıkkale, Turkey

painless, and a negative response is received in vitality tests for the respective teeth.⁷

In this case report, the diagnosis and treatment protocol of a radicular cyst that developed following an untreated horizontal root fracture and an apical root fragment that was displaced by the cystic lesion to the base of the nasal cavity are presented.

CASE REPORT

A 13-year-old boy was referred to our clinic with a chief complaint of swelling in the anterior region of his palate. According to the patient's history, he was involved in a traffic accident and suffered a traumatic injury 2 years ago, but had not consulted a dentist as he had no dental complaints until the swelling occurred 1 week ago. His medical history revealed no systemic disease, and on extra-oral examination, no pathologies were observed. On intra-oral examination, a swelling was observed on the palate, behind teeth #11, #12 and #13, and tooth #12 exhibited grade II mobility (Figure 1). Periapical and panoramic radiographs showed that a cyst was present near the apical region of the lateral incisor, which had an open apex and a relatively short root formation. Following consultation with the Department of Maxillofacial Surgery, because the boundaries of the cyst were large and adjacent to anatomical structures, including the nasal cavity and the roots of teeth #11 and #13, cone-beam computed tomography (CBCT) was performed on the patient for further diagnosis to eliminate risks during surgery. The CBCT image revealed the presence of an apical fragment, which was displaced by the cystic lesion to the base of the nasal cavity (Figure 2). According to these findings, the most likely diagnosis was a cystic lesion, which had formed following an intra-alveolar root fracture.

During the surgery, a full-thickness flap was prepared on the area between teeth #11 and #14. A window was opened on the bone tissue surrounding the cystic lesion using a surgical diamond bur. The cyst was enucleated using curettes, and the apical root fragment was extracted. Tooth #12 was also extracted due to excessive mobility. The pathological examination performed following surgery resulted in the diagnosis of a radicular cyst (Figure 3).

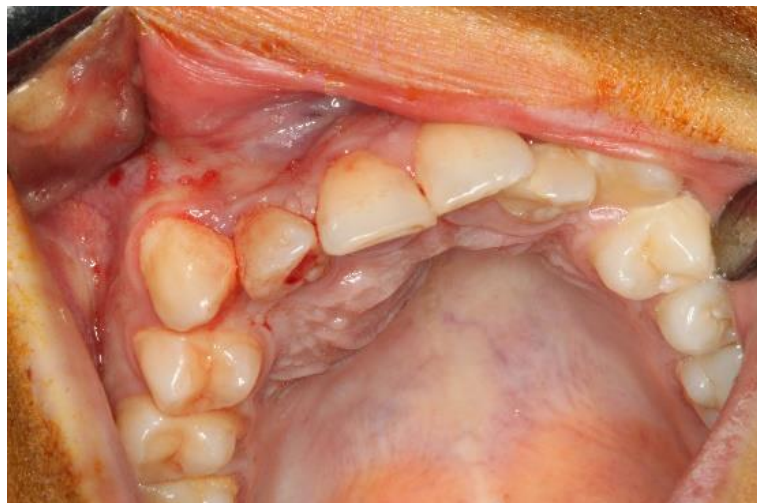

Figure 1.

Palatal swelling in the region

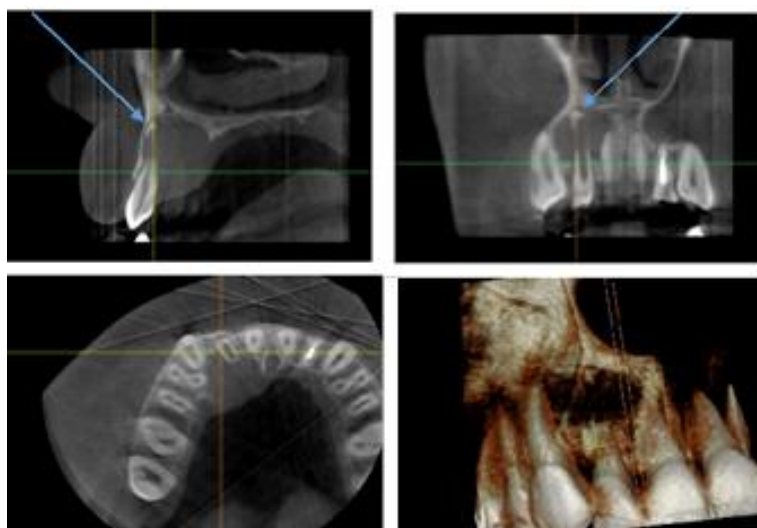


Figure 2.

Dental cysts and sagittal, coronal, axial CBCT images

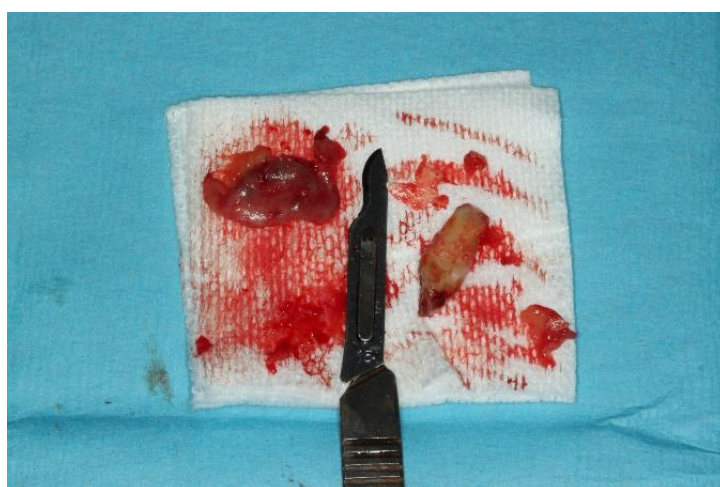

Figure 3.

Cysts, and apical tooth fragment

DISCUSSION

The successful healing of the root fragments depends on the presence of vital pulp tissue, a healthy periodontium and the dislocation of fragments.⁸ Although the healing of root fractures without treatment has been presented in many reports⁹⁻¹¹ and that spontaneous healing following a root fracture in teeth that maintain pulp vitality is clinically significant, possibly occurring in approximately 70–80 % of intra-alveolar root fracture cases,^{12,13} optimal repositioning is considered essential to facilitate healing. The occurrence of pulp necrosis is relatively low following an apical third root fracture, with a rate of 5–25 %.¹⁴ The frequency of pulp necrosis following root fractures is higher in mature teeth than in teeth with open apices. When the distance between fragments increases, the rate of pulp necrosis also increases.⁵ Previous case reports have also reported other complications, including root canal calcification, obliteration and resorption.^{15,16} In the present case study, a rare complication of a radicular cyst, which formed following an untreated intra-alveolar root fracture, was presented. There has only been one published case in the literature that reported a similar complication. Kothry *et al.*¹⁷ presented a case of a cystic lesion formation between fragments and dislocation of an apical fragment following root canal treatment in a case of horizontal root fracture.

Radicular cysts arise from epithelial residues in the periodontal ligament following the inflammation of dental pulp necrosis. Usually, these cysts are asymptomatic and diagnosed during routine radiographic investigations. Sometimes, radicular cysts reaching large sizes can cause complications on adjacent anatomical structures.¹⁸⁻¹⁹ In such cases, the close relation between the anatomical structure and the cyst can be visualized using computed tomography (CT).²⁰

CBCT scanners are based on volumetric tomography, using a two-dimensional (2D) extended digital array providing an area detector. This is combined with a three-dimensional X-ray beam. The CBCT structure contains a high level of contrast, which allows the evaluation of hard tissues. The use of CBCT in clinical practice provides advantages, including X-ray beam limitation, image accuracy, rapid scanning, dose reduction, display modes unique to maxillofacial imaging and reduced image artefacts for maxillofacial imaging, compared with conventional CT [21]. CBCT is a novel tool available for the accurate diagnoses of root fractures, regarding their presence or absence, their exact location, extent and direction of the fracture line.^{14,15} The use of CBCT for the diagnosis of root fractures has been suggested by the American Association of Endodontists and the American

Association of Oral and Maxillofacial Radiologists as well as the International Association of Dental Traumatology. Most recent trauma guidelines suggest that in addition to conventional radiography, CBCT scans may be considered for the diagnosis of root fractures.²² However, concerns related to the use of CBCT have become an issue in the recent years, particularly in younger patients, because of higher levels of radiation, higher cost to the patient and the need for sufficient training to properly evaluate the entire data set.²³ However, the use of CBCT has been recommended by the American Academy of Pediatric Dentistry in complicated cases of dental and maxillofacial injury, bone fractures and pathological abnormalities in children.^{21,23-25} In the present case study, CBCT was used prior to surgical treatment to determine the relationship between the cystic lesion and anatomical structures and neighbouring teeth. During the evaluation of the CBCT images, the apical part of the horizontal root fracture, which could not be observed in the conventional 2D images, was detected.

CONCLUSION

Parents should be made aware of the importance of visiting a dental clinic, even in the absence of complaints. In addition, intra-alveolar root fractures should be monitored clinically and radiographically to assess for complications, which may arise in the long term. The present case report also highlights the importance of the use of CBCT in certain specific circumstances.

- Parents should be made aware of the importance of visiting a dental clinic, even in the absence of complaints. Also, the importance of the use of CBCT in certain specific circumstances in children patients.

REFERENCES

- Clark SJ, Eleazer P. Management of a horizontal root fracture after previous root canal therapy. *Oral Surg Oral Med Oral Pathol Oral Radiol Endod* 2000; 89: 220-3.
- Andreasen JO, Andreasen FM, Mejare I, Cvek M. Healing of 400 intra-alveolar root fractures. 2. Effect of treatment factors such as treatment delay, repositioning, splinting type and period and antibiotics. *Dent Traumatol* 2004; 20: 203-11.
- Feely L, Mackie IC, Macfarlane T. An investigation of root-fractured permanent incisor teeth in children. *Dent Traumatol* 2003; 19: 52-4.
- Cvek M, Andreasen JO, Borum MK. Healing of 208 intraalveolar root fractures in patients aged 7–17 years. *Dent Traumatol* 2001; 17: 53-62.
- Andreasen JO, Andreasen FM, Mejare I, Cvek M. Healing of 400 intra-alveolar root fractures. 1. Effect of pre-injury and injury factors such as sex, age, stage of root development, fracture type, location of fracture and severity of dislocation. *Dent Traumatol* 2004; 20: 192-202.
- Majorana A, Pasini S, Bardellini E, Keller E. Clinical and epidemiological study of traumatic root fractures. *Dent Traumatol* 2002; 18: 77-80.
- Fomete B, Osunde OD, Oqbeifun J, Aqbara R, Ononiwu CN. A 10-Year Retrospective Analysis of 64 Cases of Cystic Lesions of the Oral and Maxillofacial Region in a Nigerian Tertiary Hospital. *Omen Med J*, 2016. 31: 434-8
- Camp JH. Management of sports-related root fractures. *Dent Clin North Am* 2000; 44: 95-109, vi-vii.
- Chala S, Sakout M, Abdallaoui F. Repair of untreated horizontal root fractures: two case reports. *Dent Traumatol* 2009; 25: 457-9.
- Oztan MD, Sonat B. Repair of untreated horizontal root fractures: two case reports. *Dent Traumatol* 2001; 17: 240-3.
- Cobankara FK, Ungor M. Spontaneously healed horizontal root fracture in maxillary first premolar: report of a case. *Dent Traumatol* 2007; 23: 120-2.
- Falomo OO. Spontaneous repair following root fracture. *Odontostomatol Trop* 1985; 8: 219-20.
- Bender IB, Freedland JB. Clinical considerations in the diagnosis and treatment of intra-alveolar root fractures. *J Am Dent Assoc* 1983; 107: 595-600.
- Lenzi R, Trope M. Revitalization procedures in two traumatized incisors with different biological outcomes. *J Endod* 2012; 38: 411-4.
- Tetradis S, Anstey P, Graff-Radford S. Cone beam computed tomography in the diagnosis of dental disease. *J Calif Dent Assoc* 2010; 38: 27-32.
- Hovland EJ. Horizontal root fractures. Treatment and repair. *Dent Clin North Am* 1992; 36: 509-25.
- Kothari P, Murphy M, Thompson J. Horizontal root fracture--an unusual complication. *Br Dent J* 1994; 176: 349-50.
- Schwartz Z, Somers A, Mellonig TJ, Carnes DL Jr, Dean DD, Cochran DL. Ability of commercial demineralized freeze-dried bone allograft to induce new bone formation is dependent on donor age but not gender. *J Periodontol* 1998; 69: 470-8.
- Gibson GM, Pandolfi PJ, Luzador JO. Case report: a large radicular cyst involving the entire maxillary sinus. *Gen Dent* 2002; 50: 80-1.
- Amos MJ, Dalghous A, Alkhabuli J, Mizen KD. Massive maxillary radicular cyst presenting as facial fracture and abscess, a case report. *Libyan J Med* 2007; 2: 211-3.
- Scarfe WC, Farman AG, Sukovic P. Clinical Applications of Cone-Beam Computed Tomography in Dental Practice. *J Can Dent Assoc* 2006; 72: 75-80.
- Hatcher DC. Operational principles for cone-beam computed tomography. *J Am Dent Assoc* 2010; 141: 3S-6S.
- Hidalgo Rivas JA, Horner K, Thiruvengkatachari B, Davies J, Theodorakou C. Development of a low dose protocol for cone beam CT examinations of the anterior maxilla in children. *Br J Radiol* 2015; 20150559.
- Leif Kullman, Mona Al Sane. Guidelines for dental radiography immediately after a dento-alveolar trauma, a systematic literature review. *Dent Traumatol* 2012; 28: 193-9.
- Jaju PP, Jaju SP. Clinical utility of dental cone-beam computed tomography: current perspectives. *Clin Cosmet Invest Dent* 2014; 6: 29-43.

Corresponding Author:

Assist. Prof. Fatih TULUMBACI
 Ankara Yıldırım Beyazıt University
 Faculty of Dentistry, Department of Pediatric Dentistry
 Ankara, Turkey
 Tel : +90 312 324 15 55
 Fax : +90 312 324 15 05
 E-Mail : fatihtulumbaci@hotmail.com