

PAPER DETAILS

TITLE: Uterine artery embolization: is it reliable for myoma treatment?

AUTHORS: Nurullah Dogan,Omer Fatih Nas

PAGES: 127-134

ORIGINAL PDF URL: <https://dergipark.org.tr/tr/download/article-file/316259>

Uterine artery embolization: is it reliable for myoma treatment?

Nurullah Dogan¹, Omer Fatih Nas²

¹Department of Radiology, Private Doruk Hospital, Bursa, Turkey

²Department of Radiology, Uludag University School of Medicine, Bursa, Turkey

ABSTRACT

Objectives. We aimed to share the long-term technical and clinical success results, complications and radiologic follow-up findings in our myoma cases treated with uterine artery embolization (UAE)) and to make a contribution to the literature data on this subject. **Methods.** The study was retrospective and the results of 70 patients who underwent UAE for myoma treatment at our institute between January 2012 and January 2015 were analyzed. **Results.** The age range was 22 to 46 years and the mean age 34 years. The postprocedural follow-up duration was 6 to 24 months and the mean follow-up duration was 14 months. The technical success rate was 100% and the clinical success rate was 84.7%. On postprocedural follow-up, fibroid passage was seen in 2 patients (2.85%), severe hypermenorrhea in 4 (5.7%) and postembolization syndrome in 6 (8.5%). Our myoma recurrence rate was 11.36% (n=5). The UAE procedure did not need to be repeated in any of the patients. **Conclusions.** UAE is a reliable alternative to hysterectomy and myomectomy. We believe that UAE should be preferred in patients who are recommended hysterectomy or are predicted to potentially need hysterectomy during myomectomy.

Eur Res J 2017;3(2):127-134

Keywords: Uterine artery embolization, myoma, myomectomy

Introduction

Uterine myomas are the most common gynecological problem that is seen in women of reproductive age [1]. Since most of the myomas are asymptomatic, their exact prevalence cannot be known. In symptomatic myomas, hysterectomy and myomectomy are traditional treatment methods [2]. According to literature data, myomectomy is recommended as the first option especially for patients who expect to conceive. Today, women prefer uterine

myoma embolization (UME) more over abdominal myomectomy, even though they expect to get pregnant [3-6]. The reasons of this preference are that UME has less invasive, shorter hospitalization time and providing quick healing.

In our country, in accordance with the decision of the consensus established with obstetrician and gynecologists, we suggest patients who expect to conceive to undergo myomectomy. Likewise, we

Address for correspondence:

Nurullah Dogan, MD., Private Doruk Hospital, Department of Radiology, Bursa, Turkey

E-mail: drndogan@gmail.com

Received: September 18, 2016; Accepted: January 15, 2017; Published Online: January 16, 2017

recommend hysterectomy to patients above 42 years who do not expect to conceive, since it has a protective role against cancer. However, we implement UME process on patients whom hysterectomy is recommended even though they expect to conceive, and also in cases that may require hysterectomy during the operation. Our short-term results were published in previous studies [7]. In this study, we share our long-term technical success, clinical success and complications.

Methods

Our study was retrospective and the results of 70 patients who were treated with UAE at the unit between January 2012 and January 2015 were analyzed. All the patients had undergone pelvic computed tomography (CT) angiography for pelvic vessel mapping before the procedure (Figure 1) and pelvic magnetic resonance imaging (MRI) before and 3 months after the procedure.

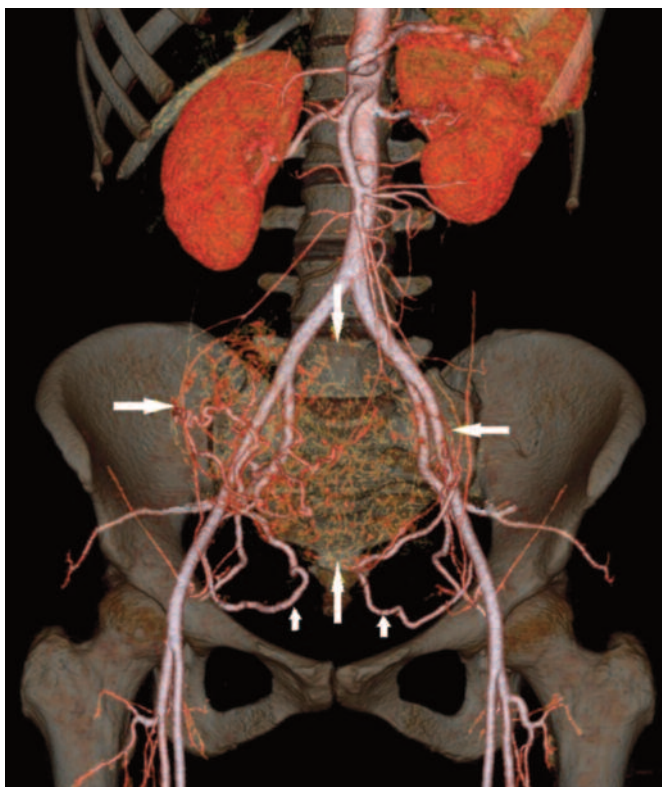


Figure 1. Pelvic CT angiography image of a 35-year-old patient with intramural hypervascular myoma 12 cm in diameter. The branches of the uterine arteries separating from the internal iliac artery (small arrow) and feeding the myoma (big arrow) are clearly seen.

Pelvic MRI investigations included T2W sagittal and axial, T1W sagittal, axial and coronal, and T1W

sagittal, axial, and coronal sequences after an i.v. injection of 0.1 mmol/kg Gadabutrol (Gadovist; Bayer). The patients were called for a follow-up at the postprocedural period in the 1st week and at 3rd, 6th, 9th and 12th months. Imaging was performed with a pelvic MRI at the third month follow-up and pelvic ultrasonography (US) was performed at the other follow-ups. Pelvic MRIs of the patients were analyzed in terms of uterus volume, total myoma volume (total volume of all myomas in the uterus), T2W image signal intensities, contrast enhancement of myomas, and accompanying pathologies.

According to literature data, in patients with pregnancy expectancy, myomectomy is accepted as the first option in myoma treatment [1-6]. Therefore, we directed all patients to surgery who we thought can benefit from myomectomy in preoperative MRI. Since we thought that hysterectomy would also be a cancer protection method, we also directed patients to surgery who are over 42 years old and have no pregnancy expectancy. We operated on only two patients who are over 42 years. Both patients were recently married and haven't got any children. Gynecology consultation was required from all patients. All patients had been recommended a hysterectomy or had been told that hysterectomy could be needed during myomectomy before they were presented at our unit.

Technical success was defined as both uterine arteries being selectively catheterized and all arcuate arteries being embolized at the end of the procedure. Clinical success criteria were a decrease of more than 50% in total myoma volume at the third month follow-up, the disappearance of contrast enhancement of myomas in the MRI, and a decrease in myoma signal intensity in T2W images after the procedure (Figure 2).

All patients were informed on how the myoma embolization procedure would be performed, the expected results, complications, and the alternative treatment methods before the procedure. This was followed by obtaining written consent.

Technique

As it was stated in our previous study [7], all patients received i.v. analgesia (100 mg Tramadol HCl; Contramal) starting half an hour before the procedure and lasting until the postprocedure 12th hour. Local anesthesia and a single femoral artery entry were used in all patients. A 5F Cobra (Cordis, USA) catheter was placed into the uterine arteries with the help of a 0.035" hydrophilic guidewire (Terumo,

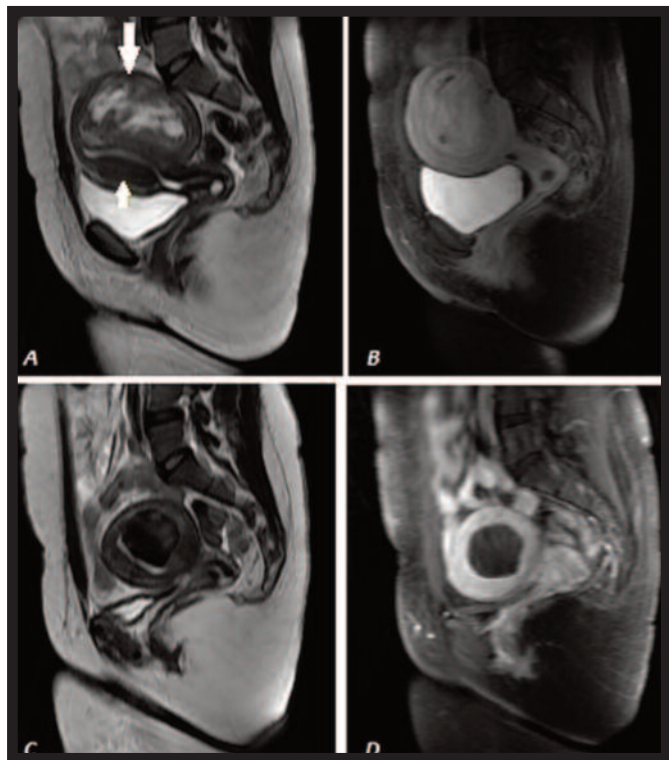


Figure 2. (A) Intramural myomas 4x2 cm in size (big arrow) in the anterior uterus and 8 cm in diameter (small arrow) in the posterior uterus are observed on preoperative sagittal T2W MRI investigation. (B) The myoma is seen to enhance more intensively than the myometrium on preoperative sagittal T1W contrast MRI investigation. (C) The diameter of the posterior myoma has regressed to 3.5 cm and has a homogenous hypointense appearance at the postoperative third-month sagittal T2W MRI investigation. The myoma and myometrium borders are sharpened. The myoma observed anteriorly at the previous investigation has disappeared completely. (D) The myoma has become hypointense due to devascularization at the postoperative third-month sagittal T1W contrast MRI investigation.

Japan). The transverse segment of the uterine artery was accessed using a microcatheter (EmboCath Plus, Biosphere Medical) and 0.018" guidewire (Sequitro, Biosphere Medical) in cases that were challenging due to tortuosity or diameter. After the arcuate arteries were imaged by administering a contrast substance to the uterine artery transverse segment, microparticles (500-700 micron; Embosphere, Biosphere Medical) were injected. If an arterio-arterial shunt was observed, the procedure was started with microparticles 700-900 micron in diameter. The injection was continued until all arcuate arteries were embolized. Later, the same procedures were performed at the contralateral uterine artery so that all arcuate arteries were embolized on both sides. Care was taken to preserve the cervicovaginal artery during the procedure (Figure 3).

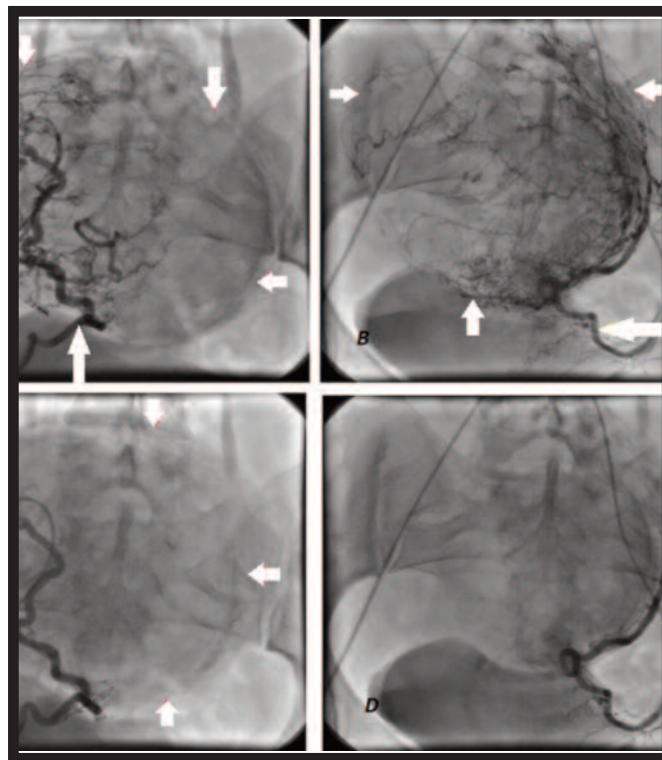


Figure 3. (A) Preoperative angiographic image of the branches of the myoma supplied by the right uterine artery. (B) Preoperative angiographic image of the branches of the myoma supplied by the left uterine artery. (C, D) The branches feeding the myoma from the right and left sides are seen to be completely embolized on postoperative angiographic images (uterine arteries: big arrow, myoma borders: small arrows).

All patients were discharged after fourteen hours. Vaginal bleeding similar to menstruation with occasional particles started a few hours after the procedure and continued for 3 to 6 days in all patients. All patients were administered painkillers (75 mg/day; Diclofenac sodium; Voltaren) orally for one week. None of our cases received prophylactic antibiotics. None of the cases had been presented for infertility treatment.

Statistical Analysis

Mean or median with minimum and maximum values were determined for the demographic data, uterine volume, and amount of embolic agent used. Changes in uterine volume were calculated the Wilcoxon test for paired samples. Statistical significance was accepted at a *p* value less than .05.

Results

The age range of the cases was 22 to 46 years and the mean age was 34 years. All patients were symptomatic and the most common symptom was

menstrual irregularities (n=56, 80%). Other symptoms were anemia (n=46, 65.7%), abdominal pain (n=28, 40%), and mass-related symptoms (palpable mass, frequent urination, constipation, etc.) (n=14, 20%). Most patients had multiple symptoms. All patients had been recommended hysterectomy or had been told that hysterectomy could be needed during myomectomy before they were presented at our unit. A history of myomectomy was present in 9 (12.8%) patients. The postprocedure follow-up duration was 6 to 24 months and the mean follow-up duration was 14 months.

Both uterine arteries were catheterized successfully and all arcuate arteries were embolized in all patients (technical success rate 100%). According to the clinical success criteria provided above, 59 of 70 UAE procedures were accepted as successful after the third month follow-up (clinical success rate of 84.3%). All patients that were clinically successful stated at the third month follow-up that the initial symptoms had disappeared. The procedure was considered a failure in 11 patients as the size of the myoma did not decrease as much as desired, total or

partial contrast enhancement continued, and image intensity did not decrease in T2W images (clinical failure rate of 15.7%). Although some of the cases accepted as clinical failure at third month follow-up stated that their symptoms had decreased, none stated that all symptoms had disappeared. When patients' pre-operation MRIs that were accepted as unsuccessful were examined, it was found that myoma sizes of 6 of them were bigger than 10 cm (average: 13.6 cm), myomas of 4 of them were dyed weak with contrast agent, and the myoma of 1 patient was has intense calcification centers [5, 6].

Mean preprocedure uterus volume on MRI was 404 cm³, and mean preprocedure myoma volume was 280 cm³, while at the third month follow-up the mean uterus volume was 182 cm³ and mean myoma volume was 116 cm³. The largest myoma size in pre-operation MRI examinations of every operated patient is between 3 and 16 cm. The reduction in the total uterus volume was 52.47% and reduction in total myoma volume was 62.14% (Table 1).

The passage of fibroids was seen in two patients

Table 1. Preprocedural and postprocedural changes

	Mean Uterine Volume (ml)	Mean Myoma Volume (ml)
Preoperative	404	280
Postoperative	182	116
Change (decrease percentage)	52.47%	62.14%

(2.85%). Both patients were presented at the third postprocedural week. The first patient had symptoms of malodorous vaginal discharge, pieces of tissue coming from the vagina, cramping abdominal pain, fever, and nausea, while the second patient had symptoms of pieces of tissue coming from the vagina and cramping abdominal pain. Our first patient was hospitalized for intravenous antibiotics and anti-inflammatory treatment administration following hysteroscopy and curettage (Figure 4). Our second patient was only followed-up with oral antibiotics and anti-inflammatory treatment. The symptoms of both patients disappeared during the follow-up. Myomas of both of these patients were submucosal located. In comparative assessment, there was no difference observed in terms of pre-operation fibroid passage formation between other patients with myomas who are successfully operated upon and these patients' pre-operation MRI examinations.

Four patients were hospitalized due to severe hypermenorrhea before the postoperative third month (5.7%). All four were treated with curettage and oral hormonal support treatment. Post-embolization syndrome was seen in six patients (8.5%). Supportive treatment was used for all six. Hysterectomy was not necessary in any of the patients during the postoperative period. Evaluation of the 44 patients with a follow-up duration over 12 months from the 59 patients accepted as clinically successful revealed myoma recurrence and related symptoms in 5. Our myoma recurrence rate at the end of the first year of follow-up in clinically successful patients was therefore 11.36% (n=5). In these patients' examinations, new myomas that weren't seen in their pre-operation MRIs were detected. The UAE procedure was not repeated in any of the patients.

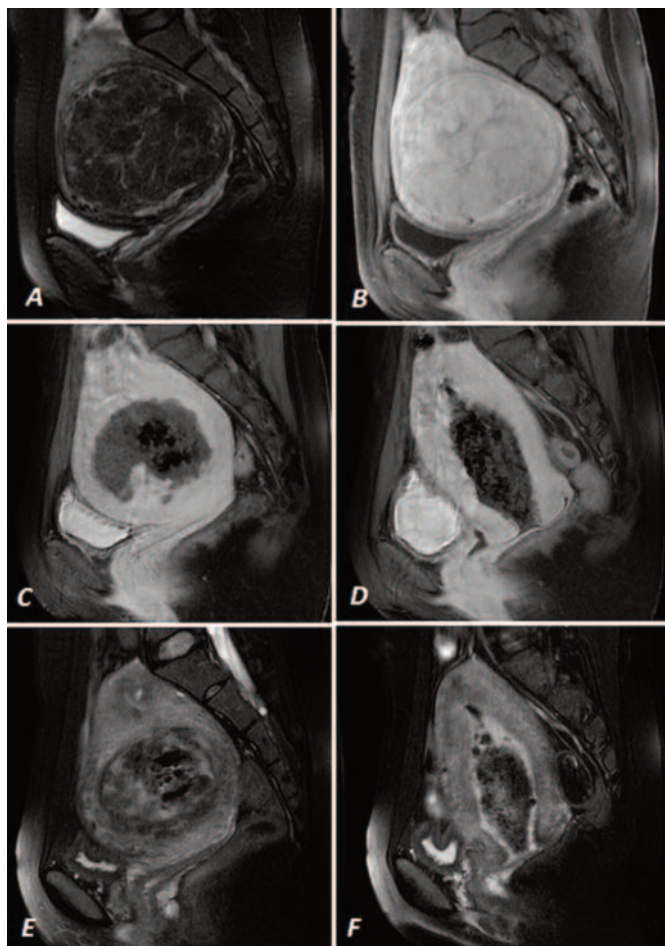


Figure 4. (A) Preoperative T2W and (B) T1W contrast sagittal images of a 41-year-old patient with a myoma 10 cm in diameter. Fibroid passage is observed at (C, D) T1W contrast and (E, F) T2W sagittal images of the case that presented with symptoms of malodorous vaginal discharge, pieces of tissue coming from the vagina, cramping abdominal pain, fever and nausea 3 weeks after the procedure. The air appearance inside the necrotic tissue was interpreted as infection.

Discussion

Uterine myomas are the most common benign tumors of the uterus. Momas can be asymptomatic [7-10]. Symptoms develop according to the localization, number, and size of the myomas. Symptomatic myomas usually cause symptoms of bleeding (irregular, increased or decreased menstrual bleeding, dysmenorrhoea), pain (pelvic area or the back), an abdominal mass (bladder or bowel compression), or infertility [8, 9]. Frequent and severe bleeding (hypermenorrhea) is the most common symptom with a rate of 60%. The hypermenorrhea often causes anemia. Myoma is the accepted cause of only 1% to 2.4% of infertility cases [9]. The symptoms of our patients were similar to those reported in literature and consisted of abdominal pain, mass symptoms, and

most commonly bleeding.

Hysterectomy and myomectomy are the conventional treatment methods for symptomatic myomas [10]. Hysterectomy is the most commonly used myoma treatment method with rates differing between countries. Myomectomy is the second most commonly used method [9, 11]. Observation, medical treatment, endometrial ablation, UAE, and surgical occlusion of the uterine artery and high intensity focused ultrasound (HIFU) are other current treatment options [12]. The number, size, and location of the myomas, the age, number of children, child expectation, previous history of abortion, the severity of the symptoms, the patient's medical condition, the risk of malignancy and proximity to menopause are some of the factors influencing the treatment decision [11]. Hysterectomy is thought to be too radical by most patients because of the loss of fertilization. Myomectomy is recommended in cases where fertility wishes to be preserved [2]. There has been an increasing interest in UAE since 1995, when it began to be used, as it is a minimally invasive procedure [1-8, 13]. Its advantages are lack of an abdominal incision, no need for general anesthesia, short hospitalization duration, and fast recovery time. Obesity, past abdominal surgery, and the number and localization of the myomas do not prevent the UAE procedure, unlike surgery [14].

The aim in UAE is to disrupt the branches feeding the hypervascular myoma with selective embolization of both uterine arteries [3]. The procedure causes devascularization infarction and consequently a reduction in the size of the myoma and a disappearance of the symptoms [8].

Some authors recommend preprocedure pelvic CT angiography to be performed on patients before UAE and the procedure to be planned on the 3D images obtained. The pelvic vascular network, vessel diameters, and the rotation of the digital subtraction angiography tube can be calculated before the procedure and an easier access to the uterine artery ensured [15]. We planned our procedures using 3D images from the preoperative pelvic CT angiogram in all of our cases.

The uterine arteries are characteristically U-shaped, and descending, transverse, and ascending parts are present [3, 6]. The cervicovaginal artery, a major branch of the uterine artery, should be protected during embolization when possible [3]. Particle injection is administered after a catheter is advanced to the transverse segment of the uterine artery for the

UAE procedure [3, 6].

A large number of different materials have been used for embolization. Polyvinyl alcohol (PVA), Gelfoam, and Trisacryl microparticles were the first materials to be used. Microspherical microparticles produced by using various materials are now used more often [16]. We also used microspherical microparticles (Embosphere, Biosphere Medical) in all of our cases. Particles larger than 500 micron are usually recommended as the diameter of the utero-ovarian anastomoses are less than 500 microns. Injection is continued until all branches going to the myoma are obstructed. When the endpoint is reached, the main uterine artery branch appears like a pruned tree [3, 6]. Another endpoint criterion is starting to see the anastomoses between the right and left branches of the uterine artery or between the uterine artery and the ovarian artery that were not observed at the beginning of the procedure (Figure 5).

The reasons for failure of the UAE procedure are the inability to create full blockage in the arteries feeding the myoma due to the anatomy- or operator-

related reasons and consequently a lack of infarction in the myoma. The inability to reach the distal part of the uterine artery, using insufficient amount of embolic agent, the presence of large shunts, and the presence of vascular structures other than the uterine artery feeding the myoma (from the abdominal aorta, cervicovaginal artery, etc.) can also be listed as causes of failure [6, 16, 17]. The most common cause of failure is unilateral embolization [3, 6]. Very large myomas (over 10 cm) respond poorly to embolization due to potential collateral feeding. Multiple myomas respond better to embolization than single myomas. UAE is more effective in small submucosal and intramural myomas [3].

Complications of the UAE procedure are quite rare. The expected complications can be classified into 3 groups as angiography-related (contrast agent allergies, contrast nephropathy, etc.), infection, and embolization-related complications (ovary embolization) [18-20]. One must consider that patients are exposed to radiation during the procedure. The most common complication requiring an intervention

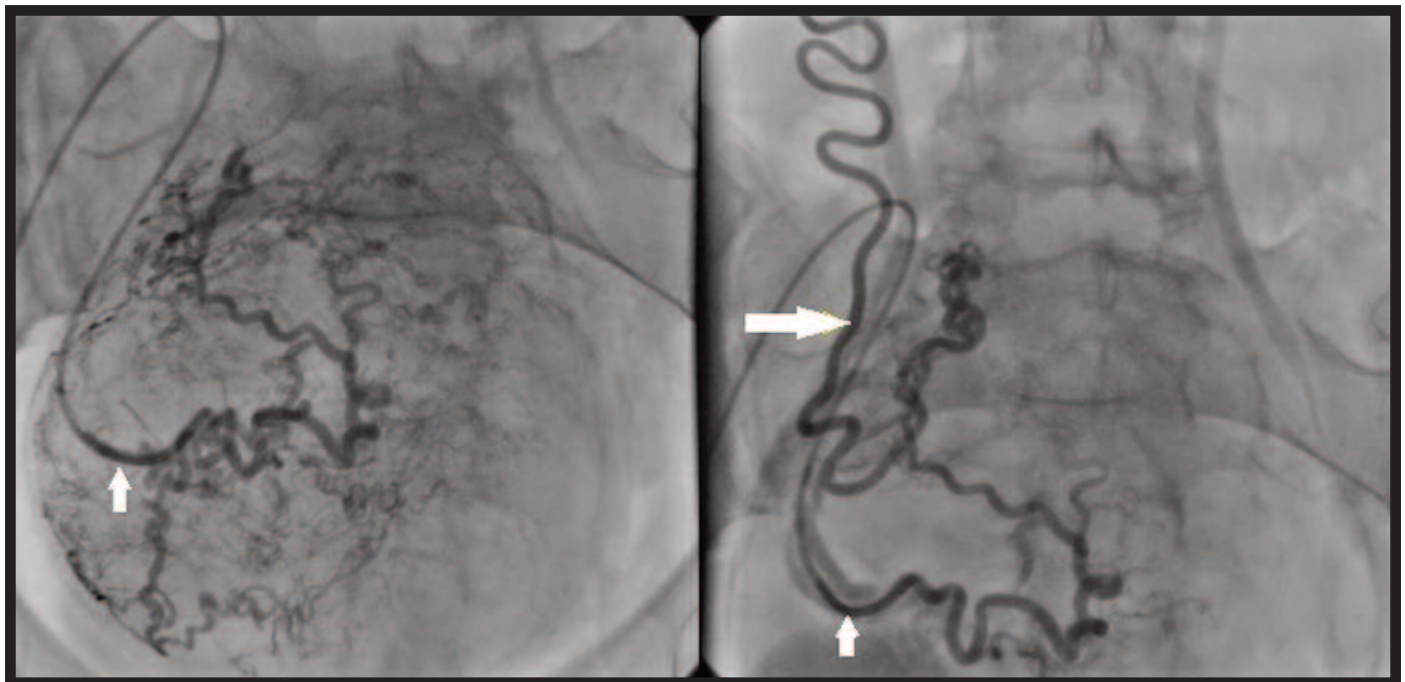


Figure 5. (A) An utero-ovarian anastomosis that was not observed in pre-embolization images of the right uterine artery (small arrow), which was selectively catheterized, (B) has become visible after embolization (big arrow).

is a fibroid passage with an incidence of 4.7% (3.9-5.7%). This condition is due to the migration of intramural and submucous myomas towards the endometrial cavity in the post-embolization period. Ovarian dysfunction characterized by temporary or permanent amenorrhea has been reported at a rate of 3.9% (2.7%-5.3%). Ovarian dysfunction is usually

seen in cases that were older than 45 years at the time they underwent UAE [5, 6, 21]. Non-targeted embolization of organs other than the ovary is a rare complication and the most common examples are vaginal damage and sexual dysfunction, due to embolization of the cervicovaginal branch, and vulvar pain and labia necrosis, due to the embolization of the

internal pudendal artery [6]. Uterine necrosis, endometritis, septic shock, pulmonary embolism, deep vein thrombosis, posterior reversible encephalopathy, and death are very rarely reported complications [3, 6, 22]. In addition to the complications reported in the literature, four of our patients were hospitalized due to severe hypermenorrhea in the first 3 postoperative months (5.7%). All four patients were treated with curettage and oral hormonal support therapy. We did not find any publication regarding this complication in literature. Myomas can cause severe hypermenorrhea even when no procedure is performed so whether our observation is related to the myoma itself or to the procedure is controversial. However, we thought it was as a complication.

The major complication rate of UAE has been reported as 2.9% (2.2%-3.8%) and the postprocedural hysterectomy rate as 0.7% (0.5%-0.9%) in a meta-analysis including 8,159 patients. The clinical-symptomatic improvement rate was 78% to 90% in the 3 months to 2 years of follow-up in that study [21]. No significant difference was found between surgery and UAE in terms of major complication rates in another meta-analysis comparing UAE, hysterectomy, and myomectomy. The 2nd and 5th year patient satisfaction rates were similar with UAE and surgery in this meta-analysis. However, a reintervention was required within 2 years in 7% of surgery patients and 15%-32% of UAE patients [23].

The most common side effect of the procedure is the postprocedural pain described by the patients as uterine cramps. The reason for one night of hospitalization is pain management [24]. We observed that the severity and duration of the pain varied significantly from patient to patient. Another common side effect is vaginal bleeding that starts within hours after the procedure and continues for 1 to 6 days. The amount of vaginal bleeding was from spots to menstrual bleeding in the style of parts dropping. The described vaginal bleeding was seen in all of our patients. Another common side effect of embolization is the post-embolization syndrome. We treated the post-embolization syndrome we observed in 6 of our patients with supportive methods.

Although an increase in the rates of conception has been reported following UAE, obstetric complications such as spontaneous abortion, premature delivery, placental implantation abnormalities, cesarean delivery, and post-partum hemorrhage have also been reported to increase [3, 12, 25]. However, a recent meta-analysis has reported that the evidence

supporting a positive effect of myomectomy on fertility to be more pronounced than with UAE is low quality [23]. The data on performing UAE in patients with an expectation of fertility is controversial [3, 12, 25]. However, considering that hysterectomy causes loss of all fertility, we believe that UAE should be preferred in particular in patients who are recommended hysterectomy or who are predicted to potentially require hysterectomy during myomectomy and who also have an expectation of fertility.

The Limitations of the Study

Though no complications have been identified in our short-term results except for process failure [7], we have observed different complications in this study. This shows that the complications of the process can be identified better with increasing number of patients. The results belong to a limited number of patients undergoing the procedure by the same clinician in a single center. We believe that performance of this procedure in more than one center and with higher number of patients will provide more efficient assessment of the process.

Conclusions

UAE is a reliable alternative to hysterectomy and myomectomy. We believe that UAE should be preferred in particular in patients recommended hysterectomy or predicted to potentially require hysterectomy during myomectomy and who have an expectation of fertility.

Conflict of interest

The authors disclosed no conflict of interest during the preparation or publication of this manuscript.

Financing

The authors disclosed that they did not receive any grant during conduction or writing of this study.

References

- [1] Barnard EP, Abdelmagied AM, Vaughan LE, Weaver AL, Laughlin-Tommaso SK, Hesley GK. Periprocedural outcomes comparing fibroid embolization and focused ultrasound: a randomized controlled trial and comprehensive cohort analysis. *Am J Obstet Gynecol* 2017 Jan 4. pii: S0002-9378(16)46488-4. doi: 10.1016/j.ajog.2016.12.177.

- [2] Bratby MJ, Belli AM. Radiological treatment of symptomatic uterine fibroids. *Best Pract Res Clin Obstet Gynaecol* 2008;22:717-34.
- [3] Dinc H. [Uterine artery embolization]. *Turkiye Klinikleri J Radiol-Special Topics* 2012;5:202-10. [Article in Turkish]
- [4] Lohle PN, Voogt MJ, De Vries J, Smeets AJ, Vervest HA, Lampmann LE, et al. Long-term outcome of uterine artery embolization for symptomatic uterine leiomyomas. *J Vasc Interv Radiol* 2008;19:319-26.
- [5] Torre A, Fauconnier A, Kahn V, Limot O, Bussières L, Pelage JP. Fertility after uterine artery embolization for symptomatic multiple fibroids with no other infertility factors. *Eur Radiol* 2016 Dec 13.
- [6] Pelage JP, Cazejust J, Pluot E, Le Dref O, Laurent A, Spies JB, et al. Uterine fibroid vascularization and clinical relevance to uterine fibroid embolization. *Radiographics* 2005;25:99-117.
- [7] Dogan N, Karatas S, Erdemir M, Kurt O, Baykan D. [Uterine artery embolization for myomas treatment: early results]. *Uludag Univ Tip Fakultesi Dergisi* 2013;39:147-51. [Article in Turkish]
- [8] Voogt MJ, Arntz MJ, Lohle PNM, Mali WPM, Lampmann LEH. Uterine fibroid embolisation for symptomatic uterine fibroids: a survey of clinical practice in Europe. *Cardiovasc Intervent Radiol* 2011;34:765-73.
- [9] Boosz AS, Reimer P, Matzko M, Romer T, Muller A. The conservative and interventional treatment of fibroids. *Dtsch Arztebl Int* 2014;111:877-83.
- [10] Tomislav S, Josip M, Liana CS, Marko V, Marko J, Ante R, et al. Uterine artery embolization as nonsurgical treatment of uterine myomas. *ISRN Obstet Gynecol* 2011;23:489281.
- [11] Duhan N. Current and emerging treatments for uterine myoma - an update. *Int J Womens Health* 2011;3:231-41.
- [12] Parker WH. Uterine myomas: management. *Fertil Steril* 2007;88:255-71.
- [13] Ravina JH, Herbreteau D, Ciraru-Vigneron N, Bouret JM, Houdart E, Aymard A, et al. Arterial embolisation to treat uterine myomata. *Lancet* 1995;346:671-2.
- [14] Mara M, Horak P, Kubinova K, Dundr P, Belsan T, Kuzel D. Hysteroscopy after uterine fibroid embolization: evaluation of intrauterine findings in 127 patients. *J Obstet Gynaecol Res* 2012;38:823-31.
- [15] Liu R, Dai E, Chen C, Liu P. [Application of in vivo pelvis and abdominal-pelvic arterial network digital three-dimensional model for uterine artery embolization in surgical approach planning]. *Zhonghua Fu Chan Ke Za Zhi* 2014;49:89-93. [Article in Chinese]
- [16] Stampfl U, Radeleff B, Sommer C, Stampfl S, Dahlke A, Bellemann N, et al. Midterm results of uterine artery embolization using narrow-size calibrated embosphere microspheres. *Cardiovasc Intervent Radiol* 2011;34:295-305.
- [17] Ustunsoz B, Ugurel MS, Bozlar U, Duru NK, Ustunsoz A. Is uterine artery embolization prior to myomectomy for giant fibroids helpful? *Diagn Interv Radiol* 2007;13:210-12.
- [18] Greenwood LH, Glickman MG, Schwartz PE, Morse SS, Denny DF. Obstetric and nonmalignant gynecologic bleeding: treatment with angiographic embolization. *Radiology* 1987;164:155-9.
- [19] Abbas FM, Currie JL, Mitchell S, Osterman F, Rosenshein NB, Horowitz IR. Selective vascular embolization in benign gynecologic conditions. *J Reprod Med* 1994;39:492-6.
- [20] Stringer NH, Grant T, Park J, Oldham L. Ovarian failure after uterine artery embolization for treatment of myomas. *J Am Assoc Gynecol Laparoscopist* 2000;7:395-400.
- [21] Toor SS, Jaber A, Macdonald DB, McInnes MD, Schweitzer ME, Rasuli P. 2012. Complication rates and effectiveness of uterine artery embolization in the treatment of symptomatic leiomyomas: a systematic review and meta-analysis. *AJR Am J Roentgenol* 2012;199:1153-63.
- [22] Suzuki S, Tanigawa N, Kariya S, Komemushi A, Kojima H, Tokuda T, et al. Posterior reversible encephalopathy syndrome occurring after uterine artery embolization for uterine myoma. *Cardiovasc Intervent Radiol* 2011;34:157-60.
- [23] Gupta JK, Sinha A, Lumsden MA, Hickey M. Uterine artery embolization for symptomatic uterine fibroids. *Cochrane Database Syst Rev* 2014;12:CD005073.
- [24] Bakri YN, Linjawi T. Angiographic embolization for control of pelvic genital tract hemorrhage. Report of 14 cases. *Acta Obstet Gynecol Scand* 1992;71:17-21.
- [25] Usadi RS, Marshburn PB. The impact of uterine artery embolization on fertility and pregnancy outcome. *Curr Opin Obstet Gynecol* 2007;19:279-83.