

## PAPER DETAILS

TITLE: Chondroid syringoma of the upper lip: a case report

AUTHORS: Osman Kürsat ARIKAN,Sibel ERDOGAN,Nuray BAYAR MULUK,Can KOÇ

PAGES: 25-27

ORIGINAL PDF URL: <https://dergipark.org.tr/tr/download/article-file/2155454>

CASE REPORT

## Chondroid syringoma of the upper lip: a case report

### Üst dudağın kondroid siringoması: Olgu sunumu

Osman Kürşat ARIKAN, M.D.,<sup>1</sup> Sibel ERDOĞAN, M.D.,<sup>2</sup> Nuray Bayar MULUK, M.D.,<sup>1</sup> Can KOÇ, M.D.<sup>1</sup>

Chondroid syringoma (mixed tumour of the skin) is a rare benign neoplasm of the sweat glands which often occurs in the head and neck region. We present a 73-year-old white farmer man with a mass of anterior surface of the upper lip that was histologically diagnosed as chondroid syringoma after surgical wide excision. There has been no signs of recurrence during a follow-up of 14 months.

**Key Words:** Adenoma; sweat gland/pathology; lip neoplasms/pathology/surgery.

Kondroid siringoma (derinin mikst tümörü) sıklıkla baş-boyun bölgesinde ortaya çıkan, ter bezlerinin nadir görülen benign bir neoplazisidir. Üst dudağının ön yüzünde kitlenin geniş cerrahi eksizyonu sonrası histolojik tanısı kondroid siringoma olan 73 yaşında yaşlı, beyaz, çiftçi bir erkek olgu sunuldu. On dört aylık takip süresi boyunca rekürrens bulgusu görülmedi.

**Anahtar Sözcükler:** Adenom; ter bezi/patoloji; dudak neoplazileri/patoloji/cerrahi.

The chondroid syringoma is a benign mixed tumour of the skin characterized by a mixture of epithelial and mesenchymal tissues.<sup>[1]</sup> These lesions usually have the appearance of slow-growing, painless swelling, subcutaneous, or intracutaneous nodules in the head and neck region between the ages of 20-70 years, with a distinct male predominance.<sup>[2]</sup> We report a case of chondroid syringoma which involved the upper lip.

#### CASE REPORT

The patient, a 73-year-old farmer man, presented with an asymptomatic mass in the anterior surface of the upper lip on February 15, 2002. The lesion had been present for 3 years before admission with slow rate of growth. On physical examination, it was

firm, lobulated, measuring 1.5x1x1 cm, painless on palpation, adherent to the surrounding skin but there was no associated skin punctum (Fig. 1). There was no lymphadenopathy in the neck.

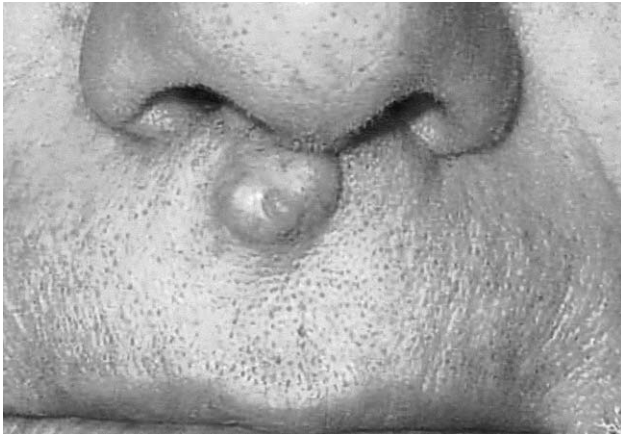
Under local anaesthesia, the lesion was completely excised, together with a 5-mm margin of normal tissue. The wound was closed primarily and healing was uneventful. There had been no signs of recurrence during a follow-up of 14 months.

The histopathologic examination of the lesion revealed, embedded in chondromyxoid stroma, were epithelial cells arranged in sheets, columns, small nests, large aggregates and double layered tubular structures (Fig. 2).

◆ Departments of <sup>1</sup>Otolaryngology and <sup>2</sup>Pathology, Medicine Faculty of Kırıkkale University (Kırıkkale Üniversitesi Tıp Fakültesi <sup>1</sup>KBB Hastalıkları ve Baş-Boyun Cerrahisi Anabilim Dalı, <sup>2</sup>Patoloji Anabilim Dalı), Kırıkkale, Turkey.

◆ Received - June 10, 2003 (Dergiye geliş tarihi - 10 Haziran 2003). Accepted for publication - January 9, 2004 (Yayın için kabul tarihi - 9 Ocak 2004).

◆ Correspondence (İletişim adresi): Dr. Osman Kürşat Arıkan. Eryaman Toplu Konut, Altay Mah. 26. Sok. No: 151/6, 06793 Etimesgut, Ankara, Turkey. Tel: +90 318 - 225 24 85 / 172 Fax (Faks): +90 318 - 225 28 19 e-mail (e-posta): osman.arikan@gediknet.com



*Fig. 1 - An asymptomatic tumour in the anterior surface of the upper lip.*

### DISCUSSION

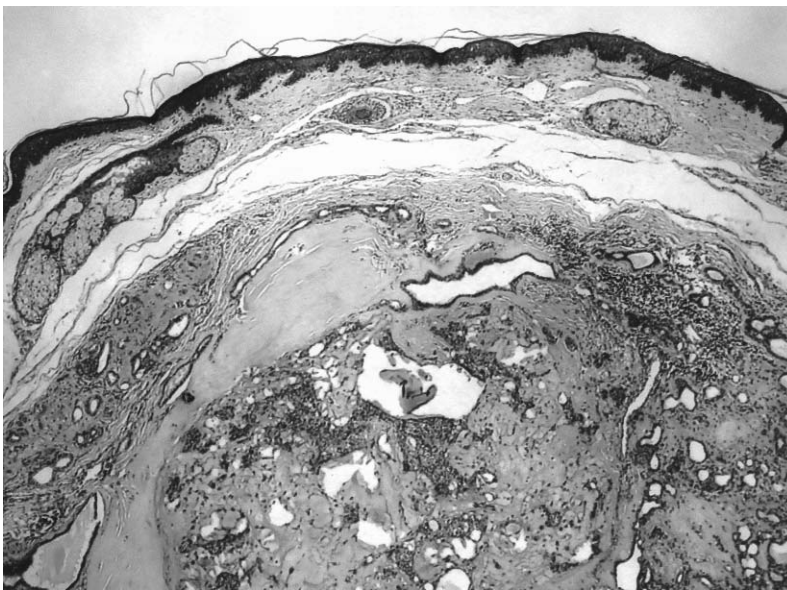
Chondroid syringoma is a benign skin tumour characterized by several histological aspects similar to salivary gland adenomas. They derived from epithelial appendages.<sup>[3]</sup> It was first suggested as a name for the mixed tumour of skin by Hirsch and Helwig.<sup>[1]</sup> The tumour develops from eccrine or apocrine glands and seen mainly in the head and neck region between the ages of 20 and 70 years.<sup>[2,3]</sup> Of 16.200 skin lesions, Yavuzer et al.<sup>[4]</sup> found the histopathologic diagnosis of chondroid syringoma in 16 cases (0.098%). After the nose and the skin of the cheek, the upper lip is the most common anatomic location for the development of chondroid

syringoma.<sup>[1]</sup> Its incidence in males is twice as high as in females.<sup>[5]</sup> The neoplasm is usually an asymptomatic, benign, painless, slow-growing, subcutaneous or intracutaneous nodule that patients want to be removed for aesthetic reasons.

The biologic behavior of chondroid syringoma is benign but a few cases of malignant tumour have been reported.<sup>[6]</sup> The malignant neoplasm tends to produce metastases to both the regional and distant lymph nodes.

Because chondroid syringomas are rare and have not pathognomonic clinical characteristics, they are often overlooked and the lesion can be confused with a dermoid or sebaceous cyst, compound nevus, basal cell carcinoma, neurofibroma, histiocytoma, pilomatricoma, dermatofibroma and seborrheic keratosis.<sup>[2,4]</sup> Fine-needle aspiration cytology has also been described for the diagnosis but such a small lesion remained ineffective.<sup>[2]</sup> It is therefore clear that the definitive diagnosis can be established only by histopathologic examination.

Histologically, chondroid syringoma correspond to the so-called pleomorphic adenoma of the skin. It is essentially an epithelial lesion characterised by tubuloalveolar and gland-like structures with two or more cuboidal cell lines, islands of cuboidal or polygonal cells in a fibroadipoid, chondroid, hyaline or mucinous stroma.<sup>[2,7]</sup> Malignant change in a chondroid syringoma is rare. On microscopic examina-



*Fig. 2 - Beneath the overlying epidermis, localised in dermis, the lesion shows chondromyxoid stroma aggregates and columns of epithelial cells (H-E x 100).*

tion, cytologic atypia, infiltrative margins, increased mitotic figures and tumour necrosis are considered as the signs of malign transformation.<sup>[8]</sup>

The treatment of choice is local excision. Recurrences are attributed to inadequate surgical excision. If the tumour has been completely excised and is benign, long-term follow-up is not indicated. Our patient has been free of recurrence for 14 months after since the operation.

In the evaluation of an elderly male patient with a firm, slow-growing and painless mass, chondroid syringoma should be included in the differential diagnosis of lesions of the head and neck region.

#### REFERENCES

1. Hirsch P, Helwig EB. Chondroid syringoma. Mixed tumor of skin, salivary gland type. *Arch Dermatol* 1961;84:835-47.
2. Chen AH, Moreano EH, Houston B, Funk GF. Chondroid syringoma of the head and neck: clinical management and literature review. *Ear Nose Throat J* 1996;75:104-8.
3. Triantafyllou AG, Rapidis AD. Chondroid syringoma of the upper lip: report of a case. *J Oral Maxillofac Surg* 1986;44:744-8.
4. Yavuzer R, Basterzi Y, Sari A, Bir F, Sezer C. Chondroid syringoma: a diagnosis more frequent than expected. *Dermatol Surg* 2003;29:179-81.
5. Stout AP, Gorman JG. Mixed tumors of the skin of the salivary gland type. *Cancer* 1959;12:537-43.
6. Harrist TJ, Aretz TH, Mihm MC Jr, Evans GW, Rodriguez FL. Cutaneous malignant mixed tumor. *Arch Dermatol* 1981;117:719-24.
7. Adlam DM, Wood GA. The chondroid syringoma (mixed tumor of skin). Report of a case in the upper lip. *Oral Surg Oral Med Oral Pathol* 1986;61:69-72.
8. Barnett MD, Wallack MK, Zuretti A, Mesia L, Emery RS, Berson AM. Recurrent malignant chondroid syringoma of the foot: a case report and review of the literature. *Am J Clin Oncol* 2000;23:227-32.