

PAPER DETAILS

TITLE: Coexistence of actinomycosis and sialolithiasis in the submandibular gland

AUTHORS: Celil USLU,Çagatay OYSU,Burak ÜLKÜMEN

PAGES: 257-259

ORIGINAL PDF URL: <https://dergipark.org.tr/tr/download/article-file/2155800>

CASE REPORT

Coexistence of actinomycosis and sialolithiasis in the submandibular gland

Submandibuler bezde birlikte bulunan aktinomikoz ve taş

Celil USLU, M.D., Çağatay OYSU, M.D., Burak ÜLKÜMEN, M.D.

Actinomycosis of the submandibular gland is unusual. A 55-year-old male presented with a right, painless submandibular mass of four-year duration. Physical examination revealed a 4x3-cm mass in the submandibular region. Ultrasonography-guided fine needle aspiration from the lesion showed microorganisms compatible with actinomyces colonies in the glandular tissue. The diagnosis was made as actinomycosis of the right submandibular gland accompanied by sialolithiasis. The patient was treated with penicillin G (10 million U/day) for three months, followed by 3 g/day oral penicillin for six months. After this medication, physical examination showed no decrease in the size of the mass and the clinical features remained unchanged. Submandibular gland excision under general anesthesia was performed.

Key Words: Actinomycosis; salivary gland calculi; submandibular gland.

Submandibuler bez aktinomikozu nadir bir durumdur. Elli beş yaşında erkek hasta sağ tarafta dört yıldır var olan ağrısız submandibuler kitle ile başvurdu. Fiziksel muayene sonucunda submandibuler bölgede 4x3 cm boyutlarında kitle saptandı. Ultrasonografi kılavuzluğunda yapılan ince iğne aspirasyonu incelemesinde, glandüler dokuda aktinomikoz kolonileriyle uyumlu mikroorganizmalar görüldü. Sağ submandibuler bezde taş ile birlikte aktinomikoz tanısı kondu. Hastaya üç ay boyunca penisilin G (günde 10 milyon U) tedavisi, ardından altı ay süren günde 3 g oral penisilin tedavisi uygulandı. Tedaviden sonra fiziksel muayenede kitlenin boyutunun azalmadığı gözlemlendi. Klinik özelliklerde değişme olmadığından genel anestezi altında submandibuler bez eksizyonu uygulandı.

Anahtar Sözcükler: Aktinomikoz; submandibuler bez; tükürük bezi taşı.

Actinomycosis is a chronic suppurative infection characterized by formation of multiple abscesses, draining sinuses, and abundant granulation tissue. The most common site of infection is the cervicofacial region (55%), followed by the abdominopelvic region (25%), pulmonothoracic region (15%), and other locations (5%).^[1] The submandibular region, parotid gland and buccal space are the most common sites of cervicofacial actinomycosis, but primary involvement of the submandibular gland is considered to be

infrequent.^[2] Furthermore, sialolithiasis accompanying actinomycosis in the submandibular gland is a rare condition.^[1,3]

We presented a rare case of actinomycosis of the submandibular gland associated with sialolithiasis.

CASE REPORT

A 55-year-old male presented to our outpatient clinic with a right, painless, submandibular mass of four-year history. The patient complained of occasional

♦ Department of Otolaryngology, Haydarpaşa Numune Training and Research Hospital (Haydarpaşa Numune Eğitim ve Araştırma Hastanesi Kulak Burun Boğaz Hastalıkları Kliniği), İstanbul, Turkey.

♦ Received - June 20, 2006 (Dergiye geliş tarihi - 20 Haziran 2006). Request for revision - April 9, 2007 (Düzeltilme isteği - 9 Nisan 2007). Accepted for publication - May 1, 2007 (Yayın için kabul tarihi - 1 Mayıs 2007).

♦ Correspondence (İletişim adresi): Dr. Celil Uslu. Haydarpaşa Numune Eğitim ve Araştırma Hastanesi, 1. Kulak Burun Boğaz Hastalıkları Kliniği. 34668 Üsküdar, İstanbul, Turkey. Tel: +90 216 - 414 45 02 / 1743 Fax (Faks): +90 216 - 336 05 65 e-mail (e-posta): celiluslu@hotmail.com

pain. He had no other medical evaluation or therapy before. Physical examination revealed a 4x3-cm mass in the submandibular region. The swelling was confined to the submandibular region and the rest of the face appeared normal. There were no palpable cervical lymph nodes. He was a heavy smoker. He had a history of right molar tooth extraction two years before. He was neither diabetic nor immunocompromised.

Nasal and laryngeal endoscopic examination was normal. Routine investigations including blood count, erythrocyte sedimentation rate, and chest X-ray were normal. Axial computed tomography (CT) showed a 10-mm hyperdense, well-delineated formation just medial to the body of the mandible, consistent with a sialolith (Fig. 1). Diffuse hypertrophy of the right submandibular gland was also noticeable. Ultrasonography-guided fine needle aspiration from the lesion showed microorganisms with a filamentous appearance compatible with actinomyces colonies in the glandular tissue. The diagnosis was made as actinomycosis of the right submandibular gland accompanied by sialolithiasis.

The patient was treated with penicillin G (10 million U/day) for three months followed by 3 g/day oral penicillin for six months. After this medication, physical examination showed no decrease in the size of the mass and the clinical features remained unchanged. Submandibular gland excision under general anesthesia was performed.

DISCUSSION

Actinomycosis is an infection due to *Actinomyces israeli*. This commensal organism is found at high amounts in tonsil tissue, carious teeth, and is regarded as an opportunistic pathogen. Predisposing factors such as poor oral hygiene, diabetes, immune suppression, malnutrition, and local tissue damage may lead to infection and subsequent invasion of subcutaneous tissues. In our case, the predisposing factor was thought to be either the tooth extraction procedure or the occurrence of sialolithiasis.^[4]

The disease is most often seen in the submandibular area of the cervicofacial region, yet primary involvement of submandibular gland is relatively uncommon. Moreover, coexistence of actinomycosis and sialolithiasis has been reported in only one case.^[2]

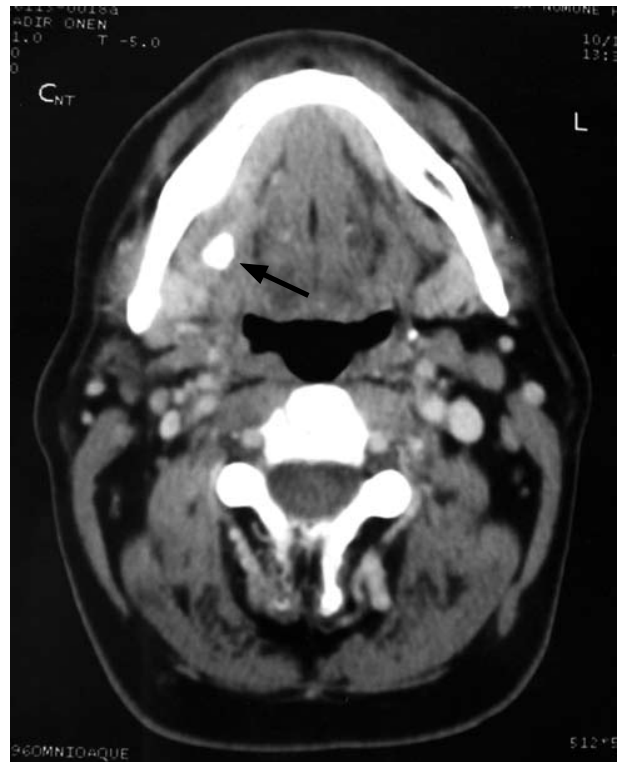


Fig. 1. Computed tomography scan of the right submandibular gland showing the calculus (arrow) and diffuse hypertrophy.

In the majority of reported cases, cervicofacial actinomycosis presents as a firm, painless, slow-growing swelling and a multiloculated abscess which frequently progresses to multiple discharging sinuses.^[3] We did not observe any of these findings in our case, except for a firm mass.^[5]

Diagnosis of actinomycosis infection is challenging because it is difficult to isolate *A. israeli*. For this reason, when actinomycosis is suspected, fine needle aspiration, smears of freshly obtained pus, standard culture swabs, and special stains for fungi are required.^[3] Early sampling is necessary for appropriate identification of the organism with the appearance of sulfur granules, suggesting actinomycosis infection as in our case. Debridement and/or excision are often necessary. Antimicrobial therapy should be used for six to twelve months to completely eradicate the disease and to prevent recurrence.

In conclusion, association of actinomycosis and sialolithiasis involving the submandibular gland is a rare condition. It should be borne in mind that sialolithiasis may be a predisposing factor for subman-

dibular actinomycosis and removal of the sialolith or the entire gland is of paramount importance.

REFERENCES

1. Allen HA 3rd, Scatarige JC, Kim MH. Actinomycosis: CT findings in six patients. *AJR Am J Roentgenol* 1987;149:1255-8.
2. Guiral H, Risco J, Mayayo E. Submaxillary sialolithiasis due to *Actinomyces israeli*. A case report. *An Otorrinolaringol Ibero Am* 1998;25:247-53. [Abstract]
3. Oysu C, Uslu C, Guclu O, Oysu A. Actinomycotic abscess of the thyroid gland in an infant. *Int J Pediatr Otorhinolaryngol* 2005;69:701-3.
4. Cevera JJ, Butehorn HF 3rd, Shapiro J, Setzen G. Actinomycosis abscess of the thyroid gland. *Laryngoscope* 2003;113:2108-11.
5. Gaffney RJ, Walsh MA. Cervicofacial actinomycosis: an unusual cause of submandibular swelling. *J Laryngol Otol* 1993;107:1169-70.