

PAPER DETAILS

TITLE: The effect of tumor width and depth on extracapsular lymph node metastases in tongue tumors

AUTHORS: Murat ULUSAN,Murat ENÖZ,Tolgar Lütfi KUMRAL,Yusufhan SÜOGLU

PAGES: 18-24

ORIGINAL PDF URL: <https://dergipark.org.tr/tr/download/article-file/2155846>

The effect of tumor width and depth on extracapsular lymph node metastases in tongue tumors

Dil tümörlerinde, tümör genişliğinin ve derinliğinin metastatik lenf nodundaki ekstrakapsüler yayılıma olan etkisi

Murat Ulsan, M.D.,¹ Murat Enöz, M.D.,² Tolgar Lütü Kumral, M.D.,³ Yusufhan Süoğlu, M.D.⁴

¹Department of Otolaryngology, Diyarbakır Training and Research Hospital, Diyarbakır, Turkey

²Department of Otolaryngology, Yenibosna Safa Hospital, İstanbul, Turkey

³Department of Otolaryngology, Haseki Training and Research Hospital, İstanbul, Turkey

⁴Department of Otolaryngology, Medicine Faculty of İstanbul University, İstanbul, Turkey

Objectives: In this study, we investigate the relationship between the effects of tumor width and depth with the extracapsular nodal spread (ECS) in oral tumors.

Patients and Methods: In this study we investigate retrospectively data of 107 patients (69 males, 38 females; mean age 45 years; range 25 to 79 years) with tongue tumors, who had undergone surgery in our clinic, between 1994 and 2004. Twenty one of them had ECS. The effects of tumor width and depth on various parameters such as nodal metastases, survival, grade and ECS are investigated.

Results: It was found that tumor width and depth were the most important factors that affect ECS and logistic regression analysis point out tumor width influence more than tumor depth. Receiver operating characteristic (ROC)-curve analysis shows us when tumor width exceeds 3.7 cm or tumor depth exceeds 2.4 cm, rate of ECS reaches the maximum sensitivity and specificity.

Conclusion: Tumor width and depth has affects on survival and prognosis but also they have significant relation with ECS.

Key Words: Extracapsular spread; tongue tumor; tumor width/depth.

Amaç: Bu çalışmada dil kanserinde tümör genişliği ve derinliğinin ekstrakapsüler nodal yayılım (EKY) ile olan ilişkisi incelendi.

Hastalar ve Yöntemler: Bu çalışmada kliniğimizde dil tümörü nedeniyle 1994-2004 yılları arasında ameliyat edilmiş olan 107 olgunun (69 erkek, 38 kadın; ort. yaş 45 yıl; dağılım 25-79 yıl) verileri geriye yönelik olarak incelendi. Olguların 21'inde EKY vardı. Tümörün genişliğinin ve derinliğinin nodal yayılım, sağkalım, evre, EKY gibi çeşitli faktörlere olan etkisi araştırıldı.

Bulgular: Tümör genişliği ve derinliğinin ekstrakapsüler yayılıma en çok etki eden faktörler olduğu tespit edildi. Bu iki parametrenin lojistik regresyon analiziyle karşılaştırılması sonucu tümörün genişliğinin, derinlikten daha önemli olduğu görüldü. ROC (receiver operating characteristic) eğrisi incelemesinde tümörün genişliği 3.7 cm'yi, derinliği ise 2.4 cm'yi geçtiğinde EKY açısından maksimum duyarlılık ve özgüllüğe ulaştı.

Sonuç: Sonuç olarak, tümör genişliği ve derinliğinin prognoz ve sağkalım üzerine etkileri olduğu gibi; EKY ile de aralarında anlamlı bir ilişki vardır.

Anahtar Sözcükler: Ekstrakapsüler yayılım; dil kanseri; tümör genişliği/derinliği.

Oral cavity cancer constitutes 30% of head and neck cancers, among them tongue tumors are the most frequent ones. Tongue is made of muscle and vessels, so there aren't enough barriers to resist tumor spread, because of this tongue tumors behave locally aggressive and early regional metastases seen. The most important factor that decreases life expectancy in patients has shown as cervical metastases by many studies.^[1] In this manner, the researches try to find the factors related to the regional spread. Lots of histopathological and clinical parameters found but still the question which factor most and what to do with neck not answered precisely. Recent publications especially focused on the parameters with the tumor itself, as width and depth.^[2]

The extracapsular spread (ECS) is the second problem with neck metastases. It decreases survival more and increases likelihood of recurrence, distant metastases. It is hard to diagnose ECS pre-operative correctly. The diameter of lymph node doesn't always direct relationship to ECS; when lymph node diameter exceeds 3 cm, likelihood of ECS presence increases approximately two times but 29% ECS still seen in lymph nodes <1 cm diameter.^[3] This shows us we can easily miss an aggressive neck disease with only looking at node's size. There are also radiological criterias for ECS presence as; axial size of more than 10 mm, reduction in the ratio of maximal longitudinal to axial diameter, presence of three or four enlarged lymph nodes and rim enhancement with a central area of low attenuation; but these are not specific.^[4]

In our research we try to delineate the factors that affect prognosis for tongue tumors and show which factor is the most important in ECS. Until now there are many researches made about prognostic factors and effects of ECS in tongue tumors^[1-12] but there are only few researches exist about the factors acting on ECS^[13] and the connection of tumor width and depth to ECS in tongue tumors. Also, we want to find a parameter of primary tumor that will give us a clue that if there is a metastatic lymph node with ECS exists, also try to measure the cut off value of width and depth that warns us about ECS.

PATIENTS AND METHODS

Patient

We evaluate retrospectively data and histological slides of 107 patients (69 males 38 females;

mean age: 45 years; range 25 to 79 years) with tongue cancers operated between 1994-2004 in İstanbul University, İstanbul Medical Faculty Hospital. Clinicopathological features including age, sex, tobacco/alcohol consumption, denture usage, histology, tumor width and depth, cervical metastases, histological grades evaluated and correlations with extracapsular neck metastases were determined. TNM (Tumor-node-metastasis) classification of AJCC 5th edition is used and graded as grade I well, grade II moderately, grade III poorly differentiated.^[5]

Only the patients who had completed two years of follow-up were included in study. All surgical margins were clear. Histologically patients grouped as squamous cell carcinoma and others (adenocystic, mucoepidermoid, adenocarcinoma, etc.).

The status of patient is recorded as alive with disease, live with recurrence, alive without disease, live without recurrence.

Institutional review board approved for this study and informed consent were obtained from all patients before enrollment of these data.

Histological

The histopathological data and measurements of tumor width and depth were obtained by studying tissue sections of the operative specimens, using hematoxylin-eosin stain. With optical micrometer we measure tumor width as maximum tumor diameter in horizontal plane and tumor depth as maximum diameter in vertical plane, beginning from mucosa to the deepest part tumor reaches,^[6] in ulcerative ones an imaginary line drawn indicating intact mucosa.^[7]

According to width as;

- 1) 1 cm and less
- 2) 1-2 cm
- 3) 2-3 cm
- 4) 3-4 cm
- 5) 4 cm and more

According to depth as;

- 1) 1 cm and less
- 2) 1-2 cm
- 3) 2-3 cm
- 4) 3 cm and more

Table 1. The TNM staging (there were no M1 and N3 cases)

	N0	N1	N2	Total
T1	34	1	1	36
T2	29	10	6	45
T3	2	1	3	6
T4	5	2	13	20
Total	70	14	23	107

T: Pathologic T; N: Pathologic N; M: Metastasis.

The SPSS 13.0 version software package (SPSS Inc., Chicago, Illionis, USA) was used to analyse results. The relation between ECS and TNM, grade, tumor width and depth, cervical metastases, recurrence, survival, smoking, denture, alcohol analysed with cross-tabulations (Chi-square, Fischer's exact test) and independent t-tests. The variables that affect ECS evaluated by receiver operating characteristic (ROC) curve and logistic regression analysis. $P < 0.05$ were considered statistically significant.

RESULTS

Data of 107 patients with tongue tumors that had undergone neck dissections analysed. Sixty-seven patients operated with transoral route and 40 operated via trans-mandibular way. Pediculated or free flaps used in 10 patients. Tracheostomy was done in 43 (40.2%) patients. Seventy-six (71%) of patients were smoker, 32 (29.9%) have alcohol history and 34 patients (31.8%) used denture. Eighty eight (82.2%) of tumors were squamous cell carcinoma histology, 19 had others like adenocarcinoma, adenocystic carcinoma, mucoepidermoid

Table 2. Tumor width and depth to nodal metastases relation ($p < 0.05$)

	No metastasis		Unilateral		Bilateral	
	n	%	n	%	n	%
Width						
0-1 cm	13	100	–	–	–	–
1.1-2 cm	19	82	4	18	–	–
2.1-3 cm	21	80	5	20	–	–
3.1-4 cm	11	58	6	31	2	11
>4 cm	6	23	16	61	4	16
Depth						
0-1 cm	30	83	6	17	–	–
1.1-2 cm	21	70	9	30	–	–
2.1-3 cm	14	54	9	34	3	12
>3 cm	5	33	7	46	3	21

carcinoma. Twenty seven (25%) of the tumors are grade I, 62 (57.9%) grade II and 18 (16.8%) grade III. TNM staging of patients showed in Table 1.

Bilateral cervical metastases

Bilateral neck metastases found in six (5.6%) of patients, unilateral neck metastases found in 31 (28.9%) patients and in 70 (65.4%) patients had no regional metastases. Both tumor width and depth has affects on bilaterality ($p < 0.05$; Table 2).

Extracapsular spread

Twenty one (19.6%) had extracapsular spread. Authors also looked at which factors affect extracapsular spread and we compare them. There isn't any statistical relationship between ECS and sex ($p = 0.78$), smoke ($p = 0.62$), alcohol ($p = 0.36$), denture ($p = 0.86$), histology ($p = 0.08$) and grade ($p = 0.17$). Age has significant relation ($p = 0.042$; Table 3). Tumor width and depth are the most important factors that influence ECS (Table 3; Fig 1, 2). When tumor width exceeds 4 cm, 58% ECS seen in pathologic lymphnodes and if tumor depth is more than 3 cm 47% ECS seen. When we compare the factors with logistic regression analysis and multivariate analysis tumor width is the main factor acting on ECS.

Survival, recurrence

Fifty-two (48.5%) of patients had recurrence, metastasis or death due to tumor; 55 patients (51.4%) have no recurrence or metastasis.

Table 3. The relation of tumor width, depth, age and ECS

	n (-)	%	n (+)	%
Width				
0-1 cm	13	100	–	–
1.1-2 cm	23	100	–	–
2.1-3 cm	24	92	2	8
3.1-4 cm	15	79	4	21
>4 cm	11	42	15	58
Depth				
0-1 cm	35	97	1	3
1.1-2 cm	25	83	5	17
2.1-3 cm	18	69	8	31
>3 cm	8	53	7	47
Age				
20-40	9	90	1	10
41-50	20	83	4	17
51-60	35	90	4	10
>60	22	65	12	35

ECS: Extracapsular spread; n (-): Number of ECS (-) patients; n (+): Number of ECS (+) patients.

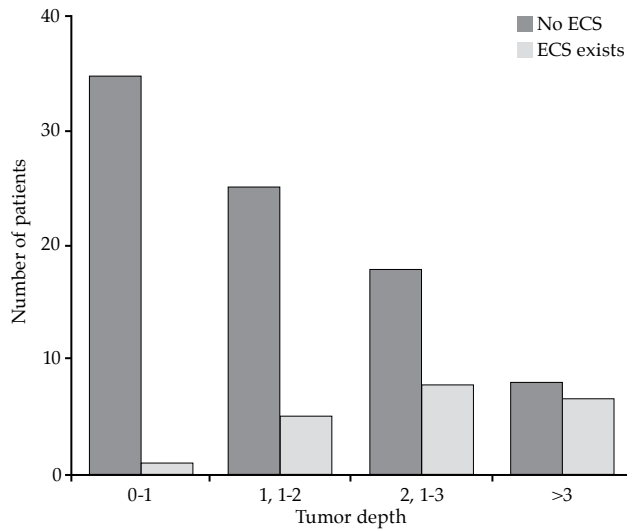


Figure 1. Extracapsular spread-tumor depth. ECS: Extracapsular spread.

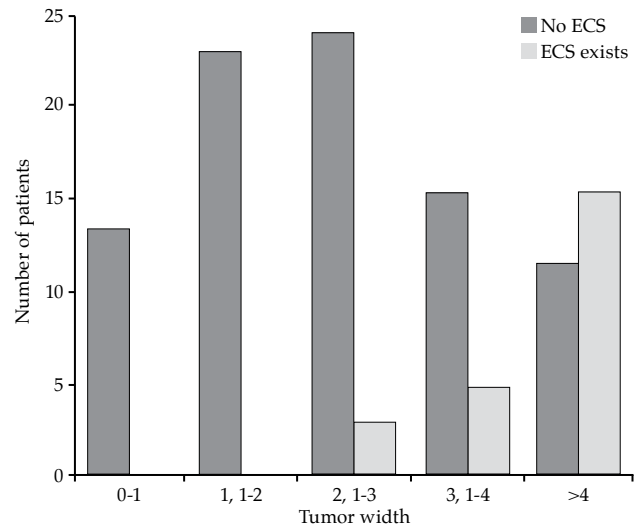


Figure 2. Extracapsular spread-tumor width and extracapsular spread-relation. ECS: Extracapsular spread.

Cervical nodal metastasis

Tumor width, depth and pT (postoperative T) has statistically significant relation to cervical nodal metastasis (Table 4).

Tumor width and depth

Age ($p=0.744$), sex ($p=0.686$), smoking ($p=0.699$), alcohol ($p=0.29$), denture usage ($p=0.659$), histology ($p=0.197$) and grade ($p=0.186$) of tumor has no effect on tumor width (Table 5).

As tumor width increases nodal stage, bilateral nodal metastasis table 2, tumor depth table 6, recurrence table 7 and ECS rate table 3 increases ($p<0.05$).

When we look at the factors between tumor depth and age ($p=0.462$), sex ($p=0.89$), smoke ($p=0.17$), alcohol ($p=0.051$), denture ($p=0.23$), histology ($p=0.95$) also not significant (Table 5). Tumor depth has statistically significant relation with nodal bilaterality ($p=0.003$; table 2) and ECS rate ($p=0.001$; table 3) also with grade (Table 8). Less differentiated tumors seems to be more deep invasion ($p<0.05$).

As tumor depth increases we see that the number of postoperative N0 cases decreases and nodal stage increases (Figure 3).

Receiver operating characteristic curve analysis show us when tumor width exceeds 3.7 cm or tumor depth exceeds 2.4 cm, rate of extracapsular spread reaches highest sensitivity and specificity point (Figure 4).

DISCUSSION

The tongue tumors incidence gradually increase every year. Although it is easy to early diag-

nosis, their prognosis and survival is not getting better. Especially high propensity for neck metastasis decreases their prognosis.^[1] Even early

Table 4. The relation of different parameters to the nodal metastasis

	pN(-)	%	pN(+)	%	p
Sex					$p>0.05$
Female	24	63	14	37	
Male	46	66	23	34	
Age (year)					$p>0.05$
20-40	8	80	2	20	
41-50	17	71	7	29	
51-60	26	67	13	33	
61-80	19	56	15	44	
Postoperative T					$p<0.05$
T1	34	94	2	6	
T2	29	64	16	36	
T3	2	33	4	67	
T4	5	25	15	75	
Differentiation					$p=0.081$
Grade I	21	78	6	22	
Grade II	37	60	25	40	
Grade III	12	67	6	33	
Tumor width					$p<0.05$
<4 cm	62	77	19	33	
>4 cm	8	31	18	69	
Tumor depth					$p<0.05$
<3 cm	65	71	27	29	
>3 cm	5	33	10	67	

T: Tumor; pN: Postoperative N; pN (-): Postoperative N0 patients; pN (+): Postoperative N1 and N2 patients.

Table 5. Tumor width and depth in relation to different parameters

	Age	Sex	Alcohol and smoke	Denture	Histology	Grade	Nodal stage	Bilaterality	ECS	Recurrence
Width	-	-	-	-	-	-	+	+	+	+
Depth	-	-	-	-	-	+	+	+	+	+

ECS: Extracapsular spread; (-) No statistically significant relation ($p>0.05$); (+) Statistically significant relation ($p<0.05$).

T1-T2 tumors may behave very aggressive. Recent researches about tongue tumors focus especially on this subject and many articles in literature figured out the deficiency of TNM staging. Besides nodal metastases and tumor's superficial diameter, tumor depth and ECS proven to decrease survival.^[8] Histopathologically ECS is defined as penetration of tumor through metastatic lymph node's capsule. Lots of articles marked that ECS has relation with survival, recurrence, distant metastasis.^[9] But we still don't know exactly what affects ECS primarily. Is this related to lymph node itself or primary tumor. The question is how to predict existence of ECS. This is the first article in the literature that focused on the relation of tumor width and depth to ECS.

Many factors act on ECS. In the literature there are articles showing relation of age, sex, tumor site and T-stage to ECS;^[9,10] but we didn't find any significant relation of ECS with clinical parameters such as sex, smoke, alcohol, denture; only age has significant relation (Table 3). Above 60 years 35% ECS, however <40 years this rate decreases to 10%. The explanation for this probably due to late presentation and impaired immune system of old people, tumors behave more aggressive and ECS rate increases.^[10]

From histological point of view, type of tumor and grade have no effect on ECS which is similar to previous studies.^[11] Logistic regression analysis figured out that tumor width and depth are

the most important parameters for ECS (Table 3). Tumors with, <3 cm width have <10% ECS rate, above 3 cm this reaches 20% and when exceeds 4 cm 58% ECS seen in metastatic nodes (Table 3). When we look at the tumor depth, <2 cm tumors harbour <17% ECS rate, on the other hand >2cm tumors have >30% ECS rate (Table 3). The mechanism of tumor depth and width to ECS relation is by increasing tumor depth it will be more close to the bigger caliber microvessels that can be a way to metastasize for tumor emboli.^[12,13] The second probable mechanism that explains ECS and tumor depth-width relation is collagenases and matrix metalloproteinases (MMPs) and vascular endothelial growth factors (VEGF).^[14] Tumors harboring more collagenases, MMPs and VEGF proven to be more invasive due to early destruction of extracellular matrix and neovascularization, that may be the same mechanism in which ECS rate increases.

In the literature lots of cut off values seen in relation to tumor depth; according to Borges^[15] when tumor size exceeds 2 cm, nodal disease rate increases; on the other hand, Yuen^[2] reported nodal disease increases while tumor size was above 3 cm; Ambrosch^[6] emphasized that tumor

Table 6. Tumor width-depth relation ($p<0.05$)

	Depth							
	0-1 cm		1.1-2 cm		2.1-3 cm		>3 cm	
	n	%	n	%	n	%	n	%
Width								
0-1 cm	13	100	-	-	-	-	-	-
1.1-2 cm	15	65	6	26	2	9	-	-
2.1-3 cm	6	23	13	50	6	23	1	4
3.1-4 cm	1	5	5	26	9	47	4	21
>4 cm	1	4	6	23	9	35	10	38

Table 7. The relation of tumor width and depth to tumor recurrence ($p<0.05$)

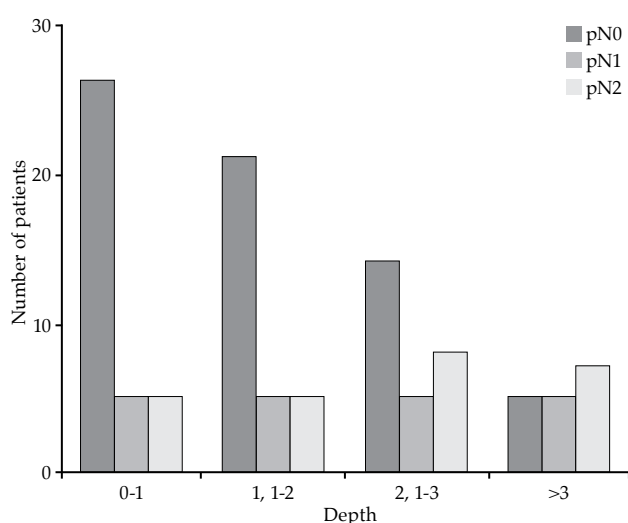
	Recurrence			
	n (-)	%	n (+)	%
Width				
0-1 cm	11	85	2	15
1.1-2 cm	18	78	5	22
2.1-3 cm	13	50	13	50
3.1-4 cm	7	37	12	63
>4 cm	6	23	20	67
Depth				
0-1 cm	28	78	8	22
1.1-2 cm	15	50	15	50
2.1-3 cm	11	42	15	58
>3 cm	1	7	14	93

Table 8. Depth-grade ($p < 0.05$)

	Grade					
	Grade I		Grade II		Grade III	
	n	%	n	%	n	%
Depth						
0-1 cm	14	39	19	53	3	8
1.1-2 cm	9	30	18	60	3	10
2.1-3 cm	3	11	18	69	5	20
>3 cm	1	6	7	47	7	47

depth >4 mm nodal disease increases; Fakhri^[16] suggests elective neck dissection when depth >4 mm.

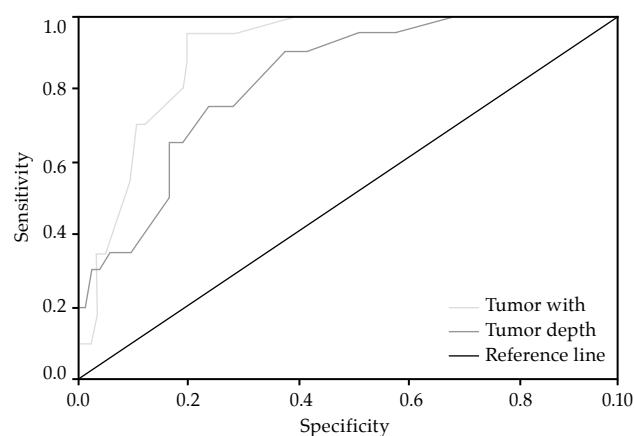
Specificity and sensitivity of ECS maximum at tumor width >3.7 mm and tumor depth >2.4 mm in ROC curve analysis (Figure 4). This doesn't mean more superficial tumors does not metastasize, but this cut-off values warn us about the existence of ECS in the probable metastatic lymph-node, which necessitates more emphasis on the treatment of neck. Keski-Säntti et al.^[8] stated that depth of infiltration more than 5.5 mm have more subclinical nodal disease. But they also thought that this was not an optimal tool for clinical decision making. Kane et al.^[17] and Suzuki et al.^[18] stated that >5 mm tumor depth are at increased risk for nodal metastases and advised elective neck dissection. In a recent journal by Jung compare the magnetic resonance imaging (MRI) and histopathological tumor depth to cervical metastases in oral tongue cancer.^[19] They showed that sensitivity and specificity of nodal metastases is maximum at 8.5 mm

**Figure 3.** The relationship between tumor depth and postoperative N ($p = 0.023$).

in histological examination; 10.5 mm in T1 weighted axial image and 11.5 mm in T2.^[19] Especially pre-operative T1 MRI shows 80% accuracy in determining tumor depth, which can guide us in making decision to clinically negative neck in the light of these data.^[20]

As tumor width and depth increase bilateral nodal metastasis rate, nodal stage, recurrence rate increases (Table 4, 5). In our study we didn't see any bilateral nodal metastases in <3 cm tumor width and <2 cm tumor depth. Above these values $>10\%$ bilaterality seen in nodal metastases. Recurrence also increases with more invasive tumors as expected, but the important point is tumors >3 cm depth has $>90\%$ recurrence rate, so we have to be very careful in follow-up and treatment of these tumors (Table 7). Kurokawa et al.^[21] reported that nodal relapse increases above 4 cm tumor width. Tumor depth has also statistically significant relation with grade (Table 5). Less differentiated tumors seems to be more invasive and as tumor depth increases recurrence rate increases which is consistent with literature. Logistic regression analysis marked that tumor width affects ECS more than tumor depth.

As a result authors figured out that although recent studies especially focused on tumor depth, tumor width is as important as it in many aspects. Extracapsular spread is primarily affected by tumor width and depth. Preoperative estimation of tumor width and depth with MRI is essential in planning neck therapy. In conclusion, if the primary treatment of tongue carcinoma is surgery the neck dissection must be done when tumor depth is bigger than 2.4 cm or tumor width bigger than 3 cm due to

**Figure 4.** Receiver operating characteristic curve analysis of tumor depth and width.

increased ECS risk; on the other hand if the radiotherapy is primary modality we must include the neck also beyond these values of tumor.

REFERENCES

- Shingaki S, Nomura T, Takada M, Kobayashi T, Suzuki I, Nakajima T. The impact of extranodal spread of lymph node metastases in patients with oral cancer. *Int J Oral Maxillofac Surg* 1999;28:279-84.
- Po Wing Yuen A, Lam KY, Lam LK, Ho CM, Wong A, Chow TL, et al. Prognostic factors of clinically stage I and II oral tongue carcinoma-A comparative study of stage, thickness, shape, growth pattern, invasive front malignancy grading, Martinez-Gimeno score, and pathologic features. *Head Neck* 2002;24:513-20.
- Puri SK, Fan CY, Hanna E. Significance of extracapsular lymph node metastases in patients with head and neck squamous cell carcinoma. *Curr Opin Otolaryngol Head Neck Surg* 2003;11:119-23.
- Connor SE, Olliff JF. Imaging of malignant cervical lymphadenopathy. *Dentomaxillofac Radiol* 2000;29:133-43.
- Broders AC. Squamous epithelioma of the lip: a study of live hundred and thirty-seven cases. *J Am Med Assoc* 1920;74:656-64.
- Ambrosch P, Kron M, Fischer G, Brinck U. Micrometastases in carcinoma of the upper aerodigestive tract: detection, risk of metastasizing, and prognostic value of depth of invasion. *Head Neck* 1995;17:473-9.
- Woolgar JA, Scott J. Prediction of cervical lymph node metastasis in squamous cell carcinoma of the tongue/floor of mouth. *Head Neck* 1995;17:463-72.
- Keski-Säntti H, Atula T, Tikka J, Hollmén J, Mäkitie AA, Leivo I. Predictive value of histopathologic parameters in early squamous cell carcinoma of oral tongue. *Oral Oncol* 2007;43:1007-13.
- Johnson JT, Barnes EL, Myers EN, Schramm VL Jr, Borochovit D, Sigler BA. The extracapsular spread of tumors in cervical node metastasis. *Arch Otolaryngol* 1981;107:725-9.
- Woolgar JA, Rogers S, West CR, Errington RD, Brown JS, Vaughan ED. Survival and patterns of recurrence in 200 oral cancer patients treated by radical surgery and neck dissection. *Oral Oncol* 1999;35:257-65.
- Woolgar JA, Rogers SN, Lowe D, Brown JS, Vaughan ED. Cervical lymph node metastasis in oral cancer: the importance of even microscopic extracapsular spread. *Oral Oncol* 2003;39:130-7.
- DiTroia JF. Nodal metastases and prognosis in carcinoma of the oral cavity. *Otolaryngol Clin North Am* 1972;5:333-42.
- Pentenero M, Gandolfo S, Carrozzo M. Importance of tumor thickness and depth of invasion in nodal involvement and prognosis of oral squamous cell carcinoma: a review of the literature. *Head Neck* 2005;27:1080-91.
- Kim SH, Cho NH, Kim K, Lee JS, Koo BS, Kim JH, et al. Correlations of oral tongue cancer invasion with matrix metalloproteinases (MMPs) and vascular endothelial growth factor (VEGF) expression. *J Surg Oncol* 2006;93:330-7.
- Borges AM, Shrikhande SS, Ganesh B. Surgical pathology of squamous carcinoma of the oral cavity: its impact on management. *Semin Surg Oncol* 1989;5:310-7.
- Fakih AR, Rao RS, Borges AM, Patel AR. Elective versus therapeutic neck dissection in early carcinoma of the oral tongue. *Am J Surg* 1989;158:309-13.
- Kane SV, Gupta M, Kakade AC, D' Cruz A. Depth of invasion is the most significant histological predictor of subclinical cervical lymph node metastasis in early squamous carcinomas of the oral cavity. *Eur J Surg Oncol* 2006;32:795-803.
- Suzuki M, Suzuki T, Asai M, Ichimura K, Nibu K, Sugawara M, et al. Clinicopathological factors related to cervical lymph node metastasis in a patient with carcinoma of the oral floor. *Acta Otolaryngol Suppl* 2007;559:129-35.
- Jung J, Cho NH, Kim J, Choi EC, Lee SY, Byeon HK, et al. Significant invasion depth of early oral tongue cancer originated from the lateral border to predict regional metastases and prognosis. *Int J Oral Maxillofac Surg* 2009;38:653-60.
- Lam P, Au-Yeung KM, Cheng PW, Wei WI, Yuen AP, Trendell-Smith N, et al. Correlating MRI and histologic tumor thickness in the assessment of oral tongue cancer. *AJR Am J Roentgenol* 2004;182:803-8.
- Kurokawa H, Yamashita Y, Takeda S, Zhang M, Fukuyama H, Takahashi T. Risk factors for late cervical lymph node metastases in patients with stage I or II carcinoma of the tongue. *Head Neck* 2002;24:731-6.