

PAPER DETAILS


TITLE: A Giant Non-Functioning Granulosa Cell Tumor in a Dog

AUTHORS: Günes ERDOGAN,Rahime YAYGINGÜL,Eyyüp Hakan UCAR,Zeynep Bilgen

SEN,Cevdet PEKER,Mehmet GÜLTEKIN,Emrah IPEK,Serdar PASA

PAGES: 408-410

ORIGINAL PDF URL: <https://dergipark.org.tr/tr/download/article-file/1473965>



Case Report

A Giant Non-Functioning Granulosa Cell Tumor in a Dog

Güneş Erdoğan^{1*}, Rahime Yaygingül², Eyyüp Hakan Ucar¹, Zeynep Bilgen Şen², Cevdet Peker¹,
Mehmet Gültekin³, Emrah İpek⁴, Serdar Paşa³

¹Department of Obstetrics and Gynaecology, ²Department of Surgery, ³Department of Internal Diseases, ⁴Department of Pathology, Adnan Menderes University, Faculty of Veterinary Medicine, Aydın, Turkey,

ABSTRACT

Background/Aim: In this present report, a giant non-functional ovarian granulosa cell tumour (GCT) was described with its clinical, laboratory and histopathological findings in a dog.

Material and Method: A 5-year-old Golden Retriever female dog was referred to our clinic for a progressive abdominal distension, lethargia and dysuria. A large abdominal mass and ascites were visualised in transabdominal ultrasonography.

Results and Conclusion: Exploratory laparotomy revealed an ovarian mass, which was removed by ovariohysterectomy. Histopathology confirmed GCT.

Keywords: Abdominal distension, Granulosa cell tumour, Dog.

Bir Köpekte Dev Boyutlu Non-Fonksiyonel Granulosa Hücre Tümörü

ÖZET

Öz bilgi/Amaç: Sunulan raporda bir köpektaki dev boyutlu non-fonksiyonel ovarian granulosa hücre tümörünün (GCT) klinik, laboratuvar ve histopatolojik bulguları tanımlanmıştır.

Materyal ve Metot: İlerleyen abdominal şişkinlik, letharji ve disuri problemi bulunan 5 yaşlı, Golden-Retriever cinsi dişi köpek kliniğimize sevk edildi. Transabdominal ultrasonografide abdomende büyük bir kitle ve ascites olduğu görüldü.

Bulgular ve Sonuç: Yapılan laparotomide görülen ovarian kitle ovaryohistektomi operasyonu ile uzaklaştırıldı. Histopatolojik araştırmada GCT olduğu bildirildi.

Anahtar kelimeler: Abdominal şişkinlik, Granulosa hücre tümörü, Köpek.

Correspondence to: Güneş Erdoğan, Department of Obstetrics and Gynecology Faculty of Veterinary Medicine, Adnan Menderes University, 09100 Aydın, Turkey. E-mail:gunesems@yahoo.com

Introduction

Ovarian tumours are not very common in female dogs, their frequency ranging between 0.5 and 1.2 % with an average 1% (Pichon et al., 2011). GCT is recorded as the second most frequent type of tumour. GCTs are a type of sex cord stromal tumour and arise from granulosa cell cords derived from atretic follicles (Foster, 2006; Perez-Marin et al., 2014). It has been detected usually as unilateral and encapsulated. (McEntee, 1990; Purswell et al., 1999).

It is well known that these tumours are capable of producing oestrogen and progesterone (Johnston et al., 2001; Davidson and Feldman, 2005). In many GCT cases, clinical signs based on endocrine imbalance are irregular oestrous, vaginal bleeding, vaginal hyperplasia, ovarian cyst, pyometra, vaginal prolapse and dermatological lesions such as symmetric alopecia and hyperpigmentation. (Sforna et al., 2003; Buijtsels et al., 2010; Kim et al., 2011; Tavasoli and Solati, 2011; Nak et al., 2012; Perez-Marin et al., 2014). Meanwhile, dogs with non-functional GCTs usually have no clinical signs related to the reproductive tract (Andersen, 1986; Zanghi et al., 2007; Perez-Marin et al., 2014). In such cases, general symptoms can be more prominent. The principal clinical signs of those tumours are abdominal effusion, abdominal distension (Pichon et al., 2011), and also other relative general symptoms.

The aim of this case report was to present the clinical, morphological, and histopathological characteristics in order to establish the diagnosis of a non-functional GCT in a female dog.

Case History

A 5-year-old Golden Retriever female dog was referred to the Clinics of Adnan Menderes University, Faculty of Veterinary Medicine with symptoms of lethargy, loss of appetite, dysuria and abdominal distension. Parenteral administrations of penicillin, vitamin B complex and also fluid therapy during the last five days have been reported by owners in previous medical history. The last oestrous observed by the owner several months ago was recorded as normal.

At clinical evaluation, a large and firm mass was detected in abdominal palpation. The patient had dysuria and constipation problems that lasted four days. No vaginal discharge was observed in the vaginal inspection and the external genitalia appeared normal. The patient's body temperature was 37.0 °C.

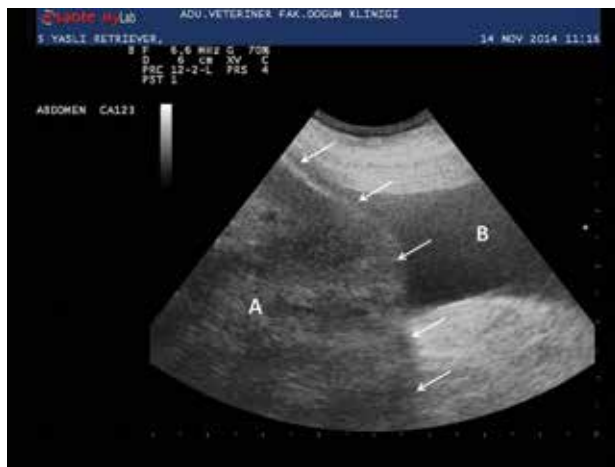

Figure 1. Ultrasonographic image of the mass (A- arrows) and bladder (B).

Şekil 1. Kitlenin ultrasonografik görüntüsü (A- oklar) ve idrar kesesi (B).

A transabdominal ultrasound revealed a large, nonspecific,

isoechoic to hyperechoic mass located from the bladder to the liver (Figure 1). In addition, mild ascites was noted (Figure 2).

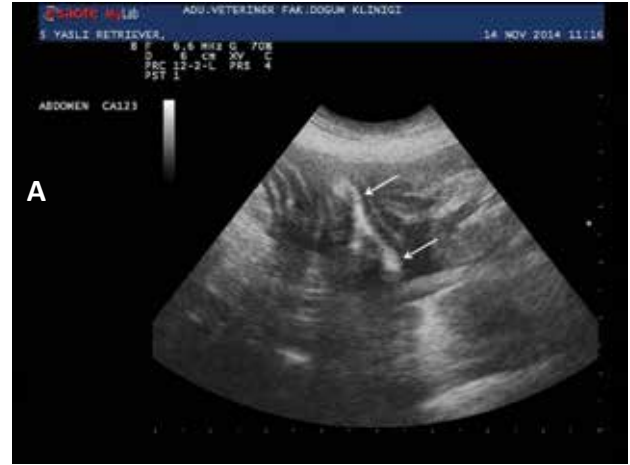

Figure 2. Ultrasonographic image of mild ascites and bowels (arrows).
Şekil 2. Orta düzeydeki ascites ve barsakların ultrasonografik görüntüsü (oklar).

Blood analysis was carried out, and the results are shown in Table 1. Moderate neutrophilia and slight anaemia were detected. Moreover, high serum levels of AST, ALP, total bilirubine, triglyceride and hypoalbuminemia were recorded.

Following the ultrasonographical examination, a median celiotomy was performed, and a large mass connected with the right uterus horn was identified. The mass was firm, encapsulated and adhered to the liver, omentum and bladder. The mass was removed using a routine ovariohysterectomy operation, and routine closure was performed on the abdominal wall. After completing all surgical procedures, the patient died during the awakening period. Therefore the abdominal wall was opened again, but no haemorrhagic focus was observed in the operation area.

The right ovarian tumour was 18.8 x 9 x 14.5 cm in size, weighed 1.280 g and was elastic to the touch, and it had irregular nodules (Figure 3). The tumor consisted of a number of nodules with rubbery consistency with sizes varying from 0.5 cm to 5 cm in diameter. The cut surface of the tumor was mostly solid, encapsulated, yellowish and quite friable with areas of hemorrhage. Follicle formations in different sizes separated by sharp boundaries were observed. Microscopically, the tumor was observed to consist of a number of different sized macrofollicles separated by thick, hyalinized acellular fibrous stroma with centrally located necrotic and hemorrhagic areas. In some areas, the invasion of tumoural cells to the fibrous stroma was noticed. Follicles were comprised of mostly anaplastic tumoural cells with hyperchromatic, spindle-shaped nuclei. In a few follicles, the oval/round shape cavity containing centrally located eosinophilic fluid was surrounded by one or more rows of cells with mostly anaplastic spindle or oval-shaped nuclei formed as a Call-exter body. In some areas, anaplastic tumoural cells were luteinized. Ten or more mitotic figures were present per high power field.

Results and Discussion

GCTs were recorded in middle aged and older dogs (Pluhar et al., 1995; Sforna et al., 2003) and detected commonly on the left ovary (Purswell et al., 1999). In the present case, although the patient's age was in the range referred to in the literature, the tumour was localized in the right ovary. It is known that 20% of GCT cases exhibit metastasis (Perez-Marin et al., 2014). Although no obvious metastatic lesions were observed in

abdominal organs, tight adhesions to the liver, omentum and bladder were noted.

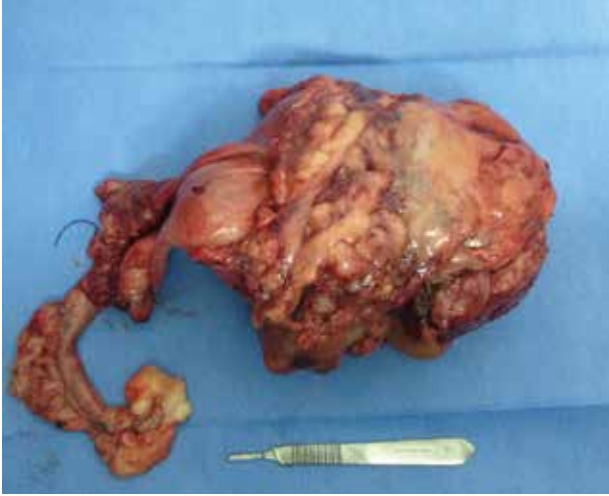

Figure 3. Macroscopic appearance of genital organs and ovarian mass.

Şekil 3. Genital organların ve ovaryan kitlenin makroskopik görüntüsü.

Canine ovarian tumours remaining asymptomatic for a long period of time have a high risk of clinical diagnosis. In some non-functional GCT cases, the lack of reproductive signs or some mistaken diagnosis result delay access to appropriate treatment. There are similar cases which reported delayed diagnoses of large-sized and non-functioning GCT (Andersen, 1986; Perez-Marin et al., 2014) and also the incidental cases (Tunca et al., 2012). Meanwhile, small-sized GCTs causing hyperestrogenic signs can be detected earlier (Sivacolundhu et al., 2001; Zanghi et al., 2006; Kim et al., 2012). When regarding the size of this tumour, it has been considered that the diagnosis of this case was delayed for almost a year. Therefore, more detailed examinations should be performed on older female dogs with general and/or abdominal symptoms.

In cases accompanied by abdominal effusion, cytological examinations (Sforna et al., 2003) and transabdominal ultrasonography are useful for diagnosis of these tumours. But cytological examinations can be more practical for short-haired breed dogs showing the abdominal distension earlier and more apparently. It is well known that transabdominal ultrasonography can reveal numerous ovarian masses and many ovarian disorders (Tunca et al., 2011; Kim et al., 2012; Pandey et al., 2012; Perez-Marin et al., 2014). Although a honeycomb structure from the ultrasonography image is strongly suggestive of a GCT (McEntee, 2002), any similar image that has diagnostic value was not observed in this present case.

References

- Andersen GL (1986). Granulosa cell tumor in a dog. *Compendium Continuing Education Veterinary*, 8, 159-168.
- Buijtel JJCWM, de Gier J, Kooistra HS, Kroeze EJBV, Okkens AC (2010). Alterations of the pituitary-ovarian axis in dogs with a functional granulosa cell tumor. *Theriogenology*, 73, 11-19.
- Davidson AP, Feldman EC (2005). Ovarian and estrous cycle abnormalities. In: *Textbook of Veterinary Internal Medicine*, Ettinger SJ, Feldman EC (Eds), Elsevier Saunders, Philadelphia, pp. 1649-1655.
- Foster RA (2006). Female Reproductive System. In: *Pathologic Basis of Veterinary Diseases*, McGavin MD, Zachary JF (Eds.), Mosby, China, pp. 1280-1282.

Johnston SD, Root Kustritz MV, Olson PNS (2001). Disorders of the canine ovary. Ovarian tumors. In: *Canine and Feline Theriogenology*, Johnston SD, Kustritz MVR, Olson PNS (Eds.), WB Saunders, Philadelphia, pp. 193-205.

Kim H, Choi H, Kim H, Choi J (2012). A giant paraovarian cyst in a dog with a granulosa cell tumor. *Journal of Veterinary Medicine Science*, 74, 385-389.

McEntee K (1990). Ovarian neoplasms. In: *Reproductive Pathology of Domestic Mammals*, McEntee K (Ed.) Academic Press, NewYork, pp. 69-93.

McEntee MC (2002). Reproductive oncology: Clinical techniques. *Journal of Small Animal Practice*, 17, 133-149.

Nak D, Demirel AA, Tuna B, Nak Y, Ozyigit O (2012). Vaginal prolapse related to ovarin granulosa cell tumor in an Anatolian Shepherd. *Turkish Journal of Veterinary Animal Science*, 36, 61-66.

Pandey AK, Bharti B, Nayak AK (2012). Granulosa cell tumour, its diagnosis and successful management in a bitch. *Haryana Veterinarian*, 51, 119-120.

Perez-Marin CC, Molilna L, Vizuete G, Sanchez JM, Zafra R, Bautista MJ (2014). Uterine and ovarian remnants in an incorrectly spayed bitch: a case report. *Veterinari Medicina*, 59, 102-106

Pichon M, Tainturier D, Amirat-Briand L, Garand A, Benchariff D (2011). Granulosa-cell tumour in a three year and a half old neutered bitch. *Revue Medicine Veterinaire*, 162, 406-412.

Pluhar GE, Memon MA, Wheaton LG (1995). Granulosa cell tumour in an ovariectomized dog. *Journal of American Veterinary Medicine Association*, 207, 1063-1065.

Purcell BJ, Parker NA, Bailey TL, Dascario JJ, Sponenberg DP (1999). Theriogenology question of the month. Persistent estrus caused by functional granulosa cell tumor of the left ovary. *Journal of American Veterinary Medicine Association*, 215, 193-195.

Sforna M, Brachelente C, Leprie E, Mechelli L (2003). Canine ovarian tumours: A Retrospective study of 49 cases. *Veterinary Research Communication*, 27, 359-361.

Sivacolundhu, RK, O'Hara AJ, Read RA (2001). Granulosa cell tumour in two spayed bitches. *Australian Veterinary Journal*, 79, 173-176.

Tavasoli A, Solati A (2011). Granulosa cell tumor of the ovary in dog: Case report from Tehran. *Journal of Animal Biology*, 5, 66-68.

Tunca R, Serin G, Epikmen ET, Aydogan A, Avcı H (2011). İki köpekte granuloza hücre tümörü. *Journal of Faculty of Veterinary Medicine Kafkas University*, 17, 675-678.

Zanghi A, Catone G, Marino G, Quartuccio M, Nicotina PA (2007). Endometrial polypoid adenomyomatosis in a bitch with ovarian granulosa cell tumour and pyometra. *Journal of Comparative Pathology*, 136, 83-86.