

PAPER DETAILS

TITLE: RELATIONSHIP BETWEEN TRAUBE'S SPACE AND BODY MASS INDEX

AUTHORS: Dündar KAÇAR,Çagatay BARUT,Özdemir SEVINÇ

PAGES: 0-0

ORIGINAL PDF URL: <https://dergipark.org.tr/tr/download/article-file/267782>

Relationship between Traube's space and body mass index

Dündar Kaçar¹, Çağatay Barut², Özdemir Sevinç³

¹Antalya Training and Research Hospital, Antalya, Turkey

²Department of Anatomy, Faculty of Medicine, Bahçeşehir University, Istanbul, Turkey

³Department of Anatomy, Faculty of Medicine, Recep Tayyip Erdoğan University, Rize, Turkey

Abstract

Objectives: Traube's space is located in the precordial area of the anterior chest wall and is used in the evaluation of spleen size; therefore, proper evaluation during physical examination is extremely important. The aim of this study was to evaluate the association between Traube's space, detected by Castell's method, and body mass index (BMI).

Methods: Twenty-one male and 14 female subjects were evaluated by the same physician with percussion method, in 2007 and 2010. Traube's space was determined on the thoracic wall and its shape was drawn on transparent paper. The drawings were scanned and the images were transferred to a personal computer (PC). The area of Traube's space on each image was calculated using Digimizer software. BMI was calculated by the body weight/(height)² formula. The data were evaluated with SPSS 13.0 software. To compare the data obtained in 2007 and 2010, the Wilcoxon signed-rank test was used.

Results: The BMI of males increased by 9.24% in three years, and the surface area of Traube's space in males decreased by 36.02% in this period. The differences in BMI and Traube's space were statistically significant ($p < 0.05$). The BMI of females increased by 2.39% in three years, but the difference was not statistically significant ($p > 0.05$). The surface area of Traube's space of females decreased by 28.23% in this period, the difference was statistically significant ($p < 0.05$).

Conclusion: The data obtained in this study are suggested to be useful for evaluation of Traube's space and spleen size during physical examination in terms of gender and BMI.

Keywords: body mass index; female; male; Traube's space

Anatomy 2016;10(2):134–137 ©2016 Turkish Society of Anatomy and Clinical Anatomy (TSACA)

Introduction

Traube's space is located in the left half of the front chest wall and is limited by the sixth rib, left anterior axillary line, and left costal arch.^[1] Within this space lies the fundus of the stomach.^[2] During physical examination by percussion, a tympanic sound is produced due to the air-filled structure (Traube open).^[3,4] However, in some pathological conditions, the space between the fundus of the stomach and the diaphragm shrinks and the sound heard changes to a dull tone (Traube closed).^[3,5]

Traube (1818–1876), who performed studies in this field, pointed out that the tympanic sound of this space may not be produced in various diseases.^[1,6] In the following years, various related physical examination methods were developed, such as Nixon's method and Castell's method. Nixon studied this space by making patients lie

on their right side, whereas Castell studied this space by making the patients lie on their back (supine position).^[7,8] The aim of this study was to evaluate the relationship between Traube's space as evaluated by Castell's method and the body mass index (BMI).

Materials and Methods

This cross-sectional study was carried out with the participation of 35 individuals (21 males, 14 females) aged 22 to 30 years. The Ethics Committee of Bülent Ecevit University, Zonguldak, Turkey also approved the study (2008/08 - 05.06.2008). Individuals taking part in the study were first given written and verbal information regarding the study. The examination of Traube's space was carried out twice by the same physician, using the same method, in 2007 and 2010. The examination was performed while

the participant was lying in the supine position and inhaling normally.^[9] Before percussion, the area over the thoracic wall compatible with Traube's space was evaluated manually with the fascial listening test of the thorax. The fascial listening test involves palpation to evaluate the mobility of the skin, with the aim of exposing underlying changes and possible movements. This test is used in the daily practice of osteopathic medicine.^[10] In the present study, individuals with no pathology detected by the fascial listening method were evaluated with percussion. The percussion started above the left breast and extended down the midclavicular line, the point at which the tympanic sound was heard was marked. Following the same line, the percussion extended down from the marked point, and the point at which the tympanic sound disappeared was detected. With the same method, percussion was performed transversely and separately from the sixth and seventh intercostal spaces to the anterior axillary line and, from there, percussion was performed at a point 2 cm laterally. The first point at which the tympanic sound was heard, and then disappeared, was marked. The distances between these six marked points were checked by percussion; the angle of the combined line (straight, convex, or concave) was found and highlighted with a permanent marker (**Figure 1**). The drawing of this space was then copied onto a transparency, and the examination was ended.^[9] In this study, Castell's method was preferred, because it is a highly sensitive method for detecting the

Table 1

Sensitivity and specificity of the methods used to evaluate and determine splenomegaly.

Method	Sensitivity (%)	Specificity (%)
Nixon (1954) ^[7]	59	94
Castell (1967) ^[8]	82	83
Barkun et al. (1989) ^[6]	62	72

size of the spleen (**Table 1**).^[1] The obtained areas were measured using Digimzer software (version 4.6.1; Informer Technologies Inc, Los Angeles, CA, USA). In addition, the body weight and height of the participants were recorded. During their anamnesis, they had been asked questions regarding any prior stomach operations, morning defecation, and any other relevant health information, and all data were noted in both 2007 and 2010. Furthermore, the BMI was calculated by the body weight/height² formula. Data obtained from every participant were recorded on assessment forms and later transferred to the program SPSS Statistical Package for Social Sciences (SPSS) software (version 11.0; SPSS Inc, Chicago, IL, USA). To compare the data obtained in 2007 and 2010, the Wilcoxon signed-rank test was used. Each gender was evaluated separately. A p value of <0.05 was accepted as statistically significant.

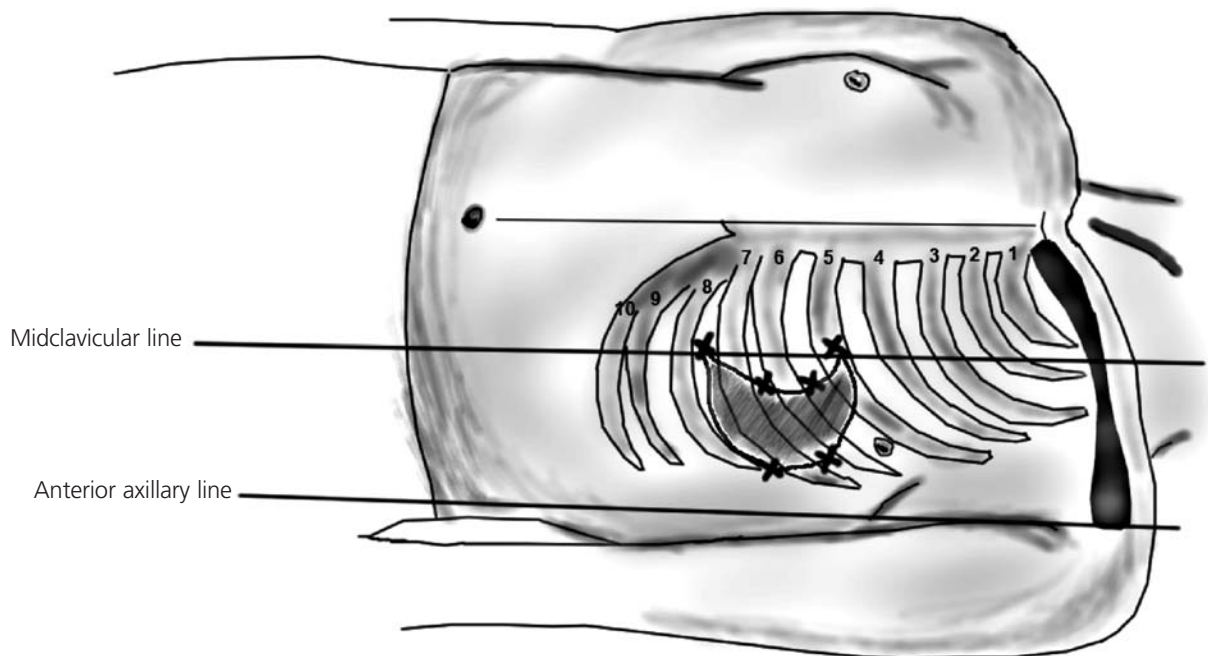


Figure 1. Marked points and combining lines illustrating the Traube's space.

Results

The body weight of the males increased by 9.43% in three years, and their BMI increased by 9.24%. The mean BMI of the males was 23.06 kg/m² in 2007 and 25.19 kg/m² in 2010. Surface area of Traube's space of males decreased by 36.02% in the same period. The mean surface area of Traube's space of males was 4894.5 mm² in 2007 and 3131.55 mm² in 2010. The differences in body weight, BMI, and Traube's space of males were statistically significant ($p<0.05$) (**Table 2**). The body weight of the females increased by 2.26% in three years, and their BMI increased by 2.39%. The mean BMI of the females was 22.15 kg/m² in 2007 and 22.68 kg/m² in 2010. The differences in the body weight and BMI of females were not statistically significant ($p>0.05$) (**Table 3**). Surface area of Traube's space in females decreased by 28.23% in the same period. The mean surface area of Traube's space of females was 2289.06 mm² in 2007 and 1642.82 mm² in 2010. The difference regarding Traube's space of females during time was statistically significant ($p<0.05$) (**Table 3**).

Discussion

Until now, studies on Traube's space have mostly focused on the spleen, particularly the size of the spleen.^[8,11,12] In this study, however, we focused on the location of Traube's space on the anterior chest wall and the relationship between the surface area of Traube's space and BMI. We tried to elucidate the possible impact of BMI alterations on Traube's space.

Our results showed that the surface area of Traube's space of males and females decreased with time and that the differences were statistically significant (**Tables 2 and 3**). Barkun et al. found that false-negative results also increased when the BMI increased, meaning that with increases in the BMI, Traube's space was evaluated as "closed", although it was "open".^[6] Their findings suggest that alterations in the BMI may affect the area of Traube's space. Our results indicate that with the increase in BMI, the area of Traube's space decreased; thus, it is possible to say that our results are somewhat in accordance with the results of Barkun et al.^[6] The reduction in Traube's space on the anterior chest wall decreases the possibility of detection of tympanic sounds over this area (Traube open). If percussion is not carefully performed in detail, "open" Traube can be incorrectly detected as "closed". We believe that the increase in the fatty tissue within the superficial fascia may be among the reasons for the difficulty in the localization of Traube's space with the increase in body weight, because the absorption of shock is among the basic functions of the superficial fascia.^[10] It is possible to describe the tapping applied during percus-

Table 2
Comparison of area of Traube's space and BMI over time in males with Wilcoxon signed-rank test (mean±SD; n=21).

Parameter	2007	2010
Body weight (kg)	74.24±10.53	81.24±12.02*
BMI (kg/m ²)	23.06±2.44	25.19±2.46*
Area of Traube's space (mm ²)	4894.5±1798.4	3131.55±1085.67*

* $p<0.05$

sion as a component of shock and this may help to explain the decrease in the surface area of Traube's space, in contrast to the increase in BMI.

Moreover, a fascia listening test was applied prior to percussion. The aim of the fascia listening test was to eliminate the possibility of any underlying factor that may affect the detection of a tympanic sound during percussion. During the fascia listening test, the detection of any pathology would have been accepted as an abnormality in the soft tissue, which may indicate a decrease in fascia force lines and elasticity of soft tissue. Poor posture, stress, and biochemical alterations in the connective tissue are among the reasons for such abnormalities in the soft tissue.^[10] If any individual had such findings, he would have been excluded from the study. However, none of the individuals evaluated for inclusion in this study had any such findings; thus, all of them were included.

Conclusion

The decrease in the area of Traube's space with time, in both genders, is an interesting finding, but we could not find any literature with which to discuss this point. Although the two evaluations were performed by the same physician, there might have been evaluation bias, which is something to take into account. Furthermore, the BMI may have affected the evaluation of Traube's space. Increase in BMI indicates the increase in body weight. In adults increase in body weight commonly indicates the increase in the fatty tissue. The increase in the fatty tissue

Table 3
Comparison of area of Traube's space and BMI over time in females with Wilcoxon signed-rank test (mean±SD; n=14).

Parameter	2007	2010
Body weight (kg)	59.86±8.75	61.21±8.55
BMI (kg/m ²)	22.15±2.75	22.68±2.84
Area of Traube's space (mm ²)	2289.06±1135.69	1642.82±890.53*

* $p<0.05$

may have led the decrease of the area of the Traube's space as explained in the discussion section above. To overcome this point, radiologic evaluations must accompany the physical examination. The obtained data are suggested to be useful for evaluation of Traube's space during physical examination.

Acknowledgement

We would like to express our sincere graditute to Dr. Derya Karaoğlu for her exquisite drawing.

References

1. Yang JC, Rickman LS, Bosser SK. The clinical diagnosis of splenomegaly. West J Med 1991;155:47-52.
2. Yıldırım M. Topografik anatomi. İstanbul: Nobel Tıp Kitabevi; 2000. p. 283.
3. Ökten A. Karnın fizik muayenesi. In: Kaysı A, ed. İç hastalıkları semiyolojisi. 4. baskı. İstanbul: Alfa Yayıncılık; 2007. p. 426.
4. Korkut B, Altınbaş A, Sarıgözel A, Özerin U, Gök H. Discrete type subaortic stenosis in dextrocardia with situs inversus totalis. Int J Angiol 1998;7:258-60.
5. Arıncı K, Elhan A. Anatomi. 2. cilt. 4. baskı. Ankara: Güneş Kitabevi; 2006. p. 105.
6. Barkun AN, Camus M, Meagher T, Green L, Coupal L, De Stempel J, Grover SA. Splenic enlargement and Traube's space: how useful is percussion? Am J Med 1989;87:562-6.
7. Nixon RK Jr. The detection of splenomegaly by percussion. N Engl J Med 1954;250:166-7.
8. Castell DO. The spleen percussion sign. A useful diagnostic technique. Ann Intern Med 1967;67:1265-7.
9. Kaçar D, Barut C. Evaluation of Traube's space using a novel computer-assisted method. Anatomy 2016;10:46-9.
10. Paoletti S. The fasciae: anatomy, dysfunction and treatment. Seattle, WA: Eastland Press; 2006. p. 204-24.
11. Zhang B, Lewis SM. A study of the reliability of clinical palpation of the spleen. Clin Lab Haematol 1989;11:7-10.
12. Grover SA, Barkun AN, Sackett DL. The rational clinical examination. Does this patient have splenomegaly? JAMA 2011;305:1414.

Online available at:
www.anatomy.org.tr
doi:10.2399/ana.16.018
QR code:

deomed®



Correspondence to: Çağatay Barut, MD, PhD
Department of Anatomy, Faculty of Medicine,
Bahçeşehir University, İstanbul, Turkey
Phone: +90 532 463 84 71
e-mail: cagbarut@yahoo.com

Conflict of interest statement: No conflicts declared.

This is an open access article distributed under the terms of the Creative Commons Attribution-NonCommercial-NoDerivs 3.0 Unported (CC BY-NC-ND3.0) Licence (<http://creativecommons.org/licenses/by-nc-nd/3.0/>) which permits unrestricted noncommercial use, distribution, and reproduction in any medium, provided the original work is properly cited. *Please cite this article as:* Kaçar D, Barut Ç, Sevinç Ö. Relationship between Traube's space and body mass index. Anatomy 2016;10(2):134-137.