

## PAPER DETAILS

TITLE: Revisiting the obturator nerve anatomy with a nerve blocking perspective

AUTHORS: Turan Koç,Orhan Berger,Sebnem Rumeli,Alev Bobus Örs,Nail Can Öztürk

PAGES: 22-33

ORIGINAL PDF URL: <https://dergipark.org.tr/tr/download/article-file/3668695>

# Revisiting the obturator nerve anatomy with a nerve blocking perspective

Turan Koç<sup>1</sup> , Orhan Beger<sup>2</sup> , Şebnem Rumeli<sup>3</sup> , Alev Bobuş Örs<sup>4</sup> , Nail Can Öztürk<sup>4</sup> 

<sup>1</sup>Department of Anatomy, Kabramanmaraş Sütçü İmam University Faculty of Medicine, Kabramanmaraş, Türkiye

<sup>2</sup>Department of Anatomy, Gaziantep University Faculty of Medicine, Gaziantep, Türkiye

<sup>3</sup>Department of Anesthesiology, Mersin University Hospital, Mersin, Türkiye

<sup>4</sup>Department of Anatomy, Mersin University Faculty of Medicine, Mersin, Türkiye

## Abstract

**Objectives:** Accurate nerve block is important for the success of local anesthesia-assisted surgery. Failure to consider the anatomical variations of the targeted nerve anatomy can lead to failure of anesthetic interventions. Given the distinct nature of the obturator nerve, blocking the nerve during clinical procedures is one such problematic situation. The aim of this article is to revisit the anatomy of the obturator nerve in adult cadavers and fetuses in order to discuss in detail its relationship with the obturator nerve block from an anatomical perspective.

**Methods:** Obturator nerve and its branches were exposed at the posterior wall of the abdomen, lateral wall of the lesser pelvis and anterior aspect of the thigh region in 47 fetuses and 10 adult cadavers. Then, various anatomical variations and morphometry of the obturator nerve were evaluated and measured in detail.

**Results:** In adult cadavers, the anterior and posterior branches branched 40% in the obturator canal and 60% in the extra-pelvic region, with no branching in the pelvis. In fetuses, the obturator nerve divided into its main branches 8.5% in the pelvis, 33% in the canal and 58.5% distal to the canal. Regarding the muscular branching of the obturator nerve, all adult cadavers showed three fully traceable branches from the anterior and a single branch from the posterior branch.

**Conclusion:** Our findings regarding the variable branching pattern of the obturator nerve anatomy from the nerve block perspective may help anesthesiologists to improve the success of obturator nerve block by incorporating results from the current and limited number of anatomical data sets.

**Keywords:** fetal anatomy; obturator nerve; regional anesthetic techniques

Anatomy 2023;17(1):22–33 ©2023 Turkish Society of Anatomy and Clinical Anatomy (TSACA)

## Introduction

The obturator nerve (ON) generally originates from the ventral rami of L2–L4 spinal nerves and emerges on the medial side of the psoas major muscle, then descends at the medial side of this muscle. After running at the lateral wall of the lesser pelvis, it passes through the obturator canal (OC) and reaches to the medial side of the thigh region.<sup>[1]</sup> Upon passing through the OC, it bifurcates into an anterior branch (AB) and a posterior branch (PB) to innervate adductor muscles, hip and knee joints.<sup>[1–3]</sup>

There are many studies in the literature suggesting that branching of the ON can exhibit variability<sup>[2–4]</sup> and have distinct variations from the originally described

anatomy.<sup>[1]</sup> Primarily, there are three known AB/PB bifurcation pattern in terms of its location: 1) in the pelvic region proximal to the OC; 2) inside the OC; 3) after leaving the OC (extra-pelvic).<sup>[2–5]</sup> This branching variability can become crucial for a successful ONB during many clinical applications such as hip and knee amputations, preventing the obturator reflex during transurethral bladder tumor resections,<sup>[6–9]</sup> relieving the thigh adductor spasms in patients suffering from multiple sclerosis, paraplegia or cerebral palsy and treatment of chronic hip pain.<sup>[10,11]</sup> It is also important to know the variations of the femoral and lateral cutaneous femoral nerves in order to provide a complete anesthesia in this region. femoral and lateral cutaneous femoral nerves.<sup>[10–12]</sup>

Since successful blockade of this nerve is crucial for the mentioned clinical procedures, efforts to develop selective ONB have been ongoing for almost a century. From a historical perspective, the first selective ONB trial dates back to the 1920s.<sup>[13]</sup> Either recognized as Labat's or Pubic approach, this classical procedure was designed to target ONB based on anatomical landmarks and applied 1.5 cm lateral and caudal to the pubic tubercle.<sup>[7,13,14]</sup> Long after, in 1973, namely as 3-in-1, a newer concept, targeting the simultaneous blockage of multiple nerves (ON, FN and lateral cutaneous nerve) was described by Winnie et al.<sup>[15]</sup> However, it is not surprising that strong arguments against this approach have accumulated, because with this technique, inadequate or weak nerve blocking was seen as well as unexpected results.<sup>[16]</sup> Almost two decades after 3-in-1 technique appeared, technological progresses brought nerve stimulated assisted inter-adductor approach into the arena as described by Wassef.<sup>[17]</sup> Then, relatively recently, in 2005, Choquet et al.<sup>[18]</sup> described a nerve stimulation-assisted blockade procedure, termed the "inguinal approach", also based on standard anatomical landmarks, applied through the midpoint of the inguinal fold between the femoral artery and the adductor longus muscle tendon. Compared to its older alternative the "pubic approach", the "inguinal approach" provides a significantly more effective blockade, given better patient comfort and higher blockade efficacy.<sup>[18,19]</sup> Rapid advances in medical technology have created even newer approaches for anesthesiologists. A few years after the Choquet approach, ultrasound-guided fascia iliaca block with selective ONB, a new generation method using ultrasound technology, was introduced.<sup>[20]</sup> Although efforts towards better ONB performance are still evident, in this study we wanted to focus on the relation of ON anatomy to ONB procedures. Therefore, the aim of this study is to revisit the anatomy of the obturator nerve in adult cadavers and fetuses in order to discuss in detail its relationship with the ONB from an anatomical perspective.

## Materials and Methods

This study was conducted on 94 sides of 47 fetuses (mean gestational week:  $22.85 \pm 3.35$ ) and 20 sides of 10 formalin-fixed male cadavers (mean age  $80 \pm 18.022$ ) without any external pathology or anomaly. The cadavers were available in the inventory of Anatomy Department of Mersin University, Faculty of Medicine. The fetus and adult cadavers were preserved with 10% formalin solution. All the dissections were performed in the supine position

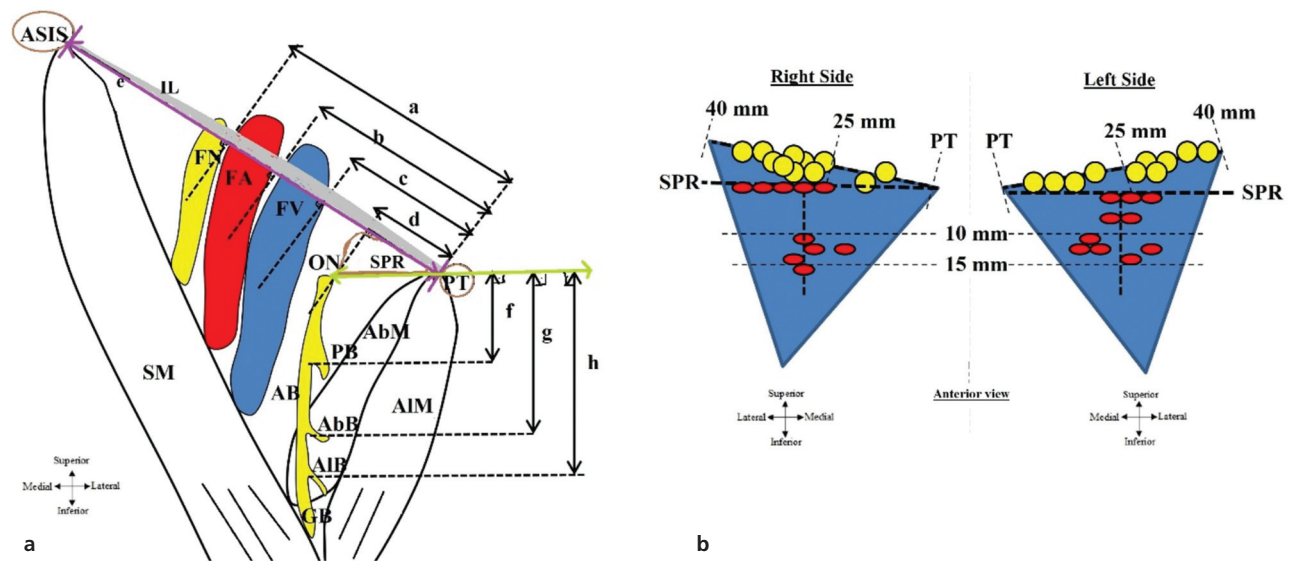
under a surgical microscope (Carl Zeiss f170 surgical microscope, Oberkochen, Germany) and photographed with a digital camera. Additionally, morphometric distances were measured by using a digital caliper with  $\pm 0.01$  mm precision. All measurements were repeated three times independently by two researchers (TK and OB). Mean-standard deviation was used for descriptive statistics of all parameters used.

The posterior abdominal wall and pelvic regions were dissected in order to identify the roots of the ON, the 3–4th lumbar vertebrae and psoas major muscle (PM). The ON coursing with the obturator artery and vein on the lateral pelvic wall was followed proximally and blunt dissection was performed in this region. The initial parts of the PM were carefully dissected to identify the roots of this nerve, which runs medial to the PM.

In order to visualize the passage of the ON from the pelvis to the thigh, the entrance and exit of the OC was exposed by shaving the superior pubic ramus (SPR). Dissection was then continued on the anterior aspect of the thigh.

Anterior superior iliac spine (ASIS), inguinale ligament (IL), pubic tubercle (PT), femoral vein (FV), femoral artery (FA), femoral nerve (FN), SPR, branches of ON and adductor muscles are chosen as anatomical landmarks. The inguinal ligament was exposed by blunt dissection from proximal to distal through the anterior abdominal wall in the supine position. The great saphenous vein running under the skin was identified and hiatus saphenous was exposed. The femoral sheath surrounding the FV and FA was carefully dissected and the vascular lacuna was identified. The muscular lacuna on the lateral side was also carefully opened and the iliopsoas muscle and the FN were exposed. In order not to disrupt the position of the structures, only the fascial sheaths adherent to the anterior side of the structures were opened. Then, after removal of the skin and subcutaneous tissues of the anterior and inner thigh, the sartorius, pectineus and adductor longus muscles were dissected free from the anterior fascia and a transverse incision line was created to expose the adductor brevis and external obturator muscles at a deeper level. The ON and its AB was identified in the connective tissue surrounding the adductor brevis muscle. After cutting and removing the adductor brevis muscle anterolaterally, the course of the PB of the ON was revealed. Both branches of the ON were followed cranially and caudally.

Thereafter, to provide a descriptive and convenient map of the anatomical relations given above, a sum of



**Figure 1.** Schematic drawing of the anterior view of the femoral triangle showing (a) the measurements of the parameters related with obturator nerve and (b) description of its location and branching points. a–h: measurements of distances. AB: anterior branch of the obturator nerve; AbB: adductor brevis branch; AbM: adductor brevis muscle; AIB: adductor longus branch; AIM: adductor longus muscle; ASIS: anterior superior iliac spine; FA: femoral artery; FN: femoral nerve; FV: femoral vein; GB: gracilis branch; IL: inguinal ligament; ON: obturator nerve; PB: posterior branch of the obturator nerve; PT: pubic tubercle; SPR: superior pubic ramus; SM: sartorius muscle. Green line: The line passing through the lower edge of the SPR. Purple line: line extending between the lateral edge of PT and the medial edge of ASIS, passing through the lower edge of the IL. Red circle exhibits the branching point of the AB and PB on the vertical line. Yellow circle exhibits location of the obturator nerve on the oblique line.

eight distance parameters between the neuro-vascular structures and certain landmarks (Figure 1). The locations of the ON, FV, FA and FN along the lower edge of the IL were recorded. For this purpose, measurements were made by considering the vertical and oblique lines. Oblique line was extending between the lateral edge of PT and the medial edge of the ASIS. Vertical line was passing through the medial edges of the neurovascular structures. The projections of the structures on the oblique line were recorded, considering the 90-degree angle between both lines as (Figure 1):

- (a) Distance between the PT–FN; (b) Distance between the PT–FA; (c) Distance between the PT–FV; (d) Distance between the PT–ON.

In order to define the exit points of the branches of the ON, the vertical line passing through the intersection of the lower edge of the SPR and the medial edge of the ON was taken as landmark. The distance of each branch separated along this line was recorded as:

- (e) Distance between the ASIS–PT; (f) Distance between the SPR and AB/PB diverging point; (g) Distance between the SPR and AB/branch to adductor brevis muscle (AbB) diverging point; (h) Distance between the SPR and AB/branch to gracilis muscle (GB) diverging point.

Following parameters were measured via digital caliper in adult cadavers. Respective data was presented based on descriptive statistics. Lastly, foot lengths of fetuses were measured to estimate the gestational ages (in weeks/months) of the fetuses (Table 1).

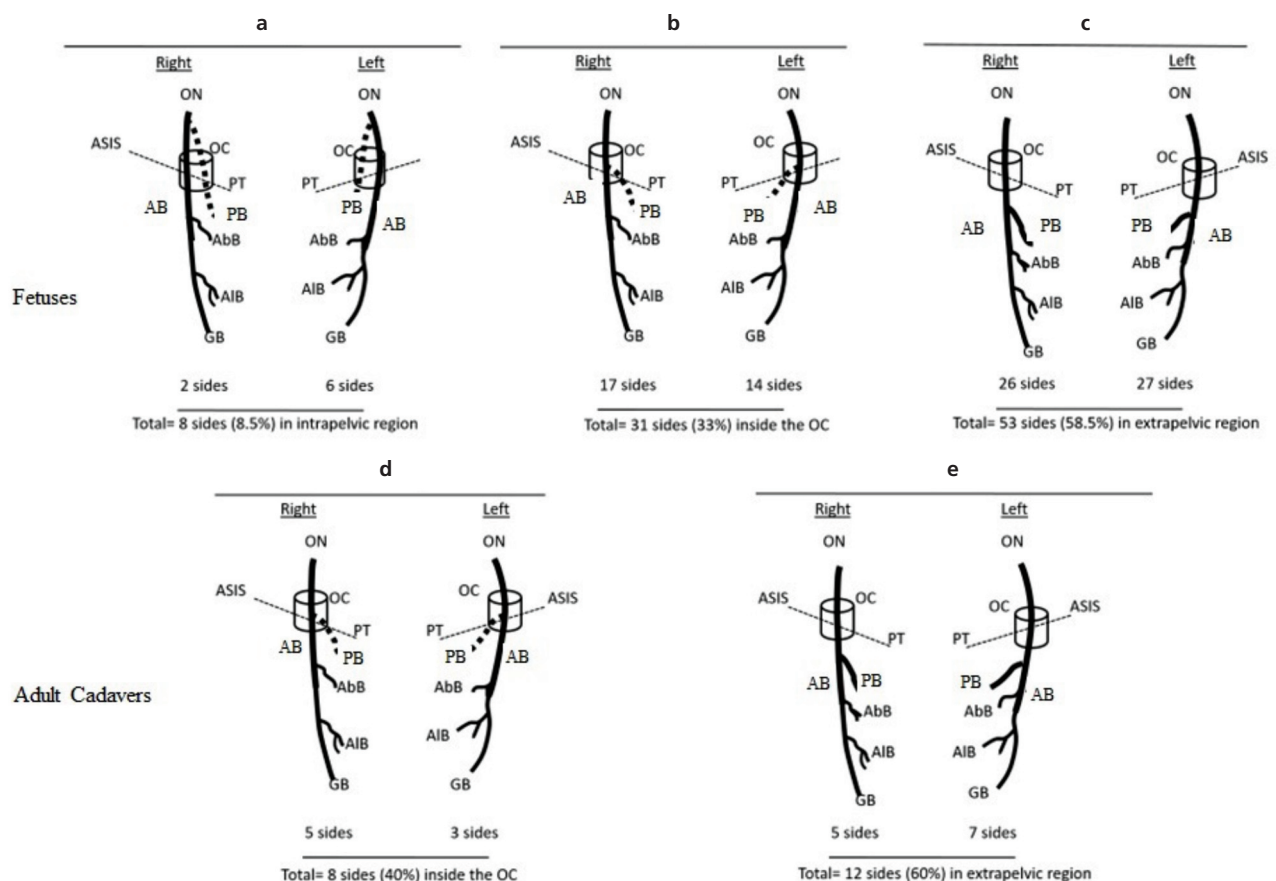
## Results

In all cases in the study, both in fetuses and adult cadavers, ON originated from the L2–L4 spinal nerves and emerged on the medial side of the psoas major muscle. In fetuses, 8.5% (8/94) of the AB and PB branched from ON in the pelvic region (Figures 2a and 3a), 33% (33/94 cases) in the OC (Figures 2b and 3b) and 58.5% (53/94 cases) in the extra-pelvic region (Figures 2c and 3c).

On the other hand, in adult cadavers, the OB branched into the AB and PB in its own canal in 40% (8/20) of the specimens (Figures 2d and 4a), whereas in the remainder (60%, 12/20) it branched after leaving the canal (Figures 2e and 4b). When the ON branching was examined on the lateral wall of the pelvic region, a branch to the hip joint was found proximal to the OC entrance in 35% (7/20) of adult cadavers (Figures 5a, c and d), whereas in the remaining cases this branch diverged from the AB (65–13/20%) (Figures 5b and e). On the other hand, distance of ON to PT was  $26.61 \pm$

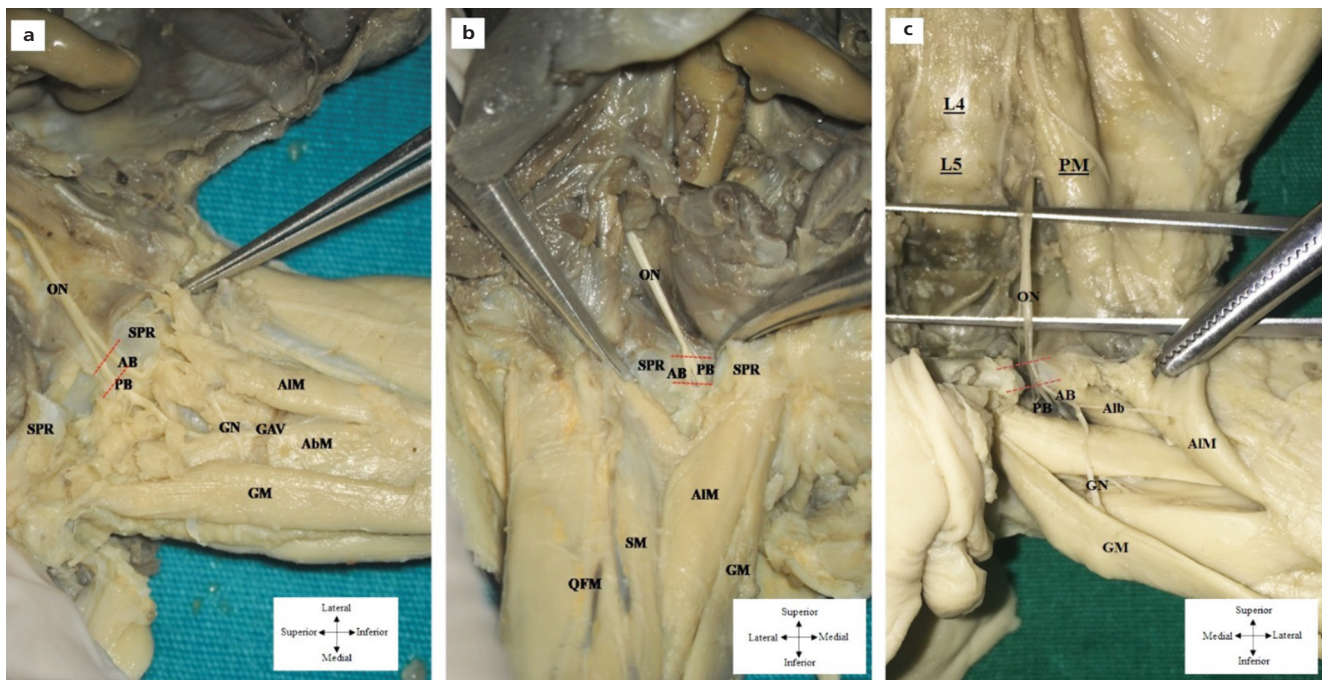
**Table 1**  
Demographic data belonging to fetuses.

Gestational age		Foot length (mm)	Number of sides	Number of cases	
Months	Weeks			Male	Female
V	18	25.55±0.70	6	2	1
	19	27.98±0.76	8	2	2
	20	30.72±0.99	14	1	6
VI	21	32.80±0.65	10	2	3
	22	34.50±1.06	12	5	1
	23	38.44±1.09	10	2	3
	24	40.71±1.03	8	3	1
VII	25	41.34±1.11	4	2	0
	26	45.56±0.89	6	1	2
	27	48.23±1.36	6	2	1
	28	52.14±0.90	2	1	0
VIII	29	53.30±0.15	2	1	0
	30	54.48±0.83	6	0	3
Total	22.85±3.35	37.48±8.32	94	24	23



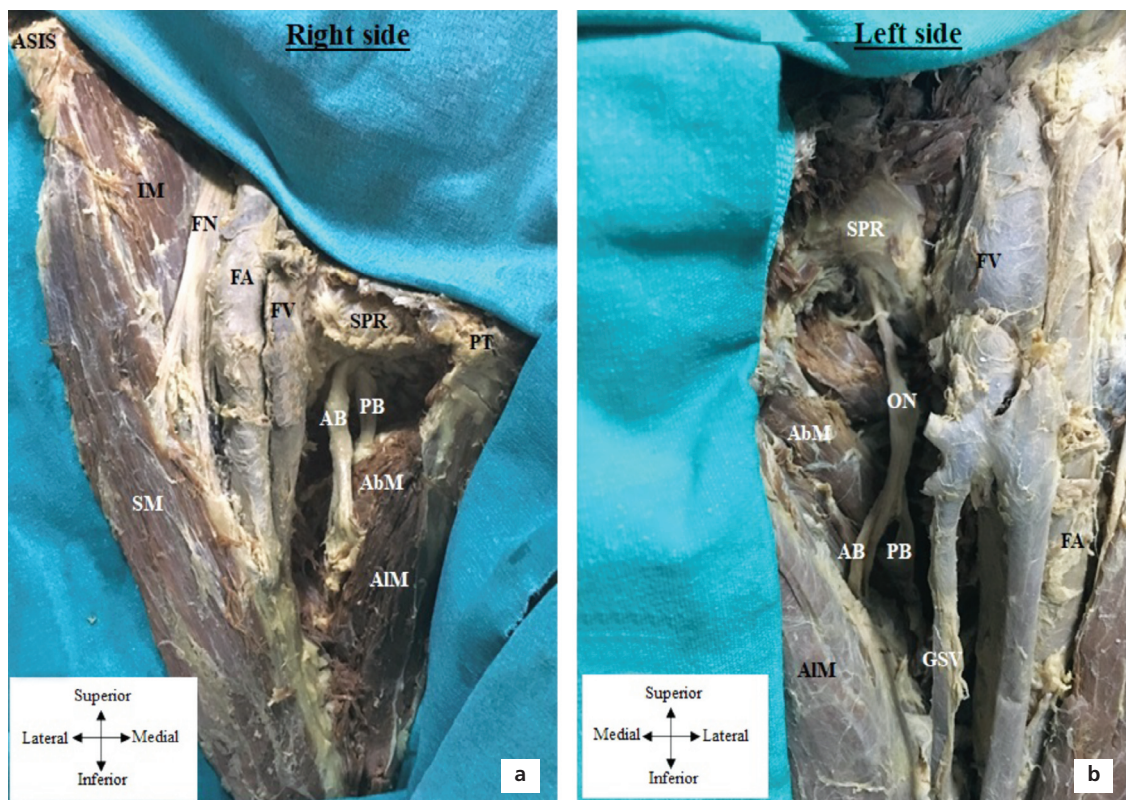
**Figure 2.** Schematic drawings of the branching pattern of the obturator nerve in fetuses (a–c) and in adult cadavers (d–e). AB: anterior branch of the obturator nerve; AbB: adductor brevis branch; AIB: adductor longus branch; ASIS: anterior superior iliac spine; GB: gracilis branch; OC: obturator channel; ON: obturator nerve; PB: posterior branch of the obturator nerve; PT: pubic tubercle.



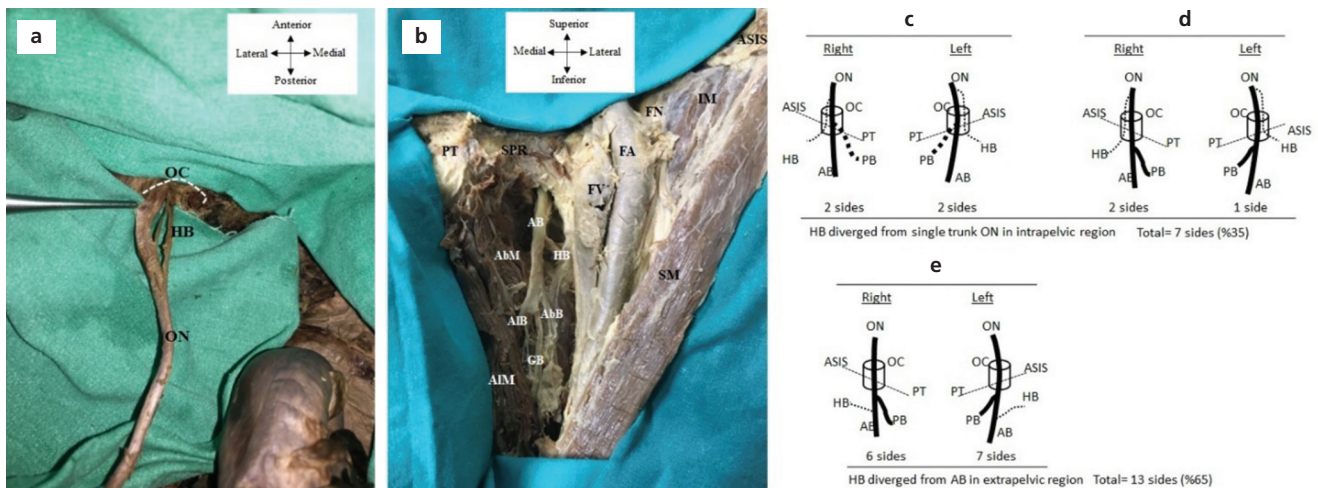


**Figure 3.** Anterior view of the pelvic and thigh regions showing bifurcation pattern of the obturator nerve in fetuses: (a) intrapelvic; (b) inside the obturator canal; (c) extrapelvic. AB: anterior branch of the obturator nerve; AIM: adductor longus muscle; GAV: artery and vein of gracilis muscle; GN: gracilis branch; GM: gracilis muscle; L4: 4th lumbar vertebra; L5: 5th lumbar vertebra; ON: obturator nerve; PB: posterior branch of the obturator nerve; PM: psoas major muscle; QFM: Quadriceps muscle; SM: sartorius muscle; SN: saphenous nerve, SPR: superior pubic ramus. Red dashed lines illustrate the obturator channel fold.

**Figure 4.** Anterior view of the pelvic and thigh regions showing bifurcation pattern of the obturator nerve in adult cadavers: (a) intrapelvic; (b) extrapelvic. AB: anterior branch of the obturator nerve; AbM: adductor brevis muscle, AIM: adductor longus muscle; ASIS: anterior superior iliac spine; FA: femoral artery; FN: femoral nerve; FV: femoral vein; GSV: great saphenous vein; IM: iliopsoas muscle; ON: obturator nerve; PB: posterior branch of the obturator nerve; PT: pubic tubercle; SM: sartorius muscle; SPR: superior pubic ramus.



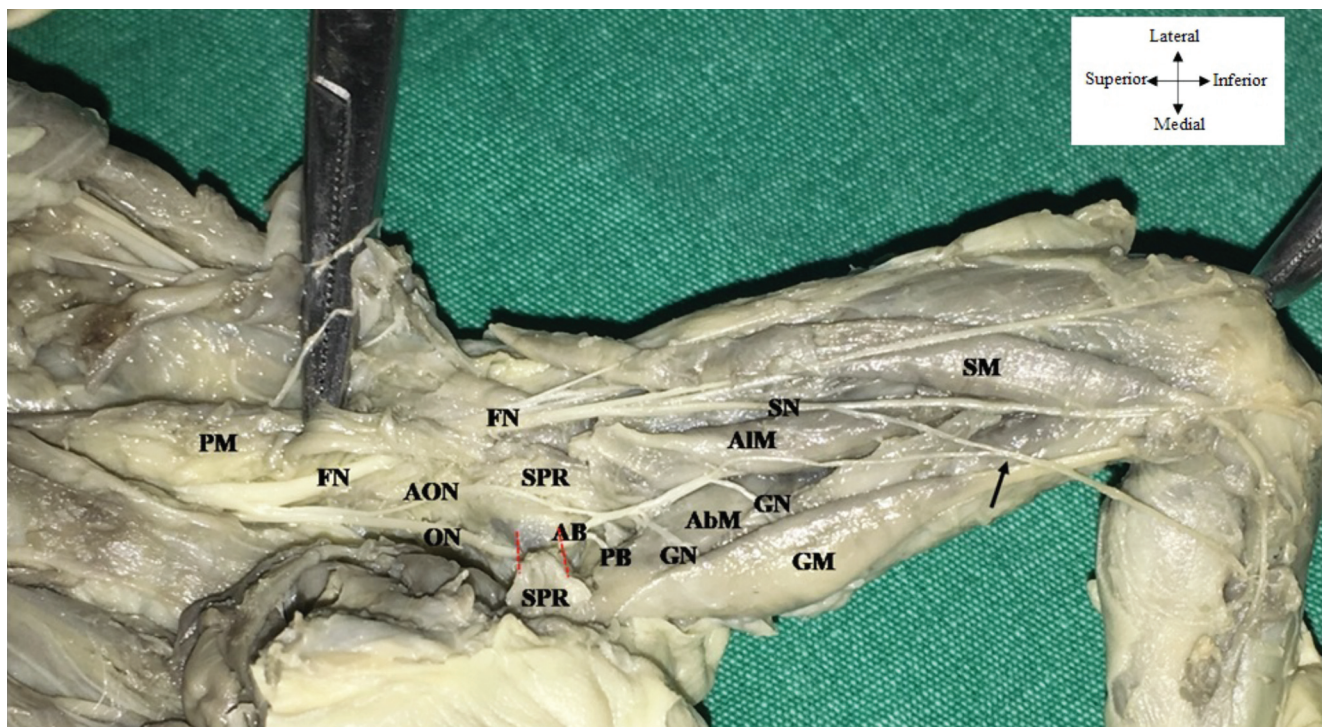




**Figure 5.** Hip branching patterns of the obturator nerve (a–e). (a) Superior view of pelvic region; (b) anterior view of the thigh. AB: anterior branch of the obturator nerve; AbB: adductor brevis branch; AbM: adductor brevis muscle, AIB: adductor longus branch; AIM: adductor longus muscle; ASIS: anterior superior iliac spine; FA: femoral artery; FN: femoral nerve; FV: femoral vein; GB: gracilis branch; HB: hip branch; IM: iliopsoas muscle; OC: obturator canal; PB: posterior branch of the obturator nerve; PT: pubic tubercle; SM: sartorius muscle; SPR: superior pubic ramus.

3.94 mm (Figure 6 and Table 2). The mean distance from SPR to the AB and PB diverging point was  $12.48 \pm 2.27$  mm (Figure 6 and Table 2). In addition to

these findings, in one of the fetuses, unilateral accessory obturator nerve (AON) was passing superior to the SPR and connected with AB (Figure 6).



**Figure 6.** Anterior view of the pelvic and thigh regions of a fetus showing communication between obturator nerve and accessory obturator nerve. AB: Anterior branch of the obturator nerve; AIM: adductor longus muscle; AON: accessory obturator nerve; GM: gracilis muscle; GN: gracilis nerve; ON: obturator nerve; PB: posterior branch of the ON; PM: psoas major muscle; QFM: quadriceps muscle; SM: sartorius muscle; SN: saphenous nerve; SPR: superior pubic ramus. Black arrow indicates the connection between saphenous and obturator nerves; red dashed lines illustrate the obturator channel fold.

## Discussion

The origin of ON can be quite diverse. For example, whilst ON often arise from the L2–L4 level,<sup>[21–23]</sup> it can emergence from L3–L4<sup>[21,22]</sup> or even T12–L5<sup>[21,22]</sup> levels. In this context, our findings seem to be consistent with the anatomical origin reported by Anloague et al.<sup>[23]</sup> On the other hand, revisiting its branching pattern (where the AB/PB diverges from the ON; sub-branches of the AB and PB; branching origin and pattern of nerves to the hip joint and muscles) is necessary to discuss its fundamental relevance to anesthetic interventions.

From an anesthesia perspective, a successful ONB can be defined as achieving the desired level of anesthesia on the relevant anatomical structures (e.g. hip joint capsule, medial side of the thigh, adductor group muscles, etc.) and completing the procedure in the least amount of time, with the least amount of puncture and the least amount of anesthetic substance volume while achieving maximum patient comfort with no or minimal complications. For this purpose, of course, the success of the procedure may vary depending on the target anatomical structure to be anesthetized. For example, to secure blockade of the hip articular branches, the chosen blockade approach should act on the most favorable proximal levels to guarantee blockade of the main ON closer to the AB and/or PB. Otherwise, the success of the anesthetic intervention may be insufficient or even fail due to possible variations, for example, hip joint branching. Since the list of anatomical structures innervated by the ON is long and it travels over a wide anatomical territo-

**Table 2**  
Position and location of neurovascular structures according to oblique and vertical lines.

Parameters	Mean±SD (mm)
Distance between ASIS–PT	118.92±8.43
Distance between PT–ON	26.61±3.94
Distance between PT–FV	38.66±4.18
Distance between PT–FA	49.13±4.48
Distance between PT–FN	64.33±5.16
Distance between SPR–AB/PB diverging point	12.48±8.27
Distance between SPR–AbB diverging point	24.65±8.77
Distance between SPR–GB diverging point	33.77±14.13

ASIS: anterior superior iliac spine; AB: anterior branch; AbB: adductor brevis branch; FA: femoral artery; FN: femoral nerve; FV: femoral vein; GB: gracilis branch; PB: posterior branch; PT: pubic tubercle; SPR: superior pubic ramus.

ry, successful access to selected structures can be problematic even with currently used anesthetic techniques (e.g. inguinal and pubic approach) (**Table 3**).

While efforts to improve methods for better ONB seem to be ongoing, these improvements will be aided by a focus on detailed anatomy, particularly the variations that can be seen in the branching and course of the nerve. The results of different anatomical studies on the main divergence point of the common ON are important in this regard. Any kind of ON branching within the pelvic region may result in inadequate anesthesia in clinical practice. Previous studies on adult cadavers and fetuses have shown that the ON branching point can be

**Table 3**  
Success rate based on the anesthetic approach.

Anesthetic approach	Targeted nerves and branches	Success rate (%)	Applied surgeries	Reference
3 in 1	Sensorial branches of femoral and lateral cutaneous femoral nerves Sensorial and motor branches of obturator nerve	16%	Above-below knee amputation, various knee surgeries	Atanassoff et al. <sup>[29]</sup>
		50%		Wallace et al. <sup>[30]</sup>
		52% for sensorial branches		Capdevilla et al. <sup>[31]</sup>
		32% for motor branches		
Labat's classic	Common ON	84%	Transurethral resection surgery	Jo et al. <sup>[9]</sup>
		84%		Moningi et al. <sup>[7]</sup>
		78%		Macalou et al. <sup>[14]</sup>
		74.1%		Aghamohammadi et al. <sup>[8]</sup>
Inguinal	Common ON or separately anterior and posterior branches	97.2%		Thallaj et al. <sup>[6]</sup>
		80%		Anagnostopoulou et al. <sup>[3]</sup>
		96.1%		Jo et al. <sup>[9]</sup>
		98%		Moningi et al. <sup>[7]</sup>
		97.1%		Aghamohammadi et al. <sup>[6]</sup>



**Table 4**

Bifurcation pattern of the obturator nerve (sides and %).

Study	Specimens	N (sides)	Branching pattern of the obturator nerve (sides and %)		
			Intrapelvic	Inside the channel	Extrapelvic
Anagnostopoulou et al. <sup>[3]</sup>	Adult cadavers	168	39 (23.22%)	87 (51.78%)	42 (25%)
Tshabalala <sup>[4]</sup>	Adult cadavers	201	4 (2%)	187 (93%)	10(5%)
Current study	Adult cadavers	20	0 (0%)	8 (40%)	12 (60%)
	Fetuses	94	8 (8.5%)	31 (33%)	55 (58.5%)
	Total: 114		8 (7%)	39 (34%)	67 (59%)

located in the pelvic region, and this branching pattern may exhibit a wide range of prevalence (0–23%) (**Table 4**). Although the studies of Anagnostopoulou et al.<sup>[3]</sup> and Tshabalala<sup>[4]</sup> included impressive numbers of adult cadavers being 168 and 201, respectively, the bifurcation pattern of ON within the pelvis was distributed quite differently between the studies (23%–39/168 vs. 2%–4/201) (**Table 4**). Furthermore, based on our observations in adult cadavers, no ON bifurcation is found in the pelvic region (0/20), whereas in fetuses (24–26 weeks) 8.5% (8/94) of nerve bifurcations occur in the intrapelvic region (**Table 4**). Considering that peripheral nerve development is no longer progressing at this fetal age, this 8.5% intrapelvic occurrence can probably be included in the adult rate. To our knowledge, our study is the first in the literature to illustrate the fetal anatomy of the ON. These three separate data set clearly show that the division of the ON into anterior and posterior branches can vary greatly.

All these data indicate that the variations of the ON bifurcation should be well known. An example of such an anatomical-anesthetic relationship is given in the study by Yoshida et al.<sup>[24]</sup> in which they aimed to perform obturator nerve blockade at the proximal level. These researchers clearly observed that with a single injection of blue dye into the thick fascia between the pectineus and obturator externus muscles of a cadaver, the dye traveled retrograde along the obturator canal. With this method, the AB and PB were stained both proximal and distal to the canal.<sup>[24]</sup> They called this procedure the US-guided pubic approach and also achieved 100% success using this approach in twenty patients undergoing transurethral bladder tumor resection.<sup>[20]</sup> However, this procedure was only tested in transurethral bladder tumor resection. Therefore, further studies are needed to examine whether this method is reproducible for other indications, such as blocking the hip joint branches for

the treatment of hip pain. In this sense, new anatomical studies with dye injection trials may be useful to test the efficacy of different ONB techniques (e.g. different landmarks and needle position, etc.).

The second important issue in ON anatomy is the origin and number of hip joint branches. Variations in hip branches may complicate nerve blockade to provide hip anesthesia. Therefore, knowledge of variations in hip joint branching can be crucial for anesthesiologists. Although we have not observed any cadavers with more than one hip joint branch, Anagnostopoulou et al.<sup>[3]</sup> encountered up to three branches. The prevalence of articular branches emerging from the main ON in the presence of a single articular branch was reported to be 35% and 47% in two studies, including ours (**Table 5**). Interestingly, when the number of articular branches is more than single, the origin of the branch is also multiply distributed, e.g. this branch can diverge from ON and PB or AB and PB as shown by Anagnostopoulou et al.<sup>[3]</sup> However, what is even more interesting is that the bifurcation of AB and PB has a highly variative state discussed in the paragraph above. For example, if the bifurcation of ON occurs in the pelvic region, the question of how the variability of hip branching occurs is unknown. Therefore, the co-occurrence of two variable factors (the site where the bifurcation of the ON and the hip branch from the ON and the AB/PB arise) may create even greater variability, which is clearly undesirable for anesthesiologists aiming at blocking the hip branches.

Regarding the use of ONB when targeting blockade of sensory innervation in the hip joint capsule (hip surgery, pain management), no matter how wide the anatomical variability, the chosen ONB method should have the ability to affect these dual-source hip joint branches, especially the main ON and PB at more proximal levels. Furthermore, while it remains unclear whether ONB alone can relieve acute postoperative

**Table 5**  
Distribution of hip articular branch of the obturator nerve.

Study	Specimens	N (sides)	Number and origin of hip articular branches		
Anagnostopoulou et al. <sup>[3]</sup>	Adult cadavers	168	Single branch	2 branches	3 branches
			Total: 104 sides (61.9%)	Total: 34 sides (20.24%)	Total: 30 sides (17.86%)
			ON (80 sides) (76.92%)	ON (16 sides) (47.05%)	ON (16 sides) (53.34%)
			AB (20 sides) (19.24%)	PB (14 sides) (41.17%)	Both ON and PB (8 sides) (26.66%)
			PB (4 sides) (3.84%)	Both ON and PB (4 sides) (11.76%)	Both AB and PB (6 sides) (20%)
Current study	Adult cadavers	20	Single branch	?	?
			20 sides (100%)		
			ON (7 sides) (35%)		
			AB (13 sides) (65%)		

pain, lateral femoral cutaneous nerve blockade in combination with ONB has been suggested to be beneficial.<sup>[25]</sup> However, it is clear that ONB is a vital component for indications related to the hip joint. Although ONB interventions have not been performed for indication of hip joint anesthesia, Taha et al.<sup>[20]</sup> demonstrated 100% successful blockade of both the AB and PB in all patients through a single application of local anesthetic to the interfascial plane between the pectineus and obturator externus muscles, combined with an ultrasound-guided proximal approach. Based on the high blockade rates of the AB and PB from Taha's<sup>[20]</sup> findings, it can be concluded that the proximal approach is also useful when blocking sensation in the hip joint capsule.

Since the occurrence of sudden thigh reflex during tumor resection in bladder is high and constituting complications,<sup>[16]</sup> desired level of temporary relief of adductor reflex via ONB is another important matter. In this regard, origin and the number of the muscular ramification of ON also bear importance to the selected ONB approach. Limited to just a few studies, a highly diverse state of the muscular ramification of ON was evident (**Table 6**). In our study, both cadaveric (20) and fetal sides (94) showed that in each side, AB gives triple muscular branches, while PB gave only single muscular branch. When tracing the course for respective innervation targets, those triplets arising from AB were reaching to adductor longus, brevis and gracilis muscles as well as the only muscular branch from PB was reaching to adductor magnus muscle in all the cases (**Table 6**). Commonly observed in three of the studies, when AB shows triple motif, they reached adductor longus, brevis and gracilis muscles (66.7–100%) (**Table 6**). PB motif was also evident. One distinct feature of our PB data was that it was giving single muscular branch (adductor mag-

nus muscle), whereas in other two studies, PB was sourcing multiple muscular branches (to adductor brevis, longus and external obturator muscles) (**Table 6**).

Since the occurrence of sudden thigh reflex is high and can be a complication during tumor resection in the bladder,<sup>[16]</sup> temporary relief of the adductor reflex at the desired level via ONB is another important issue. In this context, the origin and number of muscle branching of the ON is also important for the chosen ONB approach. Limited to only a few studies, it has been observed that the muscle branching of the ON shows considerable variation (**Table 6**). In our study, in both adult cadavers and fetal cadavers, it was shown that the AB gave three muscle branches on both sides, whereas the PB gave only one muscle branch. When the muscles to which these muscle branches went were examined, it was observed that the three branches from the AB reached the adductor longus, brevis and gracilis muscles, while the single muscle branch from the PB reached the adductor magnus muscle in all cases (**Table 6**). Commonly, in three of the studies, when the AB gave three muscle branches, these branches reached the adductor longus, brevis and gracilis muscles (66.7–100%) (**Table 6**). PB branching pattern was also evident. A distinctive feature of our PB data was that it gave a single muscle branch (adductor magnus muscle), whereas in the other two studies, PB gave multiple muscle branches (adductor brevis, longus and external obturator muscles) (**Table 6**).

After Taha et al.<sup>[20]</sup> showed promising results on the use of US-guided proximal approach to block the adductor muscle, different strategies for US-guided fascia iliac approach have been described and tested. The first group of studies suggested that the proximal approach was superior to the distal approach.<sup>[16]</sup> Thus, the distal

**Table 6**

Distribution of muscular branching of the obturator nerve.

Study	Specimens	N (sides)	Number of muscular branches from AB	Number of muscular branches from PB
Anagnostopoulou et al. <sup>[3]</sup>	Adult cadavers	168	<b>2 branches:</b> Adductor longus and gracilis 48 sides (28.57%) <b>3 branches:</b> Adductor longus, brevis and gracilis 112 sides (66.66%) <b>4 branches:</b> Adductor longus, brevis, gracilis and external obturator 8 sides (4.76%)	<b>Single branch:</b> Adductor magnus 23 sides (13.69%) <b>2 branches:</b> Adductor magnus and brevis 101 sides (60.11%) <b>3 branches:</b> Adductor magnus, brevis and external obturator 31 sides (19.04%) <b>4 branches:</b> Adductor magnus, brevis, longus and external obturator 12 sides (7.14%)
Tshabalala <sup>[4]</sup>	Adult cadavers	195	<b>3 branches:</b> Adductor longus, brevis and gracilis 195 sides (99%)	<b>2 branches:</b> Adductor magnus and external obturator 184 sides (89%) <b>3 branches:</b> Adductor magnus, brevis and external obturator 10 sides (11%)
Current study	Adult cadavers & fetuses	20 94	<b>3 branches:</b> Adductor longus, brevis and gracilis 114 sides (100%)	<b>Single branch:</b> Adductor magnus 114 sides (100%)

approach is relatively less suitable for blockade of the PB compared to the proximal approach. A comprehensive discussion on the comparison of distal and proximal approaches has been included in other studies.<sup>[16]</sup> Anatomical studies indicate that the AB innervates the adductor longus, brevis and gracilis muscles. Therefore, significant adductor muscle anesthesia is possible, even in the case of AB blockade alone. Accordingly, findings from clinical studies have shown that complete adductor blockade does not always occur; moreover, partial blockade is sometimes sufficient. For example, Han et al.<sup>[19]</sup> found that US-guided proximal and distal approaches did not significantly differ in the clinical efficacy of ONB in patients undergoing transurethral bladder tumor resection, but low-grade adductor muscle spasm was still evident. Interestingly, efforts to combine two different methods can also be effective. For example, in 2016, Yoshida et al.<sup>[24]</sup> demonstrated a successful ONB with US-guided pubic approach in twenty patients undergoing transurethral bladder tumor resection. Incidentally, using the newest approaches does not always mean that the older ones are less successful. Parallel to the exciting developments in the proximal approach or others, for example Choquet's inguinal approach is still considered a cutting edge procedure even in 2019.<sup>[19]</sup> A major limitation of comparing different approaches is that different approaches cannot be tested on the same patient.

Akkaya et al.<sup>[26]</sup> defined a triangle for the ONB surrounded by the SPR, pectineus and external obturator muscles in a study performed through the inguinal approach. In our study, a similar anatomical triangle was

observed with the SPR at the top, adductor longus muscle at the medial border and FV at the lateral border (**Figures 1 and 6**). In addition to variations in the branching pattern of the ON,<sup>[27–31]</sup> it has been reported that the presence of AON and possible anastomoses with the ON can be observed.<sup>[27,28]</sup> Akkaya et al.<sup>[28]</sup> interpreted the occurrence of such variations in terms of nerve blockade as AON blockade added to the ONB may increase clinical efficiency and quality of application.

## Conclusion

Although there is a strong visual guidance provided by US-guided procedures, more anatomical landmarks could serve to facilitate existing approaches as well as to establish new ones. In this sense, we currently present a detailed morphometric map composed of distances between specific anatomical landmarks. In addition to those in other studies on ON anatomy, the differential branching patterns of the ON in the pelvic region presented in this article should be considered under a single roof to avoid possible anesthesia errors and increase the success rate of the clinical procedures involved. Finally, we believe that scientific collaborations of anesthesiologists with anatomists have a great potential to improve the fundamentals of anesthesiology.

## Limitations

The first limitation of the study was that we did not have adult female cadavers suitable for dissection in our inventory and therefore could not discuss the differences between the sexes. However, we were able to perform



evaluations for both sexes in fetuses. The second limitation is that we were not able to identify the branches to the hip joint in pelvic or thigh dissections due to the difficulty of dissection in fetuses. Another limitation is that the measurements obtained from fixed cadavers could not be scanned on patients with ultrasound support. This situation can be supported by new studies in the future.

## Acknowledgement

We thank to donor of human cadavers and fetuses. Also, we thank to the Pathology and Obstetrics and Gynecology Departments of Mersin University Hospital that contributed to the acquisition of the materials in the Anatomy inventory.

## Conflict of Interest

The authors declare that they have no conflict of interest.

## Author Contributions

TK: project development, data collection, analysis, supervision, and manuscript writing; OB: data collection, analysis; ŞR: supervision, participated in evaluation of clinician perspective; ABÖ: supervision, participated in evaluation of anatomical perspective; NCO: manuscript writing and analysis, participated in evaluation of anatomical perspective. All authors reviewed the manuscript.

## Ethics Approval

Whole dissections and anatomical protocol of the study were approved by Mersin University, Ethics Board of Clinical Research (2019/278). Human cadaver and post-mortem human fetuses used in this study are legally registered in the educational and research gross anatomical archive of the Anatomy Department of Mersin University, Faculty of Medicine. This study accordance with recognized standards of Helsinki Declaration.

## Funding

None.

## References

1. Standring S. Gray's anatomy: the anatomical basis of clinical practice. 40th ed. Edinburgh (Scotland): Elsevier Churchill Livingstone; 2008. p. 1551.
2. Bergman RA, Afifi AK, Miyauchi R. Illustrated encyclopedia of human anatomic variation. Opus III: Nervous system: Plexuses [Internet]. [Retrieved on October 11, 2022]. Available from: <https://www.anatomyatlases.org/AnatomicVariants/NervousSystem/Text/ObturatorNerve.shtml>
3. Anagnostopoulou S, Kostopanagiotou G, Paraskeuopoulos T, Chantzi C, Lolis E, Saranteas T. Anatomic variations of the obturator nerve in the inguinal region: implications in conventional and ultrasound regional anesthesia techniques. *Reg Anesth Pain Med* 2009;34:33–9.
4. Tshabalala ZN. The anatomy and clinical implications of the obturator nerve and its branches (Dissertation submitted in full fulfilment of the requirements for the degree Master of Science in Anatomy, University of Pretoria) 2015. [Internet]. [Retrieved on October 11, 2022]. Available from: [https://repository.up.ac.za/bitstream/handle/2263/53048/Tshabalala\\_Anatomy\\_2015.pdf?sequence=1&isAllo wed=y](https://repository.up.ac.za/bitstream/handle/2263/53048/Tshabalala_Anatomy_2015.pdf?sequence=1&isAllo wed=y)
5. Kumka M. Critical sites of entrapment of the posterior division of the obturator nerve: anatomical considerations. *J Can Chiropr Assoc* 2010;54:33–42.
6. Thallaj A, Rabah D. Efficacy of ultrasound-guided obturator nerve block in transurethral surgery. *Saudi J Anaesth* 2011;5:42–4.
7. Moningi S, Durga P, Ramachandran G, Murthy PV, Chilumala RR. Comparison of inguinal versus classic approach for obturator nerve block in patients undergoing transurethral resection of bladder tumors under spinal anesthesia. *J Anaesthesiol Clin Pharmacol* 2014; 30:41–5.
8. Aghamohammadi D, Gargari RM, Fakhari S, Bilehjani E, Poorsadegh S. Classic versus inguinal approach for obturator nerve block in transurethral resection of bladder cancer under spinal anesthesia: a randomized controlled trial. *Iran J Med Sci* 2018;43:75–80.
9. Jo YY, Choi E, Kil HK. Comparison of the success rate of inguinal approach with classical pubic approach for obturator nerve block in patients undergoing TURB. *Korean J Anesthesiol* 2011;61:143–7.
10. Enneking FK, Chan V, Greger J, Hadzić A, Lang SA, Horlocker TT. Lower-extremity peripheral nerve blockade: essentials of our current understanding. *Reg Anesth Pain Med* 2005;30:4–35.
11. McNamee DA, Parks L, Milligan KR. Post-operative analgesia following total knee replacement: an evaluation of the addition of an obturator nerve block to combined femoral and sciatic nerve block. *Acta Anaesthesiol Scand* 2002;46:95–9.
12. Marhofer P, Nasel C, Sitzwohl C, Kapral S. Magnetic resonance imaging of the distribution of local anesthetic during the three-in-one block. *Anesth Analg* 2000;90:119–24.
13. Labat G. Regional anesthesia: its technic and clinical application. 1st ed. Philadelphia (PA): WB Saunders; 1923. 496 p.
14. Macalou D, Trueck S, Meuret P, Heck M, Vial F, Ouologuem S, Capdevila X, Virion JM, Bouaziz H. Postoperative analgesia after total knee replacement: the effect of an obturator nerve block added to the femoral 3-in-1 nerve block. *Anesth Analg* 2004;99:251–4.
15. Winnie AP, Ramamurthy S, Durrani Z. The inguinal paravascular technic of lumbar plexus anaesthesia: the “3-in-1” block. *Anesth Analg* 1973;52:989–96.
16. Yoshida T, Nakamoto T, Kamibayashi T. Ultrasound-guided obturator nerve block: a focused review on anatomy and updated techniques. *BioMed Res Int* 2017;2017:7023750.
17. Wassef MR. Interadductor approach to obturator nerve blockade for spastic conditions of adductor thigh muscles. *Reg Anesth* 1993;18: 13–7.
18. Choquet O, Capdevila X, Bennourine K, Feugeas JL, Bringuier-Branchereau S, Manelli JC. A new inguinal approach for the obturator nerve block: anatomical and randomized clinical studies. *Anesthesiology* 2005;103:1238–45.

19. Han C, Ma T, Lei D, Xie S, Ge Z. Effect of ultrasound-guided proximal and distal approach for obturator nerve block in transurethral resection of bladder cancer under spinal anesthesia. *Cancer Manag Res* 2019;11:2499–505.
20. Taha AM. Brief reports: ultrasound-guided obturator nerve block: a proximal interfascial technique. *Anesth Analg* 2012;114:236–9.
21. Horwitz MT. The anatomy of (A) the lumbosacral nerve plexus-its relation to variations of vertebral segmentation, and (B) the posterior sacral nerve plexus. *Anat Rec* 1939;74:91–107.
22. Arora D, Kaushal S, Singh G. Variations of lumbar plexus in 30 adult human cadavers – a unilateral prefixed plexus. *The International Journal of Plant, Animal and Environmental Sciences* 2014;4:225–8.
23. Anloague PA, Huijbregts P. Anatomical variations of the lumbar plexus: a descriptive anatomy study with proposed clinical implications. *J Man Manip Ther* 2009;17:e107–4.
24. Yoshida T, Onishi T, Furutani K, Baba H. A new ultrasound-guided pubic approach for proximal obturator nerve block: clinical study and cadaver evaluation. *Anaesthesia* 2016;71:291–7.
25. Rashid S, Vandermeer B, Abou-setta AM, Beaupre LA, Jones CA, Dryden DM. Efficacy of supplemental peripheral nerve blockade for hip fracture surgery: multiple treatment comparison. *Can J Anesth* 2013;60:230–43.
26. Akkaya T, Ozturk E, Comert A, Ates Y, Gumus H, Ozturk H, Tekdemir I, Elhan A. Ultrasound-guided obturator nerve block: a sonoanatomic study of a new methodologic approach. *Anesth Analg* 2009;108:1037–41.
27. Katritsis E, Anagnostopoulou S, Papadopoulos N. Anatomical observation on the accessory obturator nerve (based on 1000 specimens). *Anat Anz* 1980;148:440–5.
28. Akkaya T, Comert A, Kendir S, Acar HI, Gumus H, Tekdemir I, Elhan A. Detailed anatomy of accessory obturator nerve blockade. *Minerva Anesthesiol* 2008;74:119–22.
29. Atanasoff PG, Weiss BM, Brull SJ, Horst A, Külling D, Stein R, Theiler I. Electromyographic comparison of obturator nerve block to three-in-one block. *Anesth Analg* 1995;81:529–33.
30. Wallace JB, Andrade JA, Christensen JP, Osborne LA, Pellegrini JE. Comparison of fascia iliaca compartment block and 3-in-1 block in adults undergoing knee arthroscopy and meniscal repair. *AANA J* 2012;80:S37–44.
31. Capdevila X, Biboulet PH, Bouregba M, Barthelet Y, Rubenovitch J, d'Athis F. Comparison of the three-in-one and fascia iliaca compartment blocks in adults: clinical and radiographic analysis. *Anesth Analg* 1998;86:1039–44.

**ORCID ID:**

T. Koç 0000-0001-6970-3351; O. Berger 0000-0002-4932-8758;  
S. Rumeli 0000-0002-7042-6934; A. Bobuş Örs 0000-0003-4026-5460;  
N. C. Öztürk 0000-0001-9459-2120


**Correspondence to:** Turan Koç, PhD, Assist. Prof. Dr.

Department of Anatomy, Kahramanmaraş Sütçü İmam University Faculty of  
Medicine, Kahramanmaraş, Türkiye

Phone: +90 344 300 26 35

e-mail: turann\_koc@yahoo.com

*Conflict of interest statement:* No conflicts declared.

This is an open access article distributed under the terms of the Creative Commons Attribution-NonCommercial-NoDerivs 4.0 Unported (CC BY-NC-ND4.0) Licence (<http://creativecommons.org/licenses/by-nc-nd/4.0/>) which permits unrestricted noncommercial use, distribution, and reproduction in any medium, provided the original work is properly cited. *How to cite this article:* Koç T, Beger O, Rumeli Ş, Bobuş Örs A, Öztürk NC. Revisiting the obturator nerve anatomy with a nerve blocking perspective. *Anatomy* 2023;17(1):22–33.