

## PAPER DETAILS

TITLE: Otoerotizm Kaynakli Mesane İçinde Yedi Pil

AUTHORS: Haluk SÖYLEMEZ,Hakan ÇAKICI,Ahmet Ali SANCAKTUTAR,Murat ATAR,Yasar  
BOZKURT

PAGES: 49-50

ORIGINAL PDF URL: <https://dergipark.org.tr/tr/download/article-file/2016956>

## Olgu Sunumu ve Literatür Derlemesi

# Seven Batteries in the Bladder Due to Autoerotism

*Otoerotizm Kaynaklı Mesane İçinde Yedi Pil*

Haluk SÖYLEMEZ<sup>1</sup>, Hakan ÇAKICI<sup>2</sup>, Ahmet Ali SANCAKTUTAR<sup>1</sup>,  
Murat ATAR<sup>1</sup>, Yaşar BOZKURT<sup>1</sup>

<sup>1</sup>Dicle University, Medical Faculty, Department of Urology, Diyarbakir

<sup>2</sup>Erzincan State Hospital, Department of Urology, Erzincan

### Abstract

Recently the frequency of foreign bodies in the urinary tract is increasing. Except the iatrogenic reasons, most foreign bodies in the lower genitourinary tract are self-inserted via the urethra as the result of exotic impulses, psychometric problems, sexual curiosity or sexual practice while intoxicated. Although the presentation of urinary foreign bodies has frequently been described in the medical literature, the insertion of foreign bodies through the urethra for reasons of sexual gratification has rarely been considered. A 23-year-old young girl admitted to emergency service complaining of macroscopic hematuria and pelvic pain for last 2 days. About 6-7 radio-opaque density were observed on the plain X-ray and thought to be multiple batteries. Then she gave a history of insertion of many batteries into the urethra six days ago. Under spinal anesthesia a cystoscopic examination was performed. Seven batteries were observed in the bladder with hemorrhage and edema of the mucosa without any perforation and a Pfannenstiel incision was made and batteries were removed successfully. Here we reported a case of self-inserted seven batteries in to the bladder due to autoerotism with a brief review of the literature.

**Key Words:** Foreign bodies, Urinary bladder, Autoerotism

### Özet

Son zamanlarda üriner sistemde yabancı cisim görülme sıklığı artmaktadır. İyatrojenik sebepler dışında kalanlar çoğunlukla üretral yolla alt üriner sisteme kişinin kendi kendine yerleştirmesiyle görülür ve en sık sebepleri; egzotik uyarılma, psikolojik problemler, seksüel tatmin veya uyuşturucu madde kullanımı sırasındaki seksüel deneyimler olarak sayılabilir. Tıp literatüründe üriner sistem yabancı cisimleri sıkça tanımlanmış olmasına rağmen, seksüel tatmin nedeniyle üretradan yerleştirilen yabancı cisimler daha az sıklıkla tanımlanmıştır. 23 yaşında genç kız son iki gündür süren hematüri ve pelvik ağrı şikayeti acil servise başvurdu. Düz karın grafisinde görülen 6-7 adet opasitenin birçok sayıda pil olduğu düşünüldü. Daha sonra hasta, 6 gün önce üretrasından içeriye birçok pil soktuğu bilgisini verdi. Spinal anestezi altında sistoskopik değerlendirme yapıldı. Mesane içerisinde perforasyona neden olmayan ancak kanama ve ödeme neden olan 7 adet kalem pil görüldü. Pfannenstiel kesi yaparak bütün piller başarılı olarak açık operasyonla çıkarıldı. Bu yazıda kendi kendine otoerotizm nedeniyle mesaneye yerleştirilmiş 7 adet kalem pili kısa bir literatür bilgisi eşliğinde sunmayı amaçladık.

**Anahtar Kelimeler:** Yabancı cisim, Mesane, otoerotizm

### Introduction

The presence of foreign bodies in bladder is always an interesting issue. A large number of cases are reported in the literature and management of them is important in urological practice.

Objects that have been found in the urinary bladder include thermometers, electrical wires, bullets, encrusted sutures, chicken bones, wooden sticks, intrauterine contraceptive devices, surgical staples with stones, ribbon gauze, broken pieces of endoscopic instruments and many other items (1). Self inserted batteries into the bladder are rarely reported in the literature (2-4).

Foreign bodies have been inserted as the result of curiosity, autoerotic stimulation, psychological disorders or medical procedures (5) Although the foreign body may causes dysuria, hematuria, urinary tract infection and severe pain, they can be asymptomatic or minimal symptomatic for a long time (6).

Here we present seven batteries in the bladder as unusual foreign bodies in which autoerotism are the most likely explanation for the urethral insertion of a foreign body.

### Case

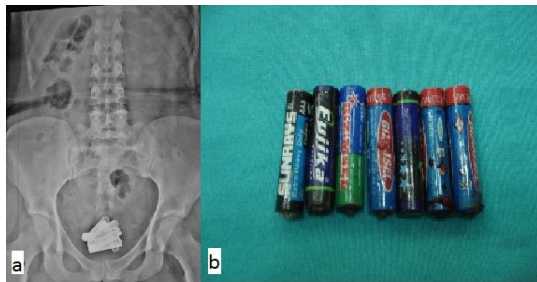
A 23-year-old young girl complaining of macroscopic hematuria and pelvic pain was referred to emergency service owing to aggravated frequency that had lasted for 2 days. At first, she did not tell about abnormal history. Laboratory findings revealed macroscopic hematuria and pyuria in routine urine analysis, and the routine blood and biochemical analysis were normal. About 6-7 radio-opaque density were observed on the plain X-ray and thought to be multiple batteries (Figure 1a). After the plain X-ray she accepted that she had a history of insertion of many batteries into the urethra six days ago. The patient was examined by a gynecologist to exclude a vaginal foreign body, simultaneously.

Under spinal anesthesia a cystoscopic examination was performed. Seven batteries were observed in the bladder with hemorrhage and edema of the mucosa

without any perforation. To avoid the risk of bladder and urethral injury, a cystolithotomy was planned. A pfannenstiell incision was made and batteries were removed successfully (Figure 1b). The postoperative recovery was uneventful and the patient was discharged 3 days after the operation. The patient was examined by a psychiatrist before and after the operation. She had no severe psychiatric disease except minor depression.

### Discussion

Causes of foreign bodies in lower urinary tract include iatrogenic during urological procedure, traumatic aspect, migration from other organs and self-insertion. The self-insertion of objects such as eyebrow pencil, wrist watch, cable, rubber tube, electrical cable, cocaine, hair, hair clip, hair pin, ballpoint pen, or even cucumber has been reported in the literature (1, 7). Batteries have been reported rarely (2-4,8). The most common reason for self-insertion of a foreign body into the urethra is of erotic or sexual reasons (9). The majority of the cases are associated with dementia, other psychiatric abnormalities, or drug intoxication.



**Figure 1.** Self inserted batteries: a) Abnormal calcifications were observed in pelvic cavity on plain X-ray film. b) Seven batteries were removed from bladder with cystolithotomy.

A self-inserted foreign body in the urinary tract is a rare condition. With careful history taking, physicians can get information about the type of foreign body and duration of insertion. To identify the exact size, number, and location of foreign body, radiological evaluation is essential. In most cases, a plain abdominopelvic X-ray is enough to locate and identify foreign bodies. However in some cases ultrasonography or computed tomography may be necessary as the next step (10). Minimally invasive procedures such as endoscopic management to minimize bladder and urethral injuries are usually preferred procedures. However, in some cases, open procedures such as perineal urethrotomy or suprapubic cystostomy is recommended (1, 9).

Here we reported a girl who has inserted seven batteries through the urethra. In this case erotic or sexual satisfaction is the typical reason to explain a

foreign body in the bladder, also known as autoerotism. In our case, patient was examined by a psychiatrist and recommended to undergo psychiatric observation.

In conclusion, foreign bodies in the lower urinary tract can be removed and cured with immediate diagnosis and proper management. In self inserted cases, psychiatric consultation should be done to prevent further attempts at insertion of other foreign bodies in the urinary tract.

### References

1. Mannan A, Anwar S, Qayyum A, Tasneem RA. Foreign bodies in the urinary bladder and their management: a pakistani experience. *Singapore Med J* 2011; 52: 24-8.
2. Ayyildiz A, Gurdal M, Nuhoglu B, Ersoy E, Huri E, Germiyanoglu C. A foreign body self-inserted via the urethra into the bladder: pocket battery. *Int Urol Nephrol* 2003; 35: 251-2.
3. Friedrichs G, Gartner C, Gartner S, Schoepner H. Hematuria due to foreign bodies in a woman-patient with the munchausen syndrome. *Z Gesamte Inn Med* 1977; 32: 149-50.
4. Gogus C, Kilic O, Haliloglu A, Gogus O. A very unusual intravesical foreign body in a male. *Int Urol Nephrol* 2002; 34: 203-4.
5. Johnin K, Kushima M, Koizumi S, Okada Y. Percutaneous transvesical retrieval of foreign bodies penetrating the urethra. *J Urol* 1999; 161: 915-6.
6. van Ophoven A, de Kernion JB. Clinical management of foreign bodies of the genitourinary tract. *J Urol* 2000; 164: 274-87.
7. Bantis A, Sountoulides P, Kalaitzis C, et al. Perforation of the urinary bladder caused by transurethral insertion of a pencil for the purpose of masturbation in a 29-year-old female. *Case Report Med* Published online 2010 August 25; 1-3 doi: 10.1155/2010/460385 [http://www.ncbi.nlm.nih.gov/entrez/query.fcgi?cmd=Retrieve&db=PubMed&dopt=Citation&list\\_uids=20862362](http://www.ncbi.nlm.nih.gov/entrez/query.fcgi?cmd=Retrieve&db=PubMed&dopt=Citation&list_uids=20862362)
8. Sneed RC, Bell RF. The dauphin of munchausen: factitious passage of renal stones in a child. *Pediatrics* 1976; 58: 127-30.
9. Moon SJ, Kim DH, Chung JH, et al. Unusual foreign bodies in the urinary bladder and urethra due to autoerotism. *Int Neurourol J* 2010; 14: 186-9.
10. Rahman NU, Elliott SP, Mc Aninch JW. Self-inflicted male urethral foreign body insertion: endoscopic management and complications. *BJU Int* 2004; 94: 1051-3.

### Corresponding Author

Yrd. Doç. Dr. Haluk SÖYLEMEZ  
Dicle University Medical Faculty Department of  
Urology, Diyarbakir  
drhaluks@yahoo.com