


## PAPER DETAILS

TITLE: TREATMENT of MAXILLARY LATERAL INCISOR LOSS USING A FIBRE REINFORCED  
ADHESIVE BRIDGE: CASE REPORT

AUTHORS: Hilal ÇİFTÇİ,Zeynep YESİL DUYMUS,Nuran DİNÇKAL YANIKOĞLU

PAGES: 31-35

ORIGINAL PDF URL: <https://dergipark.org.tr/tr/download/article-file/274150>



## TREATMENT of MAXILLARY LATERAL INCISOR LOSS USING A FIBRE REINFORCED ADHESIVE BRIDGE: CASE REPORT

### ÜST YAN KESİCİ DİŞ EKSİKLİĞİNİN FİBERLE GÜÇLENDİRİLMİŞ KÖPRÜ İLE TEDAVİSİ: VAKA SUNUMU

Dr. Hilal ÇİFTÇİ\*

Prof. Dr. Zeynep YEŞİL DUYMUŞ\*\*

Prof. Dr. Nuran DİNÇKAL YANIKOĞLU\*

**Makale Kodu/Article code:** 2589

**Makale Gönderilme tarihi:** 04.02.2016

**Kabul Tarihi:** 22.08.2016

#### ABSTRACT

In the absence of a single tooth, prosthetic treatments such as conventional fixed prosthesis and implant supporting single crown can be applied to the edentulous area.

Adhesive bridges strengthened with fibre can be used as alternative treatments because they are economic and easy to repair. One of the other reasons to use the adhesive bridges as alternative treatment is that they do not require much preparation for supported teeth.

In this study, we report a case of fibre reinforced adhesive bridge for work out esthetical, phonetic and functional problems in a patient who lost maxillary lateral incisor.

**Key Words:** Maxillary lateral incisor, fibre-reinforced, adhesive bridge

#### ÖZ

Tek diş eksikliğinde dişsiz boşluğun giderilmesi için, geleneksel sabit protez veya implant üstü tek kron gibi protetik tedaviler uygulanabilmektedir. Ayrıca günümüzde, fiberle güçlendirilmiş adeziv köprüler ekonomik olmaları, kolay tamir edilebilmeleri ve destek dişlerde fazla preparasyon gerektirmemeleri gibi nedenlerle alternatif tedavi seçenekleri arasında yer almaktadır.

Bu çalışmada, travma nedeni ile üst sol yan kesici dişini kaybetmiş bir hastadaki estetik, fonetik ve fonksiyonel bozukluğun giderilmesi amacıyla uygulanan fiberle güçlendirilmiş köprü sunulmuştur.

**Anahtar Kelimeler:** Üst çene yan kesici diş, fiberle güçlendirme, adeziv köprü

#### INTRODUCTION

In view of development of adhesive techniques, conservative therapies that require fewer tooth preparation may be administered.<sup>1-5</sup> Despite the fact that the metal resin has been found successful mechanically and clinically the reflection of the underlying metal motivated researchers to search for a more aesthetic material.<sup>6</sup> Development of fibre-reinforced composites (FRC) has given an opportunity for metal-free restorations which are aesthetic and durable at the same time.<sup>7-13</sup> In addition, unlike metals, FRC restorations are lack of the corrosion property and this eliminates the risk of allergic reaction.<sup>14</sup>

Fibre-reinforced composite resin bridges can be applied in the restoration of lost teeth due to trauma or failed endodontic treatment, when periodontal prognosis of the teeth adjacent to the missing tooth is uncertain, in the cases of patients cannot receive local anaesthesia or long-term therapy<sup>15-20</sup> or when fixed placeholder is required to be used after orthodontic treatment and in cases where temporary restoration is necessary to be applied to patients prior to installations. However, it cannot be applied where a long edentulous space is present, in deep bite cases, in the presence of large restorations of support teeth and diastema.<sup>20-24</sup>

In fibre-reinforced composite resin bridges, fibres were used to form substructure and hybrid or

\*<sup>1</sup>Ataturk University, Faculty of Dentistry, Department of Prosthodontics,

\*\*Recep Tayyip Erdogan University, Faculty of Dentistry, Department of Prosthodontics



micro-filler composites were used to cover substructure.<sup>6,9</sup> In dentistry, carbon-graphite, aramid, polyethylene and glass were used as fibre constitution in FRC. Because of carbon-graphite and aramid fibres are aesthetically unacceptable, composites reinforced with polyethylene and glass were preferred. Artificial acrylic teeth, porcelain teeth, composite resin teeth or patient's own teeth may be used as pontic in adhesive bridges reinforced with fibres.<sup>7,25</sup>

In this case presentation FRC restoration which was strengthened with polyethylene fibre and prepared with composite resin in order to bring back the aesthetics, function and phonation of a patient who lost a maxillary lateral tooth is reported.

### CASE

A 25-year old male patient who lost a maxillary left lateral tooth due to trauma admitted to the Department of Prosthodontics, Faculty of Dentistry, University of Atatürk to solve the aesthetic problems. Intraoral examination showed that there was no other missing tooth and no restoration on support teeth; the periodontal tissues were healthy and edentulous space could be used as a support for adjacent teeth. No pathological examination was observed in the respective area during radiographic examination (Figure 1).

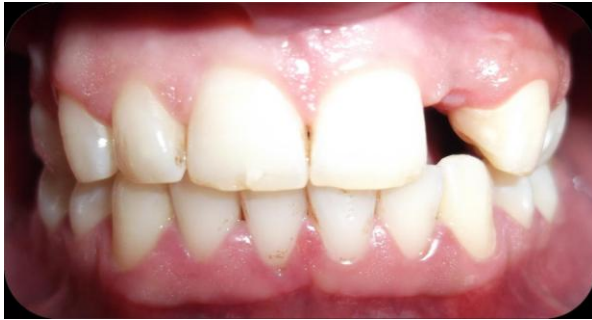

Figure 1. Pre treatment.

Treatment options were explained to the patient. The patient rejected the application of implant supporting single crown due to the financial reasons while did not prefer the conventional fixed bridge due to not being conservative. The fibre-reinforced composite bridge, which is a more conservative and aesthetics approach, was decided to be applied. After patient's consent, the impression was taken by

additional silicone impression material (Zhermack Elite HD<sup>+</sup>, 45021 Badia Polesue, Italy) and hard plaster (Ultrarock Klassek D-63654, Megadental, Bidingen, Germany) was poured to obtain a dental cast. The stone cast of the opposing jaw (mandible) was prepared by pouring model plaster into the impression taken by alginate (Kromopan Alginate, Lascod, Florence, Italy). The models were sent to the laboratory after taking waxed closure of the patient.

The dental cavity and lingual surfaces of supporting teeth were measured by calliper in order to determine the length of the fibre required. The polyethylene fibre was cut by scissors accordingly (Ribbond; ribbond, Seattle, WA, USA).

Model was isolated with lac (gypsum and acrylic separator (Sepia)) then, nano hybrid composite resin (Grandio, VOCO, Cuxhaven, Germany) was put and plasma treated polyethylene fibre was placed to prepare the substructure of the bridge.

Fibre substructure was allowed to come in the middle of the edentulous space. Fibre and composite structure was polymerized by applying light from all directions for 20 seconds with intensity of 550mW/cm<sup>2</sup> with the aid of a light emitting device (Optilight Digital, Gnatus Dental S.R.L. Casagiove, Italy). The lateral tooth body (Pontic) was shaped by condensation technique. After completion of the restoration, the routine finishing and polishing procedures applied in the resin composite restorations were performed.

The lingual surfaces of adjacent teeth were treated with 37% phosphoric acid for 15 seconds. Subsequently phosphoric acid was removed by washing with water and air dried. A self-etching adhesive system (Clearfil SE Bond, Kuraray, Kurashiki, Japan) was applied to the respective regions according to the manufacturer's instructions and polymerized for 10 seconds by using a LED light device (Elipar FreeLight II, 3M ESPE, USA).

Length of the exposed ends of the fibre material was adjusted to the lingual surfaces of adjacent teeth with the help of special cutting scissors. Prior to application fibre was soaked in to bonding material (CLEARFIL SE BOND, Kuraray, Okayama Japan), and then polymerized with LED light device and then, was adapted to the adjacent teeth with nano and polymerized for 40 seconds. Composite surfaces were fixed and polishing procedure was

performed by composite finishing burs (Mani, Diascholarship, Tokyo, Japan) and composite polishing discs (Sof-Lex, 3M-ESPE, St. Paul, USA) (Figure 2).

The treatment was finished in the same month and followed up for a year.

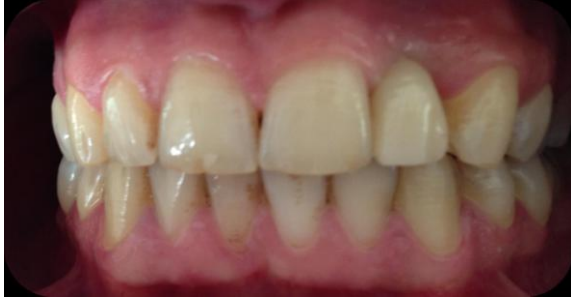

Figure 2. Post treatment.

## DISCUSSION

The success of the restoration depends on having a good treatment plan and choosing the right material.<sup>16</sup> During the treatment plan the localization of the teeth, the length of the edentulous space and the patient's occlusion should be evaluated.<sup>26</sup>

The fibre-reinforced composite resin bridges seem highly natural due to the semi-permeable property of FRC substructure. Therefore this gives a great advantage to FRC applications. The advantage of FRC applications over veneer crowns is that the former does not lead to attrition of the opposing tooth.<sup>14,27</sup> However, FRC applications have some disadvantages such as requirement of a meticulous work and limited load-carrying capacity. The most controversial aspect of this kind of restorations are their degree of resistance to the chewing forces.<sup>28</sup> In addition, even there is a break of polyethylene fibre reinforced bridge, the strip-like structure of the material avoids its possibility of tearing and becoming completely unusable.<sup>23</sup> Also, the broken part can be easily repaired.<sup>29</sup>

Gonulol et al.<sup>29</sup> have solved both aesthetical and functional problems with FRC restorations in patients who lost the maxillary incisor tooth. Moreover, they reported long-term follow-up data. In a case, they could not receive good results with FRC in first premolar tooth. Because of limited load-carrying capacity, these restorations are not suitable for the premolar and molar regions.

Kuşgoz et al.<sup>23</sup> reported 2 year follow-up results of three cases with FRC in loss of maxillary incisor. During the 2 year follow-up time, no aesthetic or phonetic problem was observed. Moreover, these restorations have easily suited to the therapy.

Unlu and Belli<sup>22</sup> have determined that FRC adhesive bridges showed acceptable success in 3 year clinical follow-up.

Ustun et al.<sup>30</sup> have established that adhesive bridges reinforced with polyethylene fibre could be a good treatment option in short-term conditions.

Clinical studies have shown that FRC bridges can be used without problem up to 5-10 years.<sup>31,32</sup>

Although, initially, the fibre-reinforced composite dental bridge applications were considered as a temporary method for the restoration of front region teeth in the absence of a single tooth, because of its ease of preparation and non-invasive property, it can be used in appropriate cases as a permanent restoration.<sup>29</sup>

In this study, the aesthetic aspects and polishing were achieved successfully since an FRC restoration was applied to the patient and the body part was prepared from composite and the implementation was performed under laboratory conditions rather than clinic. Furthermore, there has not been a separation between the restoration and adjacent teeth because the composite enabled the holding to the adjacent teeth. At the end of a one-month clinical follow-up of the patient, no breakage or staining was observed.

The fibre-reinforced composite adhesive bridges are conservative and economical treatment option which can be applied easily and in a short time for the absence of a single tooth or short edentulous spaces. Although there are case reports with successful results, further scientific studies are needed in order to eliminate the existing disadvantages.

Only one single case and relatively short follow up duration are the limitations of the present study.

## ACKNOWLEDGMENTS

Poster Presented in the FDI 2013 Congress, Istanbul, Turkey in August 28-31, 2013.

## REFERENCES

1. Kumbuloglu O, Ozdemir N, Aksoy G, User A. A different pontic design for fiber-reinforced composite bridgeworks: a clinical report. *Eur J Dent* 2007;1:50-3.
2. Balkaya M, Pamuk S, Nayır M. Reçine bağlantılı adeziv köprüler. *Quintessence* 2001;1:33-9.
3. Vallittu PK, Sevelius C. Resin-bonded, glass fiber-reinforced composite fixed partial dentures: a clinical study. *J Prosthet Dent* 2000; 84:413-8.
4. Vallittu PK. Survival rates of resin-bonded, glass fiber-reinforced composite fixed partial dentures with a mean follow-up of 42 months: A pilot study. *J Prosthet Dent* 2004; 91:241-6.
5. Vallittu PK. Prosthodontic treatment with a glass fiber-reinforced resin-bonded fixed partial denture: a clinical report. *J Prosthet Dent* 1999; 82:132-5.
6. Rosentiel SF, Land MF, Fujimoto J. Fiber reinforced composite fixed prostheses. In: *Contemporary Fixed Prosthodontics*. Ed. Dolan J. 4th ed. Elsevier Mosby. St. Louis, Miss, 2006: p. 830-40.
7. Karaalioğlu O, Yeşil Duymuş Z. Fiberle güçlendirilmiş kompozitlerin sabit bölümlü protez yapımında kullanımları. *Atatürk Üniv Diş Hek Fak Derg* 2008;18:70-7.
8. Behr M, Rosentritt M, Leibrock A, Schneider-Feyrer S, Handel G. In vitro-study of fracture strength and marginal adaptation of fibre-reinforced adhesive fixed partial inlay dentures. *J Dent* 1999;27:163-8.
9. Garoushi S, Vallittu PK. Fiber-reinforced composites in fixed partial dentures. *Libyan J Med* 2006; 1:1-6.
10. Edelhoff D, Spiekermann H, Yıldırım M. Metal-free inlay-retained fixed partial dentures. *Quintessence Int* 2001;4:269-81.
11. Göehring TN, Peters OA, Lutz F. Marginal adaptation of inlay-retained adhesive fixed partial dentures after mechanical and thermal stress: An in vitro study. *J Prosthet Dent* 2001;86:81-2.
12. Freilich MA, Meiers JC, Duncan JP, Eckrote KA, Goldberg AJ. Clinical evaluation of fiber-reinforced fixed bridges. *J Am Dent Assoc* 2002;133:1524-34.
13. Behr M, Rosentritt M, Lang R, Handel G. Flexural properties of fiber reinforced composite using a vacuum/pressure or a manual adaptation manufacturing process. *J Dent* 2000;28:509-14.
14. Freilich MA, Meiers JC, Duncan JP, Goldberg AJ: *Fiber-Reinforced Composites In Clinical Dentistry*. First Edition, Quintessence Publishing Co Inc, Hong Kong 2000: p. 1-7.
15. Altieri JV, Burstone CJ, Goldberg AJ, Patel AP. Longitudinal Clinical Evaluation of Fiber-reinforced Composite Fixed Partial Dentures: A Pilot Study. *J Prosthet Dent* 1994; 71: 16-22.
16. Güner ÇA, Karacaer Ö. Polietilen Fiber ile Güçlendirilmiş Rezin Tutuculu Köprü Restorasyonu (Olgu Sunumları). *CÜ Diş Hek Fak Derg* 2007;10:26-30.
17. Cekic I, Ergun G, Lassila LV, Vallittu PK. Ceramic-dentin bonding: effect of adhesive systems and light-curing units. *J Adhes Dent* 2007;9:17-23.
18. van Heumen CC, Kreulen CM, Creugers NH. Clinical studies of fiber-reinforced resin-bonded fixed partial dentures: a systematic review. *Eur J Oral Sci* 2009;117:1-6.
19. Burkard H. Ön diş bölgesinde kompozit kullanarak doğrudan köprü yapımı. *QuintessenceTürkçe* 2004; 2:13-25.
20. Gülerüz Gürbulak A, Çölgeçen Ö, Kesim B. Fiberle güçlendirilmiş adeziv köprüler. *Dicle Diş Hekimliği Dergisi* 2009;10:55-62.
21. Vallittu PK. The effect of glass fiber reinforcement on the fracture resistance of a provisional fixed partial denture. *J Prosthet Dent* 1998; 79: 125-30.
22. Unlu N, Belli S. Three-year clinical evaluation of fiber-reinforced composite fixed partial dentures using prefabricated pontics. *J Adhes Dent* 2006;8:183-8.
23. Kusgoz A, Sener Y, Ülker M, Yıldırım S, Koyuturk AE. Fiberle Güçlendirilmiş Kompozit ile Üst Keser Diş Eksikliğinin Restorasyonu. *Türk Diş Hekimliği Derg* 2007;14:78-82.
24. İlday NÖ, Zorba YO. Fiberle Güçlendirilmiş Kompozit Inlay Köprü Uygulamaları. *Türkiye Klinikleri Diş Hekimliği Bilimleri Dergisi* 2009;15: 53-8.
25. Turker SB, Sener ID. Replacement of a maxillary central incisor using a polyethylene fiber reinforced composite resin fixed partial denture. *J Prosthet Dent* 2008; 100:254-8.



26. Van Wijlen P. A modified technique for direct, fibre-reinforced, resin-bonded bridges: Clinical case reports. J Can Dent Assoc 2000; 66: 367-71.
27. Freilich MA, Karmaker AC, Burstone CJ, Goldberg AJ. Development and clinical applications of a light polymerized fiberreinforced composite. J Prosthet Dent 1998; 80: 311-8.
28. Li W, Swain MV, Li Q, Ironside J, Steven GP. Fibre reinforced composite dental bridge. Part I: experimental investigation. Biomaterials 2004; 25:4987-93.
29. Gönülol N, Kalyoncuoglu E, Bulucu B. Fiberle güçlendirilmiş kompozitle adeziv köprü uygulamaları (üç olgu sunumu). Atatürk Üniv Diş Hek Fak Derg 2010; 20: 43-8.
30. Üstün Y, Demirbuğa S, Ülker M. Üst orta keser diş eksikliğinin geçici olarak fiberle güçlendirilmiş adeziv köprü ile restorasyonu: Vaka Raporu. Sağlık Bilimleri Dergisi (Journal of Health Sciences) 2010;19:209-15.
31. Gohring TN, Roos M. Inlay-fixed partial dentures adhesively retained and reinforced by glass fibers: clinical and scanning electron microscopy analysis after five years. Eur J Oral Sci 2005;113:60-9.
32. Monaco C, Ferrari M, Caldari M, Baldissara P, Scotti R. Comparison of 2 bonding systems and survival of fiber-reinforced composite inlay fixed partial dentures. Int J Prosthodont 2006;19:577-85.

#### **Yazışma Adresi**

Prof. Dr. Zeynep YEŞİL DUYMUŞ  
Recep Tayyip Erdogan University,  
Faculty of Dentistry,  
Department of Prosthodontics,  
Rize, Turkey  
Tel: 904642220001  
E Mail: zyesil@hotmail.com

