


PAPER DETAILS

TITLE: REMOVAL OF DISPLACED METALLIC FOREIGN BODIES FROM MAXILLARY SINUS:
TWO CASES

AUTHORS: Sercan KÜÇÜKKURT,Hüseyin Can TÜKEL,Murat ÖZLE

PAGES: 396-399

ORIGINAL PDF URL: <https://dergipark.org.tr/tr/download/article-file/558511>



REMOVAL OF DISPLACED METALLIC FOREIGN BODIES FROM MAXILLARY SINUS: TWO CASES

MAKSİLLER SİNÜSE KAÇAN METALİK YABANCI CİSİMLERİN ÇIKARTILMASI: İKİ VAKA RAPORU

Dr. Öğr. Üyesi Sercan KÜÇÜKKURT* Dr. Öğr. Üyesi Hüseyin Can TÜKEL**
Dr. Dt. Murat ÖZLE***

Makale Kodu/Article code: 2942

Makale Gönderilme tarihi: 21.07.2016

Kabul Tarihi: 14.12.2016

ABSTRACT

Displacement of a foreign body in maxillary sinuses is a common complication in dentistry. However, metallic foreign bodies except dental implants are rarely found in the maxillary sinus. Displaced foreign bodies can cause serious complications and disturb the mucociliary function and this causes potential complications, mainly acute or chronic maxillary sinusitis. This article reported metallic objects penetrating maxillary sinuses of two patients including a membrane fixation screw and a dental burr, as well as their removal with Caldwell-Luc technique. Foreign bodies should be detected and removed on time in order to prevent complications. Otherwise, in advanced stages, the affected area should be reached with Caldwell-Luc operation or endoscopic approaches.

Keywords: Maxillary Sinus, metallic foreign body, Caldwell-Luc

ÖZ

Diş hekimliği uygulamaları esnasında maksiller sinüse yabancı cisim kaçması sık karşılaşılabilen bir komplikasyondur. Diğer yönden dental implantlar dışında kalan metalik yabancı cisimlerin maksiller sinüse kaçması oldukça nadirdir. Yabancı cisimler sinüs içerisinde mukosilyer aktiviteyi etkileyerek akut ya da kronik sinüzit gibi ciddi komplikasyonlara sebep olabilirler. Bu makalede iki farklı hastanın maksiller sinüsüne kaçan membran fiksasyon vidası ve dental frez olmak üzere iki metalik yabancı cisim ve maksiller sinüsten Caldwell-Luc işlemi ile çıkartılmaları rapor edilmiştir. Sinüs içerisine kaçmış yabancı cisimler mümkün olan en kısa zamanda tespit edilip mümkünse sinüse kaçtığı açıklıktan bölgeden uzaklaştırılmalıdır. Aksi halde ilerleyen dönemlerde Caldwell-Luc ya da endoskopik yaklaşımlara ihtiyaç duyulabilir.

Anahtar Kelimeler: Maksiller sinüs, metalik yabancı cisim, Caldwell-Luc

INTRODUCTION

Penetration of foreign bodies such as root of tooth, implant or endodontic materials into maxillary sinus is a complication that may be encountered in dentistry^{1, 2}. Penetration of metallic foreign bodies into maxillary sinus is much rare, except for dental implants^{3, 4}. Penetration of foreign bodies into the area may result from causes such as oroantral fistula occurring after tooth extraction, trauma or iatrogenic causes⁴. These objects may disrupt mucociliary function in the sinus, and this may lead to complications such as acute or chronic maxillary sinusitis. It

It is usually a surgical problem regarding removal of foreign bodies, due to difficulty of access to the area and its proximity to vital anatomical structures^{3, 5}. Nevertheless, in order to avoid complications, foreign bodies should be detected on time and removed. The ideal action is to remove the foreign body as soon as it penetrates to the area⁶. In the following stages, the area should be reached with Caldwell-Luc operation or endoscopic approaches^{5, 7}. This article reports metallic objects penetrating maxillary sinuses of two patients including one membrane fixation screw and a dental burr, as well as their removal.

* İstanbul Aydın Üniversitesi Diş Hekimliği Fakültesi, Ağız, Diş ve Çene Cerrahisi ABD

**Çukurova Üniversitesi Diş Hekimliği Fakültesi, Ağız, Diş ve Çene Cerrahisi ABD

***Gazi Üniversitesi Diş Hekimliği Fakültesi, Ağız, Diş ve Çene Cerrahisi ABD



CASE REPORT

CASE 1

A 36-year-old male patient who consulted our clinic complaining about pain in the right maxillary sinus had a sinus lifting operation approximately 1 year ago which resulted unsuccessfully due to postoperative infection. It was learned that bone grafts were cleared by a second surgical procedure in the area by the same doctor in order to eliminate the infection. The patient stated that his chronic pain also continued after the second surgery with moderate severity, and progressed at intervals in the area. He also stated that he consulted our department without resorting to the same physician, due to the trust issue that arised with the previous physician. The patient had no extraoral signs. There was no fistula or any infection found in the oral region. The oral mucosa in the region appeared normal, except for the scars from surgery. Considering the previous operations the patient had in the area, we decided to take a CBCT to monitor the maxillary sinus in detail. As a result of the radiological examination, presence of a localized membrane fixation screw was detected. On the other hand, in the CBCT image, there was no pathological thickening or infection found in the sinus mucosa (Fig. 1).

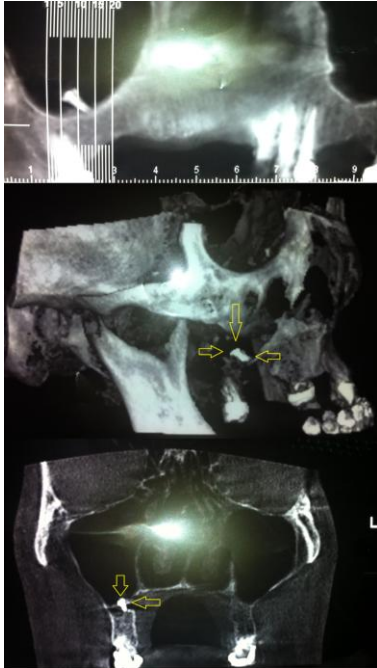


Figure 1. Cone Beam Computerized Tomography images showing membrane fixation screw in the maxillary sinus base

Membrane fixation screw was removed by accessing the area with Caldwell-Luc approach under local anaesthesia (Fig. 2). After the operation, a smooth recovery was seen in the patient. It was also learned from the follow-ups that the patients' pain was relieved and there were no ongoing problems. Considering the healthy structure of the maxillary sinus, it was planned to repeat the sinus lifting operation in the following stages, after the recovery of the schneiderian membrane.

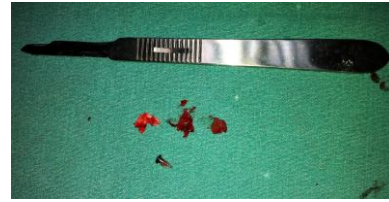

Figure 2. Removed membrane fixation screw and fibrous tissues

CASE 2

A 45-year-old male patient was referred to our clinic by a dentist. It was learned that, approximately 5 weeks ago during the maxillary left second molar tooth extraction of the patient, a dental burr penetrated the area and the patient was directed to our department by his physician. The patient was admitted to our department 5 weeks later because he was living in a remote area and there were no ongoing complaints. No systematic problem or extraoral findings were encountered in the patient. No symptoms were observed in the patient who was informed by his physician regarding the problem experienced. As a result of the radiological examination, presence of a dental drill of approximately 3 cm in size was detected in the left maxillary sinus (Fig. 3).

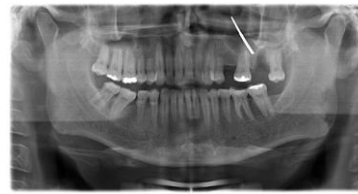

Figure 3. Orthopantomography image showing dental burr in maxillary sinus

There were no infection findings in the area during the intraoral examination, and mucosa appeared normal according to the five-week extraction

socket. Considering the seamless appearance of the extraction socket and the size of dental burr, it was decided to access the area with Caldwell-Luc approach instead of a transalveolar procedure in order to avoid a large sized oroantral intervention in the socket. The area was accessed by lifting the mucoperiosteal flap and forming a window on the sinus front wall, and the body was removed from the region (Fig. 4). The region was primary closed and the recovery period was uneventful. During the 5-month follow-up, no problems were encountered.

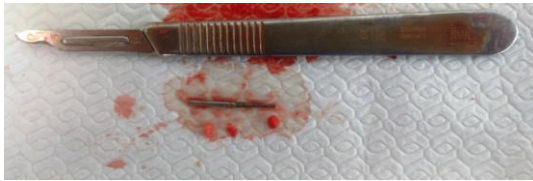


Figure 4. Removed dental burr and fibrous tissues

DISCUSSION

Penetration of tooth roots and pieces into the maxillary sinus is commonly encountered in dentistry. Penetration of metallic foreign bodies into the maxillary sinus is rare. Most commonly reported issue is presence of a tooth root or dental implant within the maxillary sinus^{1, 3, 8}. Migration of metal objects is rare. When dentistry literature is reviewed, penetration of dental drill into the maxillary antrum is reported only in a few cases⁴. Among the most important factors for penetration of foreign bodies into the maxillary sinus during operations are factors such as severe atrophy in the maxillary bone, poor anatomical structure of the area, bone resorptions, changes in the sinus pressure, occlusal forces and the physician's lack of experience. On the other hand, presence of a periapical lesion, maxillary sinusitis, dentigerous cysts and tumours in the area may increase this possibility by leading to additional bone loss.^{3, 5}

Foreign bodies moving into sinus can cause complications such as inflammatory reactions, sinusitis and fungal infections. The problems that are most commonly reported are chronic sinusitis, oroantral fistula formation, rhinolith formation and chronic pain^{4, 9}. Considering the critical anatomic location of the region in future periods, these complications may result in more severe problems such as intracranial abscess and foreign body migration to sphenoid sinus.¹⁰ In the literature, a lead poisoning case was

seen in a child patient, which was caused by penetration of a lead object into maxillary sinus⁹. Foreign bodies can sometimes become symptomatic after a certain period of time following penetration into the sinuses. In this kind of late complications, diagnosis is more difficult in terms of establishing a connection between clinical symptoms present and suspicious foreign bodies¹¹. It was reported that about 5 to 15% of all treated maxillary sinuses are caused by tooth-originated foreign bodies^{3, 12}.

Although it was shown to have a distortion rate of about 25%, orthopantomography is the most commonly used imaging method for verifying the location of dislocated elements in maxillary sinus⁶. In contrast, CBCT imaging method gives the clearest view, as well as the location the smallest and the most unexpected suspected objects in three dimensions¹. In one of our cases, CBCT was used in order to determine the exact location of the membrane fixation screw and to confirm the diagnosis. In the other case, panoramic X-ray was thought to be sufficient, due to the large size of the dental drill.

In removal of the foreign bodies penetrating into the maxillary sinus, there are various known approaches. The classic surgical technique for removal of foreign bodies in the maxillary sinus is Caldwell-Luc operation where the access is acquired from the front wall of the maxillary sinus⁵⁻⁷. In our cases, Caldwell-Luc technique was used. Major advantages of this technique are providing a broad access and field of vision to the surgery area, having experienced clinicians, being an attempt which they often applied, and absence of serious complications^{6, 7}. On the other hand, the literature reports possible complications of Caldwell-Luc procedure as; facial asymmetry, nerve damages, dental pulp devitalization and operation-led oroantral fistula formation.^{7, 13, 14} Another well-known technique is the transalveolar approach at the moment a foreign body penetrates into the sinus. This method is used as a first and urgent step to remove the tooth roots penetrating into the sinus from the socket; however this method can only be applied when the available distance is larger than the size of foreign body⁶. Endoscopic procedures can be used to remove small foreign bodies from paranasal cavities. This method provides sufficient visibility to the surgical site; it has a low morbidity, and it is easily accepted by patients. However, endoscopy is not applicable in all

cases as it requires special training and experience in this area and because of the need for special equipment¹⁵. In our cases, open approach was preferred due to the absence of endoscopic equipment and the size of the body in the dental drill case.

The best way to prevent penetration of a foreign body into the maxillary sinus during the operation is a careful preoperative evaluation process. Iatrogenic cases can arise in various fields of dentistry even during a relatively non-invasive treatment⁶. In such cases, a second unpredictable surgery is needed for removal of the penetrating bodies in the maxillary sinus. Therefore, all cases where dental procedures are applied, patients should be informed previously about the risks of complications and other possibilities. On the other hand, before every surgical procedure, the clinicians should pass appropriate investigations and be evaluated in terms of adequacy of knowledge, experience and surgical skills.

Sercan Küçükkurt: ORCID ID: 0000-0002-4095-957X
Hüseyin Can Tükel: ORCID ID: 0000-0002-6723-0842

REFERENCES

1. Selvi F, Enoz M, Yazgin I, Cakarar S, Keskin C. Do asymptomatic foreign bodies in the maxillary sinus always need to be removed? B-Ent 2008;4:243-7.
2. Özden M, Koyuncu BÖ, Günbay T. Endodontic paste penetration both in maxillary sinus and mandibular canal: Report of a case treated by piezosurgery. J Dent Fac Atatürk Uni. 2015;Supplement: 11; 21-5.
3. Shao L, Qin X, Ma Y. Removal of maxillary sinus metallic foreign body like a hand sewing needle by magnetic iron. Int J Clin Pediatr Dent 2014;7:61-4.
4. Smith JL, 2nd, Emko P. Management of a maxillary sinus foreign body (dental bur). Ear Nose Throat J. 2007;86:677-8.
5. Tilaveridis I, Lazaridou M, Dimitrakopoulos I, Lazaridis N, Charis C. Displacement of three dental implants into the maxillary sinus in two patients. Report of two cases. Oral Maxillofac Surg. 2012;16:311-4.
6. Amorim Kde S, da Silva VT, da Cunha RS, Souto ML, Sao Mateus CR, Souza LM. Removal of an upper third molar from the maxillary sinus. Case Rep Dent. 2Article ID 517149, 5 pages
7. Sohn DS, Jung HS, Kim KH, Song KJ, An HW, Min KH. Removal of displaced foreign body from the maxillary sinus using replaceable bony windows and saline irrigation, followed by suctioning of the foreign body. Implant Dent 2011;20:112-7.
8. Galindo-Moreno P, Padial-Molina M, Avila G, Rios HF, Hernandez-Cortes P, Wang HL. Complications associated with implant migration into the maxillary sinus cavity. Clin Oral Implants Res 2012; 23:1152-60.
9. Brinson GM, Senior BA, Yarbrough WG. Endoscopic management of retained airgun projectiles in the paranasal sinuses. Otolaryngol Head Neck Surg 2004; 130:25-30.
10. Felisati G, Lozza P, Chiapasco M, Borloni R. Endoscopic removal of an unusual foreign body in the sphenoid sinus: an oral implant. Clin Oral Implants Res 2007;18:776-80.
11. Mohanavalli S, David JJ, Gnanam A. Rare foreign bodies in oro-facial regions. Indian J Dent Res 2011;22:713-5.
12. Bodet Agusti E, Viza Puiggros I, Romeu Figuerola C, Martinez Vecina V. [Foreign bodies in maxillary sinus]. Acta Otorrinolaringol Esp. 2009;60:190-3.
13. DeFreitas J, Lucente FE. The Caldwell-Luc procedure: institutional review of 670 cases: 1975-1985. Laryngoscope. 1988;98:1297-300.
14. Murray JP. Complications after treatment of chronic maxillary sinus disease with Caldwell-Luc procedure. Laryngoscope. 1983;93:282-4.
15. Nakamura N, Mitsuyasu T, Ohishi M. Endoscopic removal of a dental implant displaced into the maxillary sinus: technical note. Int J Oral Maxillofac Surg. 2004;33:195-7.

Yazışma Adresi

Sercan KÜÇÜKKURT,
İstanbul Aydın Üniversitesi
Diş Hekimliği Fakültesi
Ağız, Diş ve Çene Cerrahisi ABD,
İSTANBUL – TÜRKİYE
Tlf: 0532 620 55 90,
e-mail: skucukkurt@gmail.com,

