

## PAPER DETAILS

TITLE: Investigation of Regeneration Capacity in Rat Liver After Hepatic Resection

AUTHORS: Samil ÖZTÜRK, Latife Ceyda IRKIN, İlhan ÖZDEMİR

PAGES: 27-32

ORIGINAL PDF URL: <https://dergipark.org.tr/tr/download/article-file/2192725>

## Investigation of Regeneration Capacity in Rat Liver After Hepatic Resection

Şamil ÖZTÜRK<sup>1</sup>, Latife Ceyda İRKİN<sup>2</sup>, İlhan ÖZDEMİR<sup>3</sup>

<sup>1</sup> Çanakkale Onsekiz Mart University-Vocational School of Health Services

<sup>2</sup> Çanakkale Onsekiz Mart University, Çanakkale Faculty of Applied Sciences

<sup>3</sup> Atatürk University- Faculty of Medicine, Department of Gynecology and Obstetrics

Correspondance Author: Şamil ÖZTÜRK

E-mail : samilozturk16@hotmail.com

Received :21.02.2021

Accepted: 05.03.2021

### ABSTRACT

The liver is the largest gland of the body that secretes both endocrine and exocrine secretions and plays a major role in the regulation of metabolic functions. Numerous factors such as drugs, chemicals, accidents, alcohol, surgical procedures can cause damage to the liver tissue. In this study, we aimed to determine the regeneration capacity of liver tissue in order to recover the mass loss after hepatic resection.

In our experiment 21 Wistar albino male rats were used. All experimental groups applied midline incision with laparotomy for resection of liver. At the end of 1 and 7<sup>th</sup> days, liver tissue removed for light microscopic analysis. The rats were divided three groups: Control, group 1: hepatectomy one day after liver resection, group 2: hepatectomy seven days after liver resection.

The tissue of all experimental groups were showed some histopatological changes such as sinuzoidal dilatation, vacuolization in the hepatocytes. These histopathological differentiation was found to be severe in group II compared to other groups. At the end of the 7<sup>th</sup> day, it was observed that the regeneration increased significantly, and the mitotic index value reached almost the maximum level in the second group. It was observed that the mitotic index value gradually decreased in group I and reached values close to the control group.

**Keywords:** Hepatectomy, Regeneration, Liver, Mitosis

### 1. INTRODUCTION

The largest organ of the body is skin. Liver is the largest gland of the body, with both endocrine and exocrine secretion properties, plays a major role in regulating metabolic functions, weighs approximately 1,5 kg and has the largest gland feature in the body [1]. It has a central role in many basic physiological events such as bile acid synthesis and secretion, blood-glucose balance and lipoprotein synthesis, storage of vitamins, biotransformation, detoxification and expression of endogenous and exogenous compounds [2]. Any dysfunction that may occur in the liver affects all systems in the body. The liver is the only organ that has a complex mediator network that can repair itself within a few weeks in cases of significant tissue loss and post-resection, and tissue regeneration with an enormous intercellular interaction after injury [3].

It is one of the most important steps in modern surgery that liver regeneration becomes a common and controllable procedure. For cancer treatment or transplantation, 60-70% of the liver volume can be safely removed to be used as a liver donor graft [4]. Today, in studies conducted with methods such as computed tomography, angiography and scintigraphy, it has been shown that the liver reaches its former size in 3-6 months in adults and less than 3 months in children after liver resection. In the presence of cirrhosis, this period can be up to 9-15 months [5,6]. It has been reported that the human liver can tolerate even resections up to 80-85% [7]. Regeneration occurs even if the resection is less than 10% [8]. It has been shown that regeneration of the liver tissue starts from the first day after partial hepatectomy and DNA synthesis reaches its maximum level in the first 24-48 hours [9].

It has been observed that hepatocyte proliferation is increased in cases such as surgical removal of a part of the liver lobes or hepatocyte damage from viruses or chemicals. However, studies have shown that following liver resection, the regenerative activity is increased as a result of giving more stimuli.

In our experimental hepatectomy model, we aimed to show liver regeneration on the 1<sup>st</sup> and 7<sup>th</sup> days after resection and contribute to the emergence of the most appropriate resection model as a surgical model, without giving liver drugs or alternative chemicals that stimulate regeneration.

## 2. MATERIAL AND METHOD

In our study, 21 adult male Wistar albino rats produced in Trakya University Experimental Animal Research Unit, weighing 250-300 g and having the same biological and physiological characteristics were used. During the experimental period, all our specimens were fed with pelleted feeds [Purina] containing 21% crude protein under optimum laboratory conditions [ $22 \pm 1^{\circ}\text{C}$ , 12 hours light/dark cycle]. Cage maintenance was done regularly. A total of 3 groups were formed in the experiment.

Group I (n=7): (Control group) No treatment was applied to the rats in this group. Group II (n=7): The group whose liver tissues were taken for examination 1 day after liver resection. Group III (n=7): The group whose liver tissues were taken for examination 7 days after liver resection.

### 2.1. Hepatic Resection Method

General anesthesia with ketamine/xylazine was applied to the rats. Before laparotomy in order to prevent bacterial translocation intramuscularly at 25 mg/kg of cefazolin vial (MN Pharmaceutical Inc., Istanbul, Turkey) were performed [10]. Laparotomy was performed with an upper midline incision. The left lateral and median lobe pedicles of the liver were tied with 4/0 silk and 70% hepatectomy was performed as described by Higgins and Anderson [11].

### 2.2. Histopathological Evaluation

Tissues were taken for histological follow-up for histopathological evaluation. After fixing in Bouin's solution for 12 hours the washing process was started. The tissues were washed in Ethyl alcohol (%70, 90, 96, 100) series and the dehydration process was initiated. After the dehydration step, tissues were cleared in xylene. Tissues were kept in soft paraffin overnight before embedding. The next day, liver

tissues were removed from soft paraffin (50<sup>o</sup>C) and kept in liquid hard paraffin (58<sup>o</sup>C) for 1 hour and blocked. 4-5  $\mu\text{m}$  thick sections were taken from these blocks. The sections were stained with Hematoxylin-Eosin (H&E) to observed the histological changes in the liver. Microphotographs were taken with a light microscope [Olympus CX31-Japan]. Semiquantitative evaluation was performed by taking 10 sections from different subjects from each group.

### 2.3. Mitotic Index

H&E stained sections were examined for mitotic index. Mitotic index; The number of hepatocytes and total hepatocytes showing mitotic activity at 30 high-power fields was calculated and expressed as their ratio per 1000 cells [12]. All data are expressed as mean [ $\pm$ ] standard deviation (SD). The differences between the groups were evaluated by Kruskal-Wallis analysis of variance. Mann-Whitney U test was used for comparisons between groups with significant differences. The difference was considered statistically significant in the results with  $p < 0.05$ .

## 3. RESULTS

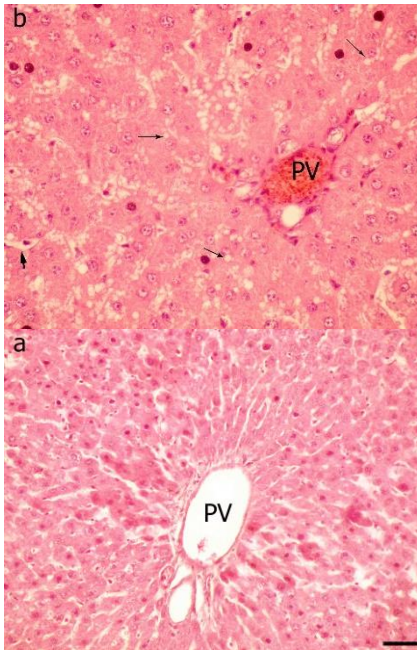
### 3.1. Light Microscopic Findings

The control samples showed normal histology. It was observed that hepatocytes, which are liver parenchymal cells, were placed regularly around the central veins to form hepatocyte cords (Figure 1a). Hepatocyte vacuolization and sinusoidal dilatation counts were determined semi-quantitatively in all experimental groups. In group II and III, mitosis at various stages was common and it was showed in the vacuolization and sinusoidal dilatation in hepatocytes. In group II, hepatocyte vacuolization and sinusoidal dilatation were severe (Figure 1b). In sections belonging to the in group III, it was observed that hepatocyte vacuolization were moderate and sinusoidal dilatation were mild (Figure 2).

### 3.2. Mitotic Index Results

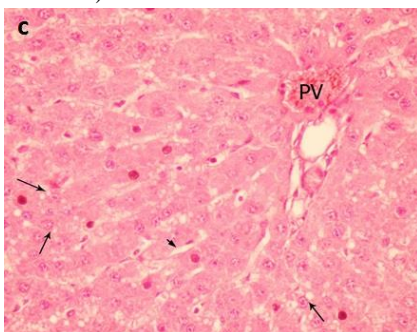
When the sections belonging to all groups were evaluated generally, it was observed that the classical liver lobule structure was preserved. The statistically significant difference between the groups

was evaluated according to  $p < 0.05$ . When the control group and experimental groups were compared, a statistically significant difference in mitotic index was observed. When the Group II was compared to group I, a statistically significant difference was found at the  $p < 0.00001$ . When the group III was compared to group I, a statistically significant difference was found  $p < 0.0001$  (Figure 3).



**Figure 1. a.** H&E staining of the control group, normal histological appearance of the liver, X40.

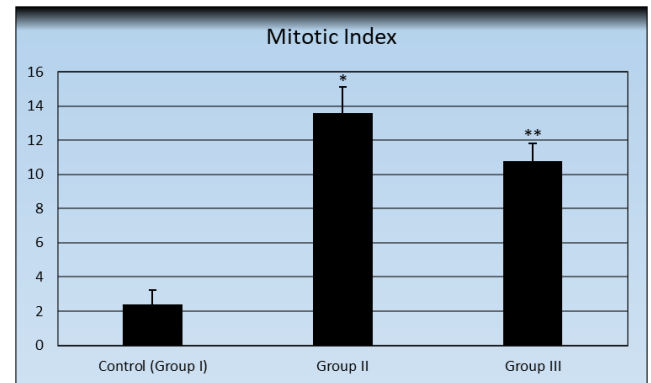
**b.** H&E staining of the liver section 1 day after resection. Intense vacuolization is seen around the portal areas, X40 (PV: Portal vein, long arrow: hepatocyte vacuolization, short arrow: sinusoidal dilatation).



**Figure 2.** H&E staining of the liver section 7 days after resection. Hepatocyte vacuolization is seen around the portal areas, X40 (PV: Portal vein, long arrow: hepatocyte vacuolization, short arrow: sinusoidal dilatation).

**Table 1.** Semi-quantitative evaluation of hepatocyte vacuolization and sinusoidal dilatation in control and study groups.

Groups	Group I [control]	Group II [1 <sup>st</sup> day]	Group III [7 <sup>th</sup> day]
Hepatocyte vacuolization	-	++++	++
Sinusoidal dilatation	-	+++	+



**Figure 3.** Mitotic index values of control and study groups. (\* $p < 0.00001$  with the control group, \*\* $p < 0.0001$  with the control group, a statistically significant difference was determined)

#### 4. DISCUSSION

The liver exhibits a distinct feature from other organs with its regeneration capacity. Under today's conditions, the liver is still an organ that has important and vital functions that are not fully resolved, including the mystery of many basic mechanisms such as biotransformation, regulation of metabolic functions, and immunological events, and that concern all systems of the human body [13,14]. Most studies on liver regeneration have been studied on the pre-existing damaged liver in experimental animals, or liver damage has been caused by using chemicals or a partial hepatectomy.

The existence of the ability to replenish the tissue mass after the loss or damage of a part of an organ has been defined as regeneration [15]. Regeneration is a complex process in which cytokines, hormones, transcription factors and oxidative stress products play a role [3]. Studies have shown that the liver has the ability to repair itself in significant tissue losses, thanks to intercellular interaction and a complex mediator network [16,17]. In most of the

studies on liver regeneration, pre-existing damaged liver in experimental animals was studied or liver damage was caused by using chemicals or by performing partial hepatectomy [18]. Palmes and Spiegel [18] explained the model used in partial hepatectomy studies by stating the ratio of each liver lobe to the total mass of all liver lobes in rats. According to the total liver mass, the right lobe contains 38%, the left lobe 30%, the tail lobe 8% and the two-piece quadrat [quadrilateral] lobe contains 10% of the mass. It has been stated that the most suitable model for partial hepatectomy studies in rats is resection of 68-70% of the liver [16].

In liver regeneration, it has been reported that hepatocyte proliferation begins in the periportal zone and reaches the pericentral zone within 36-48 hours [19,20]. In another study, it was stated that mitosis reached the highest level at the 32nd hour after partial hepatectomy [20,21]. Groups II and III in which we performed partial hepatectomy, the abundance of hepatocytes showing various stages of mitosis around the vena centralis in the liver sections of the group is consistent with the results stated in studies on liver regeneration. Determination of mitotic index has been used frequently in studies on liver regeneration and played an important role in interpretation of regeneration [22].

In studies on liver regeneration, the determination of the mitotic index and more importantly the PCNA index has been used frequently and played an important role in the interpretation of regeneration [23-27]. Hou et al. [16] Mitotic index data were also used to determine the effects of an organic compound named FR167653 on liver regeneration in rats who underwent partial hepatectomy. In their study, they determined that the mitotic index that they determined simultaneously from the liver sections of the control group rats they underwent partial hepatectomy was higher than the PCNA index. The mitotic index data we put forward in our study are in parallel with each other and with the results of the research. In the findings of our study, mitotic index results were found to be higher in the second group and the third group compared to the control group. Both mitotic index was found to be

higher on the first day compared to the 7<sup>th</sup> day. In the study where we applied a partial hepatectomy model, the mitotic index value we determined in the liver tissue of the second group was found to be higher than the mitotic index values of the first and third groups. We believe that this study, which aims to demonstrate liver regeneration after hepatic resection and uses an experimental model of partial hepatectomy, will shed light on future research.

## 5. CONCLUSION

In the study we planned to examine the histological examination of liver regeneration after hepatic resection, we observed that regeneration due to the relative weight of the liver increased significantly over time. In histopathological examination under light microscopy, it was observed that vacuolization of hepatocytes and dilatation in sinusoids first occurred after partial hepatectomy, and mitotic activity increased in the following days, which is an indicator of increased regeneration. Vacuolization, sinusoidal dilatation and mitosis activity were the highest in the group II. In the group III, In Group III, these values were observed to be close to the group I. We believe that the data obtained from our study will contribute to the literature.

## ÇIKAR ÇATIŞMASI BEYANI

Yazarlar tarafından herhangi bir potansiyel çıkar çatışması bildirilmemiştir.

## ARAŞTIRMA VE YAYIN ETİĞİ BEYANI

Bu çalışmanın yazım sürecinde uluslararası bilimsel, etik ve atıf kurallarına uyulmuş ve toplanan veriler üzerinde herhangi bir tahrifat yapılmamıştır. Environmental Toxicology and Ecology Dergisi ve derginin editörleri etik ihlallerden sorumlu değildir. Tüm sorumluluk sorumlu yazara aittir ve bu çalışma ETOXEC dışında herhangi bir akademik yayın ortamında değerlendirilmemiştir.



## REFERENCES

- [1] A. Aktümsek, 'Anatomi ve Fizyoloji İnsan Biyolojisi,' 3th. Ankara: Nobel Yayınları, 2006, pp.366-7.
- [2] T.E. Andreoli, 'Liver,' In: M.B. Fallon, B.M. McGuire, G.A. Abrams, M.R. Arguedas Eds. Cecil Essentials of Medicine. 5th Ed. Philadelphia, USA: WB Saunders Company, 2001, pp.365-98.
- [3] R. Adam, P. Bhangui, E. Vibert, D. Azoulay, G. Pelletier, J.C. Duclos-Vallée, D. Samuel, C. Guettier and D. Castaing, 'Resection or transplantation for early hepatocellular carcinoma in a cirrhotic liver: does size define the best oncological strategy?,' Ann. Surg. vol. 256, pp. 883-91, Dec, 2012, doi: 10.1097/SLA.0b013e318273bad0.
- [4] E.A. Pomfret, J.J. Pomposelli, F.D. Gordon, N. Erbay, L. Lyn Price and W.D. Lewis, 'Liver regeneration and surgical outcome in donors of right-lobe liver grafts,' Transplantation. vol 76. pp. 5-10, jul, 2003, doi: 10.1097/01.TP.0000079064.08263.8E.
- [5] Z.G. Ren, J.D. Zhao, K. Gu, J. Wang and G.L. Jiang, 'Hepatic proliferation after partial liver irradiation in Sprague-Dawley rats,' Mol. Biol. Rep. Vol. 39, pp. 3829-36, Apr, 2012, doi: 10.1007/s11033-011-1161-z.
- [6] S. Perek, S. Kapan, Eds. U. Değerli, Y. Bozfakıoğlu, 'Cerrahi Gastroenteroloji'. 5th ed. İstanbul: Nobel Tıp Kitabevleri, pp. 194-208, 2000.
- [7] Y. Umeda, H. Iwagaki, M. Ozaki, T. Ogino, T. Iwamoto, R. Yoshida, S. Shinoura, H. Matsuda, H. Sadamori, N. Tanaka and T. Yagi, 'Refractory response to growth factors impairs liver regeneration after hepatectomy in patients with viral hepatitis,' Hepatogastroenterology. Vol. 56, pp. 971-7, Jul-Aug, 2009, PMID: 19760923
- [8] G.K. Michalopoulos and M.C. DeFrances, 'Liver regeneration'. Science. Vol. 296, pp. 60-6, 1996.
- [9] D.R. Labrecque, G. Steele, S. Fogerty, M. Wilson and J. Barton, 'Purification and physical-chemical characterisation of hepatic stimulator substance,' Hepatol. Vol. 7, pp. 100-6, 1987.
- [10] M.J. Xu, D. Feng, H. Wu, H. Wang, Y. Chan, J. Kolls, N. Borregaard, B. Porse, T. Berger, T.W. Mak, J.B. Cowland, X. Kong and B. Gao, 'Liver is the major source of elevated serum lipocalin-2 levels after bacterial infection or partial hepatectomy: a critical role for IL-6/STAT3,' Hepatology. Vol. 61, pp. 692-702, Feb; 2015, doi: 10.1002/hep.27447.
- [11] A. Akcan, C. Kucuk, E. Ok, O. Canoz, S. Muhtaroglu, N. Yilmaz and Z. Yilmaz, 'The effect of amrinone on liver regeneration in experimental hepatic resection model,' J. Surg. Res. Vol. 130, pp. 66-72, Jan; 2006, doi: 10.1016/j.jss.2005.07.020.
- [12] M. Selzner and P.A. Clavien, 'Failure of regeneration of the steatotic rat liver: Disruption at two different levels in the regeneration pathway,' Hepatology. Vol. 31, pp. 35-42, 2000.
- [13] R.G. Kilbourn, D.L. Traber and C. Szabo, 'Nitric oxide and shock'. Dis. Mon. Vol. 47, pp. 277-348, 1997.
- [14] Z. Hou, K. Yanaga, Y. Kamohara, S. Eguchi, R. Tsutsumi and J. Furu, 'A new suppressive agent against interleukin-1b and tumor necrosis factor- $\alpha$  enhances liver regeneration after partial hepatectomy in rats,' Hepatology. Research. Vol. 26, pp. 40-46, 2003.
- [15] N. Fausto, 'Liver regeneration,' J. Hepatol. Vol. 32, pp. 19-31, 2000.
- [16] A.K. Rohlfing, K. Trescher, J. Hähnel, C. Müller and J.P. Hildebrandt, 'Partial hepatectomy in rats results in immediate down-regulation of p27Kip1 in residual liver tissue by transcriptional and post-translational processes,' Front. Physiol. Vol. 13, pp. 4-139, Jun, 2013, doi: 10.3389/fphys.2013.00139.
- [17] R. Veteläinen, A.K. van Vliet and T.M. van, 'Gulik. Severe steatosis increases hepatocellular injury and impairs liver regeneration in a rat model of partial hepatectomy' Ann. Surg. vol. 245, pp. 44-50, 2007.
- [18] D. Palmes and H.U. Spiegel, 'Animal models of liver regeneration,' Biomaterials. Vol. 25, pp. 1601-11, 2004.
- [19] A. Mimuro, T. Aoki, A. Tsuchida, T. Miyashita, Y. Koyanag and S. Enosawa, 'Effect of ethanolamine on liver regeneration after 90% hepatectomy in rats,' Transplant. Proc. vol. 234, pp. 2664-7, 2002.
- [20] T.X. Tang, T. Hashimoto, L.Y. Chao, K. Itoh and T. Manabe, 'Effects of partial pancreatectomy on liver

regeneration in rats' J. Surg. Res. Vol. 72, pp. 8-14, 1997.

[21] E.B. Fernandez, I.A. Sesterhenn, W.F. McCarthy, F.K. Mostofi and J.W. Moul, 'Proliferating cell nuclear antigen expression to predict occult disease in clinical stage I nonseminomatous testicular germ cell tumors,' J. Urol. Vol. 152, pp. 1133-8, 1994.

[22] N. Ekici, S. Muhtaroglu, A. Bedirli, 'Administration of Ginkgo biloba extract (egb761) alone and in combination with fk506 promotes liver regeneration in a rat model of partial hepatectomy,' Balkan. Med. J. 35(2), pp.174-180, 2018.

[23] D. Mangnall, N.C. Bird and A.W. Majeed, 'The molecular physiology of liver regeneration following partial hepatectomy,' Liver. Int. Vol. 23, pp. 124-138, 2003.

[24] N. Assy and G.Y. Minuk, 'Liver regeneration: methods for monitoring and their applications,' J. Hepatol. Vol. 26, pp. 945-52, 1997.

[25] D. Mangnall, N.C. Bird and A.W. Majeed, 'The molecular physiology of liver regeneration following partial hepatectomy,' Liver. Int. Vol. 23, pp. 124-138, 2003.

[26] C. Picard, L. Lambotte, P. Starkel, C. Sempoux, A. Saliez and V.V.D. Berge, 'Steatosis is not sufficient to cause an impaired regenerative response after partial hepatectomy in rats,' J. Hepatol. Vol. 32, pp. 645-52, 2002.

[27] O. Castro-e-Silva Jr, S. Zucoloto, F.S. Ramalho, L.N.Z. Ramalho and J.M.C. Reis, 'Antiproliferative Activity of copaifera duckei oleoresin on liver regeneration in rats,' Phytother. Res. Vol. 18, pp. 92-94, 2004.