

PAPER DETAILS

TITLE: Frequency of Roux Stasis Syndrome is Different in Uncut or Conventional Roux-Y Procedures

AUTHORS: Semra Tutcu Sahin, Semra Salimoglu, Mustafa Tireli

PAGES: 715-720

ORIGINAL PDF URL: <https://dergipark.org.tr/tr/download/article-file/4120577>



ORİJİNAL MAKALE / ORIGINAL ARTICLE

Balıkesir Sağlık Bilimleri Dergisi / BAUN Sağ Bil Derg
Balıkesir Health Sciences Journal / BAUN Health Sci J
ISSN: 2146-9601- e ISSN: 2147-2238
Doi: <https://doi.org/10.53424/balikesirsbd.1527770>



Frequency of Roux Stasis Syndrome is Different in Uncut or Conventional Roux-Y Procedures

Semra TUTCU SAHIN ¹, Semra SALIMOGLU ², Mustafa TIRELI ²

¹ Celal Bayar University, Faculty of Medicine, Department of General Surgery

² University of Health Sciences, Tepecik Research and Training Hospital, Department of General Surgery

Geliş Tarihi / Received: 05.09.2024, Kabul Tarihi / Accepted: 09.12.2024

ABSTRACT

Objective: One of the main problems of conventional Roux-Y (C-RY) procedures is Roux stasis syndrome. To avoid this problem, an alternative technique called Uncut Roux-Y (U-RY) has been proposed in the literature. The aim of this article is to present the results of our patients who underwent C-RY and U-RY and to compare the incidence of Roux stasis between these two methods. **Materials and Methods:** The medical records of all patients who underwent C-RY and U-RY procedures at Manisa Celal Bayar University Department of General Surgery and Tepecik Teaching Hospital General Surgery Clinic between January 1989 and January 2018 were retrospectively reviewed. The incidence of Roux stasis in both procedures was investigated. **Results:** A total of 64 C-RY and 42 U-RY anastomoses were performed in 106 patients. Of the 64 C-RYs, 17 were performed for gastric cancer, 17 for bilienteric diversion, 25 for alkaline reflux gastritis and 5 for pancreatic pseudocyst. Of the 42 U-RYs, 18 were performed for gastric cancer, 18 for biliaryenteric diversion, 4 for alkaline reflux gastritis and 2 for pancreatic pseudocyst. A total of 38 complications occurred in 28 patients in the postoperative period. Roux stasis developed in 7 patients (14.1%) who underwent C-RY and 2 patients (4.8%) who underwent U-RY. There was no statistically significant difference in the development of Roux stasis between these two methods ($p>0.05$). **Conclusion:** The incidence of Roux stasis is lower in U-RY anastomosis compared to C-RY anastomosis. U-RY operation may be an effective method to prevent both duodenogastric reflux and roux stasis, especially in patients undergoing gastroenterostomy via omega loop. In addition, surgically, the U-RY technique is easier to perform than the C-RY technique. Therefore, U-RY operation is one of the techniques that can be preferred in laparoscopic or open gastroesophageal and biliary surgery.

Keywords: Roux-Y Stasis Syndrome, Uncut Roux-Y Limb, Conventional Roux-Y Ans.

Roux Stasis Sendromunun Sıklığı Kesilmemiş veya Geleneksel Roux-Y Prosedürlerinde Farklıdır

ÖZ

Amaç: Konvansiyonel Roux-Y (C-RY) prosedürlerinin ana sorunlarından biri Roux staz sendromudur. Bu sorunu önlemek için literatürde Uncut Roux-Y (U-RY) olarak adlandırılan alternatif bir teknik önerilmiştir. Bu makalenin amacı C-RY ve U-RY yapılan hastalarımızın sonuçlarını sunmak ve bu iki yöntem arasındaki Roux staz görülme oranını karşılaştırmaktır. **Gereç ve Yöntem:** Ocak 1989 ile Ocak 2018 tarihleri arasında Manisa Celal Bayar Üniversitesi Genel Cerrahi Anabilim Dalı ve Tepecik Eğitim Hastanesi Genel Cerrahi Kliniği'nde C-RY ve U-RY prosedürleri uygulanan tüm hastaların tıbbi kayıtları retrospektif olarak incelendi. Her iki prosedürde Roux stazı görülme oranı araştırıldı. **Bulgular:** Toplam 106 hastanın 64'üne C-RY, 42'sine U-RY anastomozu uygulandı. 64 C-RY'nin 17'si mide kanseri, 17'si biliyenterik diversiyon, 25'i alkalen reflü gastrit ve 5'i pankreatik psödokist nedeniyle yapıldı. 42 U-RY'nin 18'i mide kanseri, 18'i biliyenterik diversiyon, 4'ü alkalen reflü gastrit ve 2'si pankreatik psödokist nedeniyle yapıldı. 28 hastada ameliyat sonrası dönemde total 38 komplikasyon meydana geldi. C-RY yapılan 7 hastada (%14,1) ve U-RY yapılan 2 hastada (%4,8) Roux stazı gelişti. Bu iki yöntem arasında Roux stazı gelişmesi açısından istatistiksel olarak anlamlı fark saptanmadı. ($p>0.05$) **Sonuç:** Roux stazı görülme oranı, U-RY anastomozunda C-RY anastomozuna göre daha düşüktür. U-RY operasyonu, özellikle omega loop üzerinden gastroenterostomi yapılan hastalarda hem duodenogastrik reflüyü hem de roux stazını önlemede etkili bir yöntem olabilir. Ayrıca cerrahi açıdan U-RY tekniğinin uygulaması C-RY tekniğine göre daha kolaydır. Bu nedenle U-RY operasyonu, laparoskopik veya açık gastroözofageal ve biliyer cerrahide tercih edilebilecek tekniklerden biridir.

Anahtar Kelimeler: Roux-Y Staz Sendromu, Kesilmemiş Roux-Y Prosedürü, Konvansiyonel Roux-Y Ans.

Sorumlu Yazar / Corresponding Author: Semra TUTCU SAHIN, Celal Bayar University, Faculty of Medicine, Department of General Surgery, Manisa, Türkiye.

E-mail: semratutcu@gmail.com

Bu makaleye atıf yapmak için / Cite this article: Tutcu Sahin, S., Salımoğlu, S., & Tireli, M. (2024). Frequency of roux stasis syndrome is different in uncut or conventional roux-y procedures. *BAUN Health Sci J*, 13(3), 715-720. <https://doi.org/10.53424/balikesirsbd.1527770>



BAUN Health Sci J, OPEN ACCESS <https://dergipark.org.tr/tr/pub/balikesirsbd>

This work is licensed under a Creative Commons Attribution-NonCommercial 4.0 International License

INTRODUCTION

The conventional Roux-Y (C-RY) technique has been used in esophageal, gastric and hepatopancreatobiliary operations for many years. The main advantage of the Roux-Y operation is that it prevents bile and pancreatic secretion from reaching the gastric and esophageal mucosa. One of the main problems of this procedure is Roux stasis syndrome. This problem is seen in 20-40% after gastroesophageal surgery (Britton et al., 2005; Gustavsson et al., 1988; Hinder et al., 1988; Noh, 2000) and in 5-10% after biliary enteric diversion operations. (AbdelRafee et al., 2015; Bismuth et al., 1978; Stefanini et al., 1975). Therefore, an alternative technique called Uncut Roux-Y (U-RY) was proposed by Van Stiegman and Goff in 1988 (Van Stiegmann and Goff, 1988). In recent years, the U-RY technique has been used more frequently in laparoscopic gastric and esophageal surgeries compared to the C-RY technique (Park et al., 2018; Sun et al., 2018).

The aim of this article is to present the results of a total of 106 patients who underwent C-RY and U-RY in upper gastrointestinal and pancreatobiliary system surgery together with their surgical procedures and to compare the incidence of Roux stasis in these two methods.

MATERIALS AND METHODS

The medical records of all patients who underwent C-RY and U-RY between January 1989 and January 2018 at the Department of General Surgery of Manisa Celal Bayar University and the General Surgery Clinic of Tepecik Teaching Hospital were retrospectively analyzed. Age, gender, preoperative diagnosis, surgical procedure, morbidity and mortality were recorded. Patients were divided into 2 groups as U-RY (n=42) and C-RY (n=64)

according to the type of anastomosis performed. The data obtained were transferred to IBM SPSS Statistics 21 program. The incidence of Roux stasis in both groups was compared by chi-square test. The limit of statistical significance was accepted as $p < 0.05$.

Surgical method

For the U-RY procedure, the jejunum lumen was first occluded 30-35 cm distal to the ligament of Treitz. For this procedure, four or five seromuscular sutures (with 000 polypropylene or silk) were placed circularly on the jejunal wall and the suture material was tightly tied. A bilioenteric, gastrojejunal or esophagojejunal anastomosis was created at a site 5-7 cm distal to this jejunal occlusion site, either end to end or side by side. Approximately 25-30 cm distal to this anastomosis, a side-to-side jejunojejunostomy was performed to divert duodenal fluid (Figure 1-A). The 30-35 cm long jejunal segment lying distal to the ligament of Treitz, when passed anterior to the transverse colon, can easily access an anastomosis at the level of the porta hepatis or distal esophagus.

For the C-RY procedure, the jejunum was first cut 20-25 cm distal to the ligament of Treitz and the distal end was closed with 000 silk or polypropylene material. A bilioenteric, gastrojejunal or esophagojejunal anastomosis was created side by side or end to end 3-4 cm distal to the jejunal closure site. An end-to-side jejunojejunostomy was performed approximately 25-35 cm distal to this anastomosis (Figure 1-B).

Ethical considerations

Approval for this study was obtained from the Ethics Committee of Manisa Celal Bayar University Faculty of Medicine.

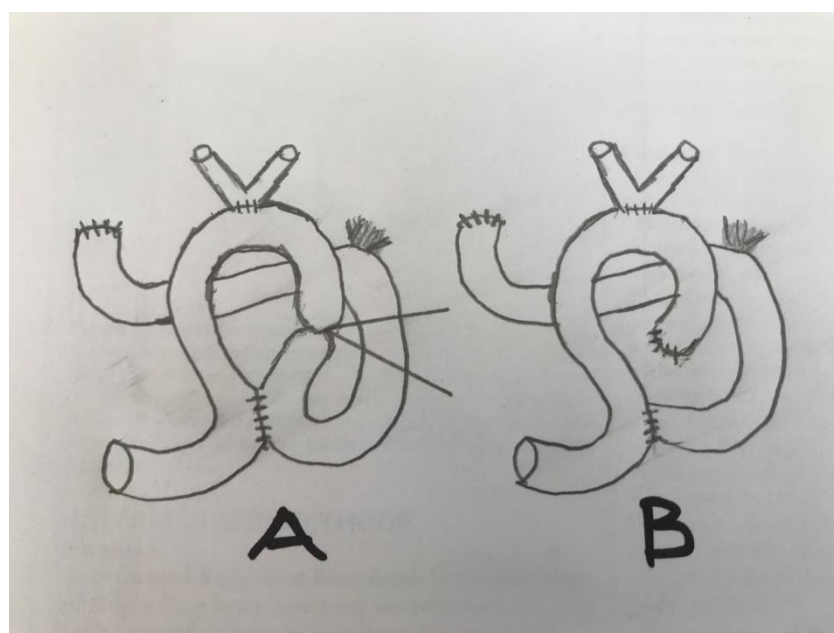


Figure 1. Gastrojejunostomy, A: Uncut Roux – Y, B : Conventional Roux-Y.

RESULTS

In Of the total 106 patients, 64 (33 females and 31 males) underwent C-RY and 42 (23 females and 19 males) underwent U-RY procedures. The mean age of the patients was 57.1 years (range: 22-86).

Of our 64 patients, 17 underwent C-RY for gastric tumor, 25 for alkaline reflux gastritis, 17 for bilienteric diversion and 5 for pancreatic pseudocyst. Of our 42 patients, 18 underwent U-RY for gastric tumor, 18 for bilienteric diversion, 4 for alkaline reflux gastritis and 2 for pancreatic pseudocyst.

Of the gastric malignancies, 20 were localized in the gastric corpus (ten U-RY and ten C-RY) and 15 in the cardia (eight U-RY and seven C-RY). There were 18 patients who underwent total gastrectomy (twelve U-RY and six C-RY), 12 patients who underwent near-total gastrectomy (four U-RY and eight C-RY), and 5 patients who underwent distal esophagectomy and total gastrectomy (two U-RY and three C-RY). The locations of gastric malignancies and surgical treatments are shown in the table (Table 1).

Of the patients who underwent biliaryenteric diversion, 14 were malignant and 21 were benign. Of the malignant patients, 6 were gallbladder carcinoma and 8 were cholangiocarcinoma. Hepaticojejunostomy (one U-RY and two C-RY) was performed in 3 patients with gallbladder carcinoma after cholecystectomy and choledochal excision. In the other 3 irresectable gallbladder carcinomas, only biliary enteric bypass procedures (two U-RY and one C-RY) were performed to divert bile. 8 of our patients had cholangiocarcinoma. Tumor and extra hepatic biliary tree resection and biliary enteric diversion (three U-RY and one C-RY) were performed in 4 of them. The other 4 irresectable cholangiocarcinoma patients underwent only biliary enteric bypass procedure (one U-RY and three C-RY). 11 of the benign patients had late postcholecystectomic bile duct stricture. In 5 patients, the strictural segment of the bile duct was resected (two U-RY and three C-RY), while 6 patients with bile duct stricture underwent only proximal biliary enteric bypass procedures (three U-RY and three C-RY). 6 patients had intraoperative bile duct injury and underwent bile duct excision and hepaticojejunostomy (four U-RY and two C-RY). In 2 cases, there was obstruction at choledochoduodenostomy and bypass procedures were performed (one U-RY and one C-RY). In the other 2 cases, excision of the cysts and biliary tree and hepaticojejunostomy (one U-RY and one C-RY) were performed due to choledochal cysts. The diagnoses and surgical treatments of the patients who underwent bilienteric diversion are shown in the table (Table 2).

In our series, there were 29 patients with alkaline reflux gastritis (ARG), 25 patients underwent C-RY and 4 patients underwent U-RY procedure. The first operations of 25 C-RY patients with ARG were 13 distal gastrectomy-gastrojejunostomy, 8 truncal vagotomy-

gastrojejunostomy and 4 truncal vagotomy-pyloroplasty. Of the 4 ARG patients whose first operation was U-RY, 2 were truncal vagotomy gastrojejunostomy and 2 were truncal vagotomy pyloroplasty. 7 patients had pancreatic pseudocysts and underwent cystojejunostomy (two U-RY and five C-RY).

Mortality occurred in 4 patients (3.8 percent) in the postoperative period (three U-RY and one C-RY). Two of our patients with mortality had gastric cancer, the other two had gallbladder and biliary tree cancer. The causes of death were liver failure in two biliary tree patients and one pneumonia and one peritonitis due to duodenal stump failure in two gastric cancer patients.

A total of 38 complications occurred in 28 patients in the postoperative period. Enterocutaneous fistula developed in 4 patients (3.8%). The localization of the fistula was biliary anastomosis in 2 patients, esophagojejunostomy anastomosis in 1 patient and duodenal stump in 1 patient. All fistulas were treated conservatively.

11 patients showed signs of Roux stasis. C-RY was performed in 9 patients (14.1%) and U-RY in 2 patients (4.8%). The diagnosis of Roux stasis was made with clinical findings in all patients. Roux stasis syndrome was seen in 5 patients with alkaline reflux gastritis, 4 patients with gastric cancer and 2 patients after bilienteric diversion surgery. Patients with Roux stasis syndrome were treated conservatively (cessation of oral feeding, nasogastric decompression, parenteral fluids and electrolytes, and oral erythromycin suspension). The duration of this treatment ranged from two to seven days. The stasis episode recurred intermittently during a four-month period in patients who underwent gastric surgery. These patients were also treated conservatively. Endoscopic examination of these seven stasis patients with U-RY or C-RY did not reveal any anastomotic stenosis or jejunal ulcer. Two bilienteric diversion patients with C-RY anastomosis developed cholangitis. Magnetic resonance cholangiopancreatography (MRCP) showed no anastomotic stenosis or gallstones in the patients with cholangitis. These cholangitis crises recurred four times within three months and were treated conservatively. None of our patients with Roux stasis required surgical intervention. Chi square test was applied to the data transferred to the SPSS Statistics 21 program to compare the complication of Roux stasis in terms of two different anastomosis techniques. (The statistical significance limit was accepted as $p < 0.05$.) The difference between the groups in terms of the development of Roux stasis was not statistically significant ($p = 0.19$).

In addition, wound infection developed in nine patients, wound dryness in three patients, and pulmonary problems in seven patients and these were treated conservatively. The distribution of complications according to the technique applied is shown in the table (Table 3).

Table 1. Gastroesophageal tumors, localization and surgical treatment.

Localization of Tumor	Uncut Roux-Y	Classic Roux-Y
Gastric corpus cancer	8	10
Gastric cardia cancer	8	7
Gastric corpus carcinoid	1	-
Gastric corpus GIST	1	-
Total gastrectomy	12	6
Nearly-total gastrectomy	4	8
Distal esophagectomy and total gastrectomy	2	3

Table 2. Diagnosis and surgical technique in biliaryenteric diversion.

Diagnosis and operation	Uncut Roux-Y	Classic Roux-Y
Gallbladder Cancer (n=6)		
Resection	1	2
By-Pass	2	1
Cholangiocancer (n=8)		
Resection	3	1
By-Pass	1	3
Bileduct Stricture (n=11)		
Resection	2	3
By-Pass	3	3
Operative Bileduct Injuries (n=6)		
Resection	4	2
Occlusion - Choledochoduodenostomy (n=2)		
By-Pass	1	1
Choledochal cysts (n=2)		
Resection	1	1

Table 3. Postoperative complications.

Complications	Uncut Roux-Y	Classic Roux-Y
Postoperative death	3	1
Roux-stasis syndrome	2	9
Enterocutaneous fistulas	2	2
Wound infection	4	5
Wound dehiscence	1	2
Pulmonary problems	4	3

DISCUSSION

The most important problem of the C-RY technique is the Roux-Y stasis syndrome (Britton et al, 2005; Gustavsson et al, 1988; Hinder et al, 1988; Noh, 2000). This syndrome has been defined based on clinical criteria only. The symptoms of this problem are chronic abdominal pain, persistent nausea, intermittent vomiting worsened by solid or liquid food (Britton et al., 2005; Hinder et al., 1988; Noh, 2000; Zang et al., 2018).

Several factors have been suggested to play a role in the development of Roux stasis syndrome. The most important role is the motility disorders of the traditional Roux anus (J. Y. Park & Kim, 2014; Y. S. Park et al., 2018; Sun et al., 2018). Altered motility of the Roux-Y anus may be responsible for Roux-Y stasis syndrome (Morrison et al., 1990; Tu et al., 1995). Roux stasis syndrome may occur due to the separation of the Roux anus from the natural small bowel pacemaker located in the proximal duodenum and the development of ectopic pacemakers in the proximal and middle part of the Roux limb after surgery (Karlstrom et al., 1989; Miedema, 1992; Morrison et al., 1990). These ectopic pacemakers generate new peristaltic waves in the oral direction and these retrograde contractions delay passage through the Roux anus and stasis (Karlstrom et al., 1989). The other factor is motility disorders of the gastric remnant after gastrectomy in which gastric pouch emptying is slowed in some cases (Britton et al., 2005; Gustavsson et al., 1988; Hinder et al., 1988; Noh, 2000). The higher incidence of Roux stasis syndrome after alkaline reflux gastritis surgery in our series may be due to motility disorder of the gastric remnant.

The addition of antrectomy and truncal vagotomy will make the gastric remnant atonic and this gastric pouch will impair the emptying of solid meals (Britton et al., 2005). According to some authors (Gustavsson et al., 1988; Sun et al., 2018), whether or not to perform vagotomy has no role in this. Another factor is performing afferent ans longer than 40 cm. Gustavsson et al. (Gustavsson et al., 1988) reported that the mean length of the conventional Roux-Y limb in patients with stasis was 41 cm, which was longer than 36 cm in patients without stasis.

Van Stiegman and Goff (Bismuth et al., 1978) proposed an alternative technique for Roux-Y construction in 1988. This operation is referred to as the uncut Roux-Y (U-RY) procedure. This method involves a loop gastro or esophagojejunostomy approximately 35-45 cm distal to the gastro or esophagojejunostomy and a side-to-side jejunojejunostomy. Afferent anuses are stapled proximal to the jejunojejunostomy and pancreatobiliary secretions are diverted through the jejunojejunostomy.

When the U-RY procedure is performed, normal jejunal peristalsis continues because neuromuscular continuity is maintained. Thus, motility disorders do not develop in the UR-Y limb and peristaltic waves in the oral direction do not occur (Miedema, 1992). Maintaining myoneural continuity between the duodenal pacemaker and the Roux limb may prevent Roux stasis syndrome (Kiciak et al., 2007; Zhang, 2006). Miedema et al. (Miedema, 1992) reported that stapler lines placed along the jejunal wall in dogs did not disrupt the myoneural continuity to the uncut Roux limb. Therefore, ectopic pacemakers are not seen in the uncut Roux-Y. Closure of the jejunal anus with staples or non-absorbable circular sutures does not interfere with the myoneural continuity between the duodenal pacemaker and the uncut Roux anus.

In the literature, it has been reported that the incidence of Roux stasis syndrome after U-RY is lower compared to

C-RY technique (Noh, 2000; Y. S. Park et al., 2018; Sun et al., 2018; Uyama et al., 2005; Yang et al., 2017). A recent meta-analysis (Sun et al., 2018) showed that the incidence of reflux gastritis or esophagitis, delayed gastric emptying and Roux stasis syndrome was statistically significantly lower in UR-Y operation. Some studies reported that the frequency of Roux stasis syndrome was lower in UR-Y compared to CR-Y, but this difference was not statistically significant (J. Y. Park & Kim, 2014; Park et al., 2018; Sah et al., 2020). In our series, the rate of Roux stasis was lower in UR-Y patients, but this difference was not statistically significant ($p>0.05$). The treatment of Roux stasis syndrome is usually conservative. The principles of this treatment are cessation of oral feeding, nasogastric decompression, intravenous fluids and some medications (metoclopramide, erythromycin, domperidone) (Britton et al., 2005; Hinder et al., 1988; Sun et al., 2018). The majority of patients recover with this treatment. However, severely symptomatic patients who do not improve with conservative measures are reoperated. In these cases, total or near-total gastrectomy is performed. Some studies (Britton et al., 2005; Hinder et al., 1988) have reported good results from this procedure. Therefore, U-RY procedures remain a preferred technique for gastroesophageal open or laparoscopic operations. (Ma et al, 2017; Noh, 2000; Sah et al, 2020; Tireli, 2012; Uyama et al, 2005; Wang et al, 2019; Yang et al, 2017; Zang et al, 2018) In our patients, recovery was achieved with conservative treatment and no patient required reoperation. For many years, hepaticojejunostomy with C-RY reconstruction has been used in many benign and malignant diseases. Cholangitis has been reported in 5-10% after this operation (AbdelRafee et al., 2015; Bismuth et al., 1978; Stefanini et al., 1975). Impaired intestinal motility at the Roux anus can lead to bile stasis and bacterial proliferation (Ducrotte et al., 1991; Vantrappen et al., 1977). This bacterial overgrowth in the Roux anus is a common and adverse event that causes cholangitis. Klaus et al. (Klaus et al., 2003) showed that the C-RY limb may be responsible for hepatic stasis, bacterial translocation and infection, leading to disruption of liver architecture in animals. Hepatic histomorphology in long-term survivors was found to be significantly better in U-RY looped animals compared to C-RY animals (Klaus et al., 2003). According to the findings in the literature, the U-RY technique prevents both motility disorders and bacterial overgrowth in the limb.

Klaus et al. (Klaus et al., 2003) studied small intestinal transit after biliodigestive anastomosis in rats using intravenous radioisotopes. They showed that large amounts of the isotope were retained in the liver and at the proximal end of the C-RY limb. This result was associated with microscopically more pronounced liver damage. Based on these findings, the authors stated that cholangitis and liver injury may develop after C-RY hepaticojejunostomy. Therefore, U-RY technique may be more beneficial than C-RY technique in terms of bile drainage and limb transit. In our series, cholangitis

developed in two C-RY hepaticojejunostomy patients without gallstones or anastomotic stenosis. These patients were treated conservatively. None of our U-RY patients developed cholangitis. There are several reports of disruption of staple lines in animal models and human subjects undergoing U-RY surgery (Nguyen Tu and Kelly, 1995; Park et al., 2018; Tu et al., 1995; Uyama et al., 2005; Yang et al., 2017). The same authors achieved permanent closure of the Roux anus using a novel wingless six-row linear stapler (Ma et al., 2017; Uyama et al., 2005; Wang et al., 2019; Zang et al., 2018). For permanent closure of the jejunum, Noh (Noh, 2000) proposed four or five seromuscular sutures with polypropylene around the jejunal wall circumference and tied the suture tightly. He showed that there was no disruption of the occlusion line with this technique. This method permanently closed the jejunal lumen but did not disrupt the myoneural continuity of the jejunum. We and others (Jangjoo et al., 2010; Sah et al., 2020; Tireli, 2012) used the same closure technique in the operation. In our series, we found no disruption of the occlusion line of the jejunal limb in the endoscopic examination of eight patients with long-term survival. Noh (Klaus et al., 2003), Sah (Sah et al., 2020), Tireli (Tireli, 2012) and Jangio (Jangjoo et al., 2010) also reported the same findings.

Limitations and Strengths

Since our study was retrospective, our results are limited. Our sample size may not be sufficient for statistical results. In addition, the low survival time of the malignant hepatobiliary patient group in the study limited our long-term results.

CONCLUSION

The results of studies in the literature suggest that the U-RY technique may be more effective than the C-RY technique in preventing Roux stasis. The U-RY anus reduces the time required for closure of the jejunum by incision, the blood flow of the jejunum is not impaired, and this ensures that intestinal peristalsis is not damaged (Ma et al, 2017; Park and Kim, 2014; Park et al, 2014; Park et al, 2018; Sah et al, 2020; Sun et al, 2018; Wang et al, 2019). For these reasons, the U-RY technique continues to be a preferred technique in laparoscopic or open gastroesophageal and biliary surgery. (Kiciak et al, 2007; Ma et al, 2017; Noh, 2000; Sah et al, 2020; Sun et al, 2018; Wang et al, 2019; Yang et al, 2017; Zang et al, 2018; Zhang, 2006). The rate of Roux stasis in our series is similar to the literature. According to the results of our series, U-RY anastomosis may be more effective than C-RY anastomosis to prevent Roux stasis. In addition, we think that U-RY anastomosis is technically easier than C-RY anastomosis. Our results are limited by the retrospective nature of our study and the small number of patients. Large series, prospective randomized studies on the results of Uncut Roux-Y technique in upper gastrointestinal or bilioenteric anastomoses are needed.

Acknowledgements

The authors would like to extend their sincere thanks to anyone who contributed to this study.

Conflict of Interest

The author declare no potential conflicts of interest with respect to the research, authorship and/or publication of this article.

Author Contributions

Plan, design: ST, SS; **Material, methods and data collection:** ST, SS, MT; **Data analysis and comments:** ST, SS; **Writing and corrections:** ST, MT.

Funding

None.

Ethical Approval

Institution: Ethics Committee of Celal Bayar University Faculty of Medicine

Date: 16.09.2020

Approval No: 539

REFERENCES

- AbdelRafee, A., El-Shobari, M., Askar, W., Sultan, A. M., & El Nakeeb, A. (2015). Long-term follow-up of 120 patients after hepaticojejunostomy for treatment of post-cholecystectomy bile duct injuries: A retrospective cohort study. *International Journal of Surgery*, 18, 205–210. <https://doi.org/10.1016/j.ijsu.2015.05.004>
- Bismuth, H., Franco, D., Corlette, M. B., & Hepp, J. (1978). Long term results of Roux-en-Y hepaticojejunostomy. *Surgery, Gynecology & Obstetrics*, 146(2), 161–167.
- Britton, J. P., Johnston, D., Ward, D. C., Axon, A. T. R., & Barker, M. C. J. (2005). Gastric emptying and clinical outcome after Roux-en-Y diversion. *British Journal of Surgery*, 74(10), 900–904. <https://doi.org/10.1002/bjs.1800741010>
- Ducrotte, P., Peillon, C., Guillemot, F., Testart, J., & Denis, P. (1991). Could recurrent cholangitis after Roux-en-Y hepaticojejunostomy be explained by motor intestinal anomalies? A manometric study. *The American Journal of Gastroenterology*, 86(9), 1255–1258.
- Gustavsson, S., Ilstrup, D. M., Morrison, P., & Kelly, K. A. (1988). Roux-Y stasis syndrome after gastrectomy. *The American Journal of Surgery*, 155(3), 490–494. [https://doi.org/10.1016/S0002-9610\(88\)80120-X](https://doi.org/10.1016/S0002-9610(88)80120-X)
- Hinder, R. A., Esser, J., & DeMeester, T. R. (1988). Management of gastric emptying disorders following the Roux-en-Y procedure. *Surgery*, 104(4), 765–772.
- Jangjoo, A., Mehrabi Bahar, M., & Aliakbarian, M. (2010). Uncut Roux-en-y esophagojejunostomy: A new reconstruction technique after total gastrectomy. *Indian Journal of Surgery*, 72(3), 236–239. <https://doi.org/10.1007/s12262-010-0059-7>
- Karlstrom, L. H., Soper, N. J., Kelly, K. A., & Phillips, S. F. (1989). Ectopic jejunal pacemakers and enterogastric reflux after Roux gastrectomy: effect of intestinal pacing. *Surgery*, 106(3), 486–495.
- Kiciak, A., Woliński, J., Borycka, K., Zabielski, R., & Bielecki, K. (2007). Roux-en-Y or ‘uncut’ Roux procedure? Relation of intestinal migrating motor complex recovery to the preservation of the network of interstitial cells of Cajal in pigs. *Experimental Physiology*, 92(2), 399–408. <https://doi.org/10.1113/expphysiol.2006.035253>
- Klaus, A., Hinder, R. A., Nguyen, J. H. ., & Nelson, K. L. (2003). Small bowel transit and gastric emptying after biliodigestive anastomosis using the uncut jejunal loop. *The American Journal of Surgery*, 186(6), 747–751. <https://doi.org/10.1016/j.amjsurg.2003.08.025>
- Ma, J.-J., Zang, L., Yang, A., Hu, W.-G., Feng, B., Dong, F., Wang, M.-L., Lu, A.-G., Li, J.-W., & Zheng, M.-H. (2017). A modified uncut Roux-en-Y anastomosis in totally laparoscopic distal gastrectomy: preliminary results and initial experience. *Surgical Endoscopy*, 31(11), 4749–4755. <https://doi.org/10.1007/s00464-017-5551-8>
- Miedema, B. W. (1992). The Roux Stasis Syndrome. *Archives of Surgery*, 127(3), 295. <https://doi.org/10.1001/archsurg.1992.01420030057011>
- Morrison, P., Miedema, B. W., Kohler, L., & Kelly, K. A. (1990). Electrical dysrhythmias in the roux jejunal limb: Cause and treatment. *The American Journal of Surgery*, 160(3), 252–256. [https://doi.org/10.1016/S0002-9610\(06\)80017-6](https://doi.org/10.1016/S0002-9610(06)80017-6)
- Nguyen Tu, B., & Kelly, K. A. (1995). Elimination of the Roux stasis syndrome using a new type of “uncut Roux” limb. *The American Journal of Surgery*, 170(4), 381–386. [https://doi.org/10.1016/S0002-9610\(99\)80308-0](https://doi.org/10.1016/S0002-9610(99)80308-0)
- Noh, S.-M. (2000). Improvement of the Roux limb function using a new type of “uncut Roux” limb. *The American Journal of Surgery*, 180(1), 37–40. [https://doi.org/10.1016/S0002-9610\(00\)00421-9](https://doi.org/10.1016/S0002-9610(00)00421-9)
- Park, J. Y., & Kim, Y. J. (2014). Uncut Roux-en-Y Reconstruction after Laparoscopic Distal Gastrectomy Can Be a Favorable Method in Terms of Gastritis, Bile Reflux, and Gastric Residue. *Journal of Gastric Cancer*, 14(4), 229. <https://doi.org/10.5230/jgc.2014.14.4.229>
- Park, Y. S., Shin, D. J., Son, S., Kim, K., Park, D. J., Ahn, S., Park, D. J., & Kim, H. (2018). Roux Stasis Syndrome and Gastric Food Stasis After Laparoscopic Distal Gastrectomy with Uncut Roux-en-Y Reconstruction in Gastric Cancer Patients: A Propensity Score Matching Analysis. *World Journal of Surgery*, 42(12), 4022–4032. <https://doi.org/10.1007/s00268-018-4715-6>
- Sah, B. K., Li, J., Yan, C., Li, C., Yan, M., & Zhu, Z. G. (2020). Anastomosis for distal gastrectomy in Chinese patients: uncut roux-Y or roux-Y? *BMC Surgery*, 20(1), 7. <https://doi.org/10.1186/s12893-019-0672-8>
- Stefanini, P., Carboni, M., Patrassi, N., Basoli, A., Bernardinis, G. De, & Negro, P. (1975). Roux-en-Y Hepaticojejunostomy. *Annals of Surgery*, 181(2), 213–219. <https://doi.org/10.1097/0000658-197502000-00016>
- Sun, M.-M., Fan, Y.-Y., & Dang, S.-C. (2018). Comparison between uncut Roux-en-Y and Roux-en-Y reconstruction after distal gastrectomy for gastric cancer: A meta-analysis. *World Journal of Gastroenterology*, 24(24), 2628–2639. <https://doi.org/10.3748/wjg.v24.i24.2628>
- Tireli, M. (2012). The results of the surgical treatment of alkaline reflux gastritis. *Hepato-gastroenterology*, 59(119), 2352–2356