

PAPER DETAILS

TITLE: Gastroprotective effect of tarantula cubensis extract in the indomethacin-induced peptic ulcer model in rats

AUTHORS: Fatma Nihan CANKARA,Özlem ÖZMEN,Hasan Basri SAVAS,Yasemin SAHIN,Caner GÜNAYDIN

PAGES: 278-284

ORIGINAL PDF URL: <https://dergipark.org.tr/tr/download/article-file/1299867>

Gastroprotective effect of tarantula cubensis extract in the indomethacin-induced peptic ulcer model in rats

Sıçanlarda indometazin ile indüklenmiş peptik ülser modelinde tarantula cubensis ekstraktının gastroprotektif etkisi

Fatma Nihan Cankara^{1*}, Özlem Özmen², Hasan Basri Savaş³, Yasemin Şahin¹, Caner Günaydın⁴

1.Department of Pharmacology, Suleyman Demirel University Faculty of Medicine, Isparta, Turkey

2.Department of Pathology, Mehmet Akif Ersoy University Faculty of Veterinary Medicine, Burdur, Turkey

3.Department of Biochemistry, Alanya Alaaddin Keykubat University Faculty of Medicine, Antalya, Turkey

4.Department of Pharmacology, Ondokuz Mayıs University Faculty of Medicine, Samsun, Turkey

ABSTRACT

Background: Gastric ulcers are the most common gastrointestinal disease, due to several factors in the industrialized world. They may also occur after many pharmacological agents, combined with gastroprotective agents such as proton pump inhibitors (PPI) or anti-acids, are used as a preferred approach to maintaining gastrointestinal health. Unexpected adverse effects in these combinations make natural products an important alternative option.

Methods: Therefore, the main aim of this study is to investigate one natural compound, the Tarantula cubensis extract (TCE), in the experimental peptic ulcer model which was created by a single administration of indomethacin (40 mg/kg, body weight) to fed state Wistar-albino rats. The animals were pre-treated with two-doses of the TCE (0.2 ml/kg) before the indomethacin administration. After six hours, they were euthanized and the stomach tissue was isolated for biochemical and immunohistochemical analysis. Total antioxidant status/total oxidant status (TAS/TOS), prostaglandin E2 (PGE2), and nuclear factor kappa-B (NF-κB) levels were determined with ELISA in tissue homogenates. Caspase-3, cyclooxygenase-2 (COX-2), inducible nitric oxide synthase (iNOS) and tumor necrosis factor-alpha (TNF-α), were visualized with immunohistochemistry in intact tissues.

Results: Pre-treatment with TCE increased PGE2 levels and decreased total oxidative status (TAS/TOS). Additionally, TCE alleviated the increase of (NF-κB) levels due to the indomethacin administration. Histopathological and immunostaining results showed that TCE mitigated elevated immunoreactivity of the caspase-3, COX-2, iNOS, and TNF-α which were the results of the indomethacin administration.

Conclusion: Our study demonstrated that pre-TCE treatment ameliorated indomethacin-induced peptic ulcers via antioxidant and anti-inflammatory actions.

Keywords: Tarantula cubensis extract, indomethacin, peptic ulcer, oxidative stress, inflammation

ÖZ

Amaç: Gastrik ülser, endüstrileşmiş dünyada çeşitli faktörler nedeniyle en sık görülen gastrointestinal hastalıktır. Bununla birlikte mide ülseri, gastrointestinal sağlığın korunması için genellikle tercih edilen proton pompa inhibitörleri (PPI) veya anti-asitler gibi birçok gastroprotektif farmakolojik ajanın kombine kullanılmasından sonra da nüks edebilmektedir. Bu kombinasyonlardaki beklenmedik olumsuz etkiler doğal ürünleri alternatif bir seçenek haline getirir. Bu nedenle, bu çalışmanın temel amacı, tek bir indometazin (40 mg/kg) ile oluşturulan deneysel peptik ülser modelinde doğal bileşiklerden biri olan Tarantula cubensis (TCE) ekstraktının etkisinin araştırılmasıdır.

Yöntemler: İndometazin uygulanmasından önce iki doz TCE (0.2 ml/kg) s.k yoldan uygulanmıştır. Tek doz İndometazin (40 mg/kg) uygulamasından altı saat sonra anestezi altında mide dokusu biyokimyasal ve immünohistokimyasal analiz için çıkarılmıştır. Total antioksidan durum/total oksidan durum (TAS/TOS), prostaglandin E2 (PGE2) ve nükleer faktör kappa-B (NF-κB) düzeyleri doku homojenatlarında ELISA ile belirlenmiştir. Kaspaz-3, siklooksijenaz-2 (COX-2), indüklenbilir nitrik oksit sentaz (iNOS) ve tümör nekroz faktörü-alfa (TNF-α) immünohistokimya ile görüntülenmiştir.

Bulgular: TCE ile ön tedavi PGE2 düzeylerini artırdı ve toplam oksidatif durumu (TAS / TOS) azaltmıştır. Ek olarak, TCE indometazin uygulamasına bağlı olarak NF-κB düzeylerindeki artışı hafifletmiştir. Histopatolojik ve immünboyama sonuçları, TCE'nin, indometazin uygulamasının sonuçları olan kaspaz-3, COX-2, iNOS ve TNF-α'nın yüksek immünoreaktivitesini azalttığını göstermiştir.

Sonuç: Çalışmamız TCE tedavisinin, antioksidan ve antiinflamatuar etkiler yoluyla indometazine bağlı peptik ülserleri iyileştirdiğini göstermiştir.

Anahtar kelimeler: Tarantula Cubensis Ekstraktı, indometazin, peptik ülser, oksidatif stres, inflamasyon

Received: 04.05.2020 Accepted: 05.07.2020 Published (Online):29.10.2020

* Corresponding Author: Fatma Nihan Cankara, Assistant Professor, PhD. Department of Pharmacology Suleyman

Demirel University, Faculty of Medicine Isparta, Turkey, Phone: +90 532 599 42 79 e-mail: nihancankara@yahoo.com

ORCID: 0000-0002-2367-6412

To cited: Cankara FN, Özmen Ö, Savaş HB, Şahin Y, Günaydın C. Gastroprotective effect of tarantula cubensis extract in the indomethacin-induced peptic ulcer model in rats. Acta Med. Alanya 2020;4(3):278-284. doi:10.30565/medalanya.797406

INTRODUCTION

Gastric ulcer is the most prevalent gastrointestinal system disease and nearly 15 patients in every 15,000, results in death in the world [1]. This chronic and multifactorial disease frequently relapses 10% over of the lifetime and many factors, such as *Helicobacter pylori*, smoking, stress, alcohol consumption and non-steroidal anti-inflammatory drug (NSAIDs) use, increase risk and incidence of the disease throughout the lifetime [2].

Sustained production of the free radicals and antioxidant mechanisms against these radicals are in the balance of the normal homeostasis and dysregulation of this balance is related to more than one hundred disease pathologies [3]. However, this bidirectional balance between oxidative stressors and antioxidant mechanisms is crucially maintained in the human body, as reactive products are continuously formed by exogenous and endogenous sources [4]. Owing to the complex pathophysiology of gastric ulcers, antioxidant and anti-inflammatory compounds that can affect gastric prostaglandin synthesis have major importance in the ways to seek gastric ulcer treatment [5]. Although proton pump inhibitors are frequently prescribed drugs against NSAID-induced gastrointestinal damage, long-term gastric ulcer treatment with these drugs were reported to be a risk factor for bone fractures and unwanted cardiovascular events [4]. The main reason for gastric ulcers seen in NSAID users is that activated 5-Lipoxygenase (5-LOX) pathways becomes more dominated due to the suppressed arachidonic acid/cyclo-oxygenase cascade [4]. Various studies have demonstrated the gastroprotective effects of natural products in experimental gastric ulcer models [6].

Tarantula cubensis extract (TCE) is commonly used in the veterinary field [7],[8]. Although, major mechanism behind the therapeutic effects of TCE is not clearly identified, it is commonly believed that stimulation of cellular defense mechanisms and boosting of the anti-inflammatory mechanism occurs in favor of the healing of the inflammatory lesions, such several ulcers and abscess [9],[10]. Therefore, it is rational to think that the suggested anti-inflammatory and wound-healing properties

of TCE might be have beneficial effects in the gastric ulcer treatment.

The aim of this study was the investigation of the effects of TCE administration on an experimental gastric ulcer model in rats. Because the inflammation and dysregulated oxidative balance are key mediators in disease pathophysiology, we tried to investigate the effects of TCE on the oxidative status and well-known inflammatory markers on stomach tissue, and reveal the possible effects and mechanisms in the peptic-ulcer disease.

MATERIAL AND METHODS

Animals

Experiments were performed with 8-10 weeks old male Wistar-albino rats, which were kept under 12-hour light/dark cycles with constant room temperature ($22 \pm 2^\circ\text{C}$) and humidity (%55-60), in separate cages. The study was conducted in accordance with the guideline for the care and use of laboratory animals approved by Experimental Animals Research Council (2018-416) and all efforts were made throughout the experiment in reducing animal suffering.

Chemicals

Indomethacin was purchased from Sigma Aldrich (St. Louis, MO, USA) and Theranekron® alcoholic extract (1:100) of *Tarantula cubensis* in alcoholic solution 1 mg/ml, was purchased from Richter-Pharma AG, Wels, Austria. Indomethacin was dissolved in the saline and the TCE dose was selected based on the previous studies [9].

Experimental groups and drug treatments

Animals were divided into 4 equal groups: Control (n=8), IDM (n=8), TCE (n=8), TCE+IDM (n=8). Throughout a 24-hour fasting period in all the groups, animals were provided with unrestricted access to water. Experimental groups and the administration schedules were designed as follows:

- 1-Control group: 0.2 ml saline (1st and 4th day) + 24 hour fasting (5th day) + 1 ml saline (i.p, 6th day) + 6 hours after last administration, sacrifice.
- 2- IDM group: 0.2 ml saline (1st and 4th day) +

24 hour fasting (5th day) + IDM 40 mg/kg [11] intraperitoneal (i.p, 6th day) + 6 hours after last administration, sacrifice.

3- TCE group: 0.2 ml/kg TCE solution (14) subcutaneous (s.c) (1st and 4th day) + 24 hour fasting (5th day) + 1 ml saline (i.p, 6th day) + 6 hours after last administration, sacrifice.

4- TCE+IDM group: 0.2 ml/kg TCE solution (s.c, 1st and 4th day) + 24 hour fasting (5th day) + IDM 40 mg/kg (i.p, 6th day) + 6 hours after last administration, sacrifice.

Biochemical analysis

After all animals were euthanized, abdomens were dissected and opened along the greater curvature for observation of the number and locations of gastric lesions. A piece of stomach was dissected and homogenized in an ice-cold phosphate buffer (pH 7.4) and stored in -80°C until analysis. The thawed samples of homogenized tissue were centrifuged at 10,000 g for 10 minutes at 4°C. Protein concentrations in the supernatant was measured by using the Lowry method [12]. TAS and TOS were determined from the same samples after the determination of protein levels. Total Antioxidant Capacity (TAS) and Total Oxidant Capacity (TOS) levels were measured spectrophotometrically by using commercially available ELISA kits [13]. Results were given in mmol Trolox Eq/L unit for TAS and $\mu\text{mol H}_2\text{O}_2\text{Eq/L}$ unit for TOS. The TAS and TOS results for the tissues were calculated via division by the protein value and OSI (Oxidative Stress Index) ratio was expressed by using the TOS/TAS formula.

Histopathological analysis

Stomach tissues were harvested for microscopical evaluation in all rats, during the necropsy. Routine tissue processing method were performed by using an automatic tissue processing equipment (Leica ASP300S; Leica Microsystem, Nussloch, Germany) for formalin-fixed tissues. Then the gastric tissue samples were embedded in paraffin, and five serial sections taken from the blocks at 5 μm thickness by a fully automatic microtome (Leica RM 2155, Leica Microsystem, Nussloch, Germany). One of the sections was stained routinely with hematoxylin–eosin (H&E) and

the remaining sections on poly-L-lysine slides were used for the immunohistochemical method. The sections were immunostained with active caspase-3 [Anti-caspase-3 antibody, (ab4051; Abcam-Cambridge, UK)], TNF- α [anti-TNF- α antibody (ab6671; Abcam -Cambridge, UK)], inducible nitric oxide synthase [Anti-iNOS antibody (ab15323; Abcam -Cambridge, UK)] and COX-2 (Cat. no: RM-9121-S0, Thermo scientific, Fremont, USA) antibodies, according to the instructions of the manufacturer's streptavidin biotin peroxidase method. Primary antibodies were incubated for a period of 60 minute using a 1/100 dilution. For secondary antibody, a ready-to-use commercial kit [EXPOSE Mouse and Rabbit Specific HRP/DAB Detection IHC kit (ab80436)] was used. As chromogen 3,3-diaminobenzidine (DAB) were applied for 5 minutes for all slides. For negative controls, the incubation with primary antiserum was omitted. All evaluations were performed by a pathologist from another university, in a blinded manners. To evaluate the percentage of immune-positive cells for each marker, 100 cells were counted in 10 different fields for every section, at a magnification of X40. Statistical analyses were subjected of the results obtained from the image analyzer and the morphometric analysis for microscopical evaluation were performed using the Database Manual Cell Sens Life Science Imaging Software System (Olympus Co., Tokyo, Japan).

Statistical analysis

All data obtained from experiments was expressed as mean \pm SD and analyzed with the one-way analysis of variance (ANOVA), followed by Bonferroni's correction which was used for multiple comparison. P values less than 0.05 were considered significant and all analysis carried out with the SPSS (v21.0, Chicago, Illinois).

RESULTS

Pre-TCE treatment decreased observable gastric hemorrhages due to the indomethacin administration

At the overall examination there was no lesions seen in the control group (shown in Fig. 1. a). IDM induced severe gastric damage, such as mucosal lesions characterized by brown-colored marked

hemorrhages (shown in Fig. 1. b). Additionally, there were no observable lesions in the TCE group as with the control group (shown in Fig. 1. c). Furthermore, TCE, before IDM administration, decreased observable gross hemorrhages at the gastric mucosa (shown in Fig. 1. d).

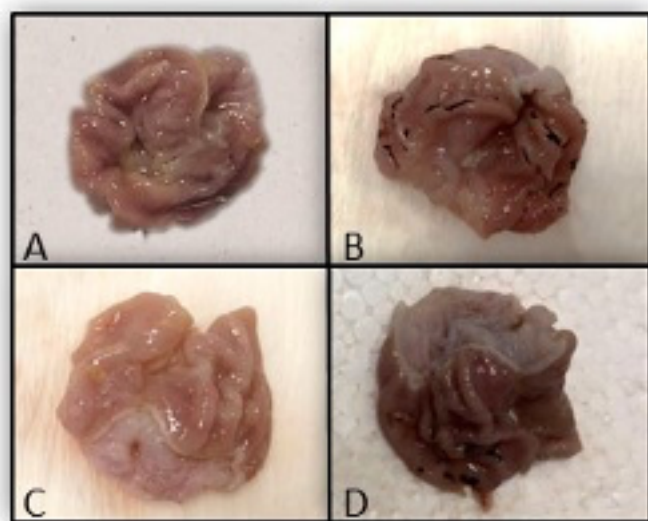


Fig. 1. Macroscopic images of stomach tissues are shown as control (a), IDM (b), TCE (c) and TCE+IDM (d) groups, respectively. Normal mucosal view in control and TCE groups (a, c) Hemorrhages and damage in stomach tissue clearly visible (b), Reduced hemorrhagic areas compared with IDM group (d).

Indomethacin-induced oxidative stress was alleviated with pre-TCE treatment

As expected, TCE alone administration did not cause any change on TAS/TOS levels and OSI ratio. IDM administration increased TAS (shown in Fig. 2. a) levels and decreased TOS (shown in Fig. 2. b) levels, resulting in a significantly increased OSI ratio (data not shown) ($p < 0.05$), while TCE alleviated the alteration of the oxidative stress parameters as a result of IDM administration ($p > 0.05$).

Pre-TCE attenuated the increase of PGE2 and NF- κ B levels

Gastric PGE2 (shown in Fig. 2. c) levels were significantly decreased in the IDM group ($p < 0.05$). Additionally, NF- κ B (shown in Fig. 2. d) increased in the IDM group, as expected. Although, these parameters did not change in the TCE group, pre-TCE treatment significantly ameliorated the decrease in the PGE2 and increase in the NF- κ B levels due to the IDM insult ($p < 0.05$).

Indomethacin-induced increased inflammatory immunoreactivity and apoptosis inhibited by pre-TCE treatment

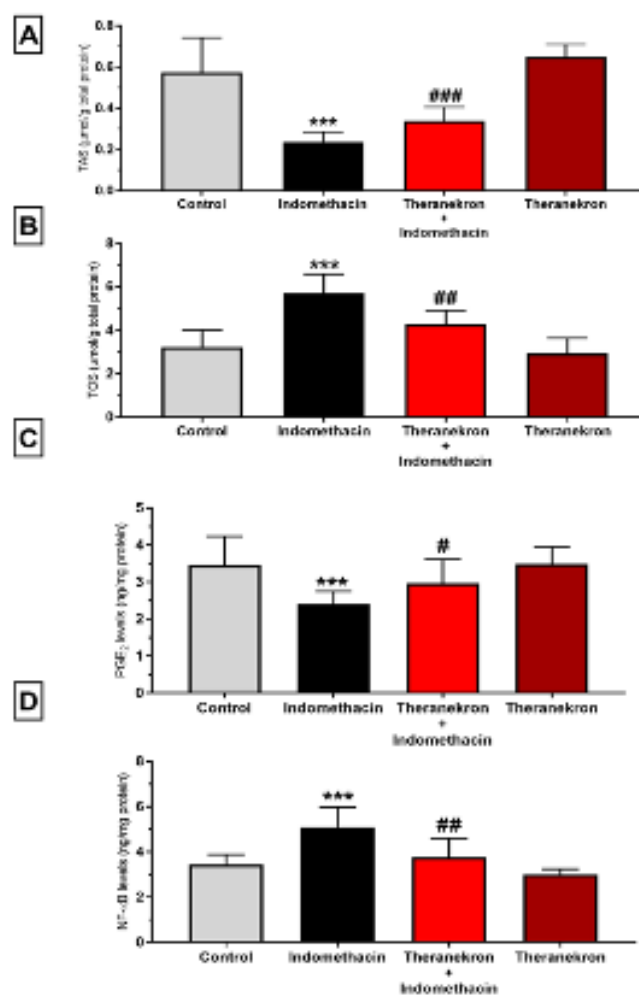


Fig. 2. TAS (a), TOS (b), PGE₂ (c) and NF- κ B (d) levels in the all experimental groups were expressed as mean \pm SD. *** $p < 0.001$ versus control group, ### $p < 0.001$, ## $p < 0.01$, # $p < 0.05$ versus IDM group.

Histopathological examination of the stomachs revealed large and deep ulcers in the IDM group. In these rat's stomachs, deep damage, mucosal hemorrhage, marked edema and numerous leucocytes infiltration of the submucosal layer were observed. The TCE treatment caused a decrease in both the diameter and depth of the ulcers. The gastric mucosa of the TCE and control groups demonstrated normal tissue and structure; the histopathological findings between the groups are shown in Figure 3. Marked Caspase-3 (shown in Fig. 3A), COX-2 (shown in Fig. 3. b), iNOS (shown in Fig. 3. c) and TNF- α (shown in Fig. 3. d) expression was observed in stomach cells, in the lesioned areas of the indomethacin administered

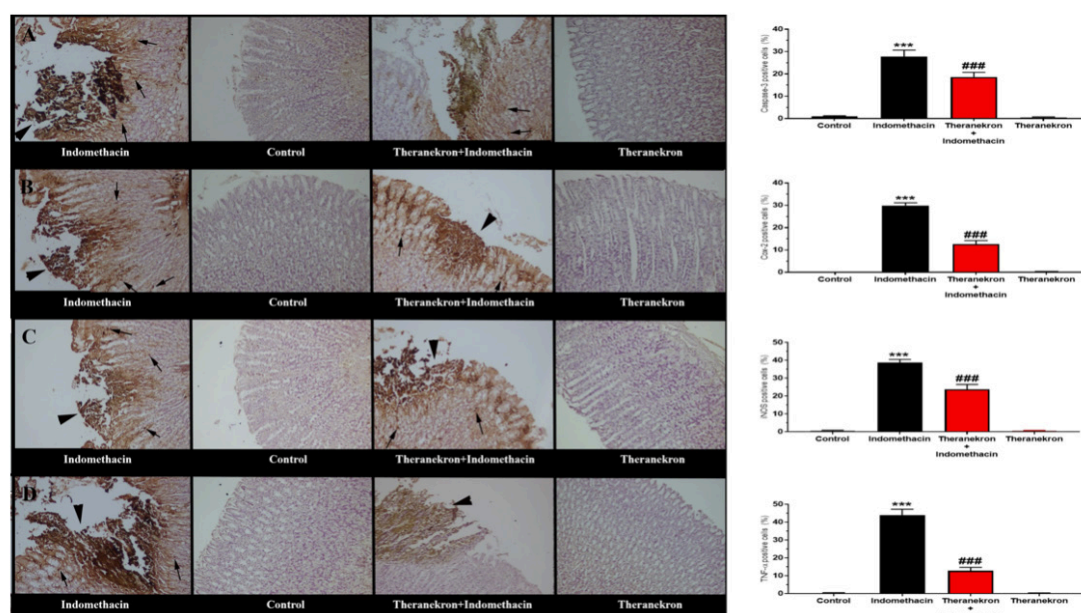


Fig. 3. Histopathological examination of all experimental groups. Hematoxylin and eosin staining of gastric tissues (A) with severe mucosal lesion (arrow head) and hemorrhage in the IDM group, normal gastric mucosae in control group, decreased lesion and hemorrhage (arrow head) in the TCE+ IDM group, normal tissue architecture in a rat's in stomach belonging TCE group, HE. Caspase-3 (a), COX-2 (b), iNOS (c) and TNF- α (d) immunoreaction between the groups. Severe expression in cells (arrows) in IDM group around the lesion, (arrowhead), no expression in control group, decreased expression (arrows) in IDM+TCE group, negative expression in TCE group. Streptavidin biotin peroxidase method, Bars=50 μ m. Additionally, caspase-3 (a), COX-2 (b), iNOS (c) and TNF- α (d) immunoreactivity in the all experimental groups were expressed as mean \pm SD. All data represented as mean \pm SD. *** $p < 0.001$, ** $p < 0.01$ versus control group, ### $p < 0.001$ versus IDM group.

group. Both epithelial and mesenchymal cells expressed the markers. The cells near the lesions also expressed all markers. There was no or only slight reactions in the TCE and control groups. There was no positive reaction in the primary antibody omitted sections. Additionally, in a number of positive cells stained with Caspase-3, COX-2, iNOS, TNF- α significantly increased in IDM group and that increase reversed with TCE administration (shown in Fig. 3).

DISCUSSION

This study demonstrated that pre-TCE treatment ameliorated IDM-induced gastric damage. TCE increased the antioxidant response and decreased the inflammatory levels as well as immunoreactivity in the gastric tissue.

IDM, a commonly prescribed drug for its anti-inflammatory properties, is also used for experimental model of gastric ulcer in rats [14]. Free radical generation because of inhibited prostaglandin synthesis by IDM, has been accepted as crucial biochemical reaction in the physiopathology of gastric ulcer [15]. Utsumi et. Al. suggested that over-activation of the inflammatory response caused by IDM, could be dependent on the antioxidant/oxidant status of gastric cells

[16]. Thus, compounds that can cause antioxidant actions could be targeted as a potential treatment option in NSAIDs-induced gastric lesions. In the abundance of oxidative markers, TAS and TOS plasma levels and OSI ratio are generally deemed a better indicator of the body's total anti-oxidant defense [17]. IDM-induced gastric ulcer via oxidative and inflammatory actions with increasing OSI parameters have been already studied [18] and compounds with antioxidant actions showed protective actions in the indomethacin-induced gastric ulcers by several groups [19]. In line with these studies, ours demonstrated that pre-treatment of TCE alleviated increased OSI ratio, which means that the antioxidant properties of TCE might have a role in the gastroprotective actions. However, caspase-3 is a non-selective apoptosis marker and it is well-known that increased ROS and oxidative stress, results in the cellular apoptosis via cytochrome C activated caspase-3. Inhibition of the elevation of the ROS levels in the gastric tissue, and the resulting decrease in the caspase-3 levels, are suggested as a protective mechanism against oxidative stress in the gastric tissue. Several groups demonstrated that decreasing ROS levels and increasing antioxidant enzymes in the gastric tissue, resulted in increased cellular survival and decreased caspase-3 apoptosis

immunoreactivity. Maintaining gastric mucosal integrity against oxidative stress and ROS are elegant targets as gastroprotective therapy options. In accordance with these studies, robust increases of caspase-3 immunoreactivity after indomethacin administration alleviated with the pre-TCE treatment, which indicates diminished caspase-3 cellular loss. Additionally, antioxidant effects of pre-TCE treatment supports this notion and demonstrates that decreased caspase-3 immunoreactivity might be the result of the antioxidant properties of the TCE.

Owing to the general mechanism of action of NSAIDs, decrease in the PGE2 levels and inhibition of COX isozymes in gastric mucosa exacerbates gastric ulcers in most animal species [20]. COX 2 in particular, has been known to modulate glandin-mediated mucosal defense in the gastric tissue [21]. Although it seems controversial, increased expressions of COX-2 mRNA after indomethacin administration have been considered as a gastric mucosal defense against increased inflammatory injury [22]. As a marker of the gastric inflammatory damage, inhibition of the increased COX-2 immunoreactivity is attenuated with pre-TCE treatment. In addition to its antioxidant action, that anti-inflammatory action of TCE possibly contributes effects on the PGE2 levels. Decreased PGE2 levels, which are a potent protector in the gastric tissue, is possibly the result of the selectivity of indomethacin on COX-1 more than COX-2. PGE2 naturally protect gastric mucosa against acidic damage through increasing mucus and bicarbonate secretion, and compounds that increase PGE2 act as a protector in gastric acid induced peptic damage [23]. Also, Abood et al. suggested that PGE2 could inhibit TNF- α production, which is another anti-inflammatory action in the context of the gastroprotection [24]. In line with these results, inhibition of the decrease in the PGE2 levels and increase in the TNF- α immunoreactivity in the gastric tissue by pre-TCE treatment seen in our study, suggest that gastroprotective action of TCE might be mediated with PGE2. Besides PGE2, NO is another important mediator in the NSAIDs-induced gastric ulcers [25] after discovering the role of NO in mucosal damage, several NO-containing NSAIDs were used as anti-inflammatory drugs, which deprive of the gastric damage potential. NO

has been shown to regulate gastric pH through maintaining blood flow and vasodilation, and drugs that activate NO synthesis (iNOS) or increase free NO levels, could diminish gastric ulcer damage [19]. In parallel with that knowledge, increased iNOS levels after indomethacin administration is considered as a natural defense mechanism against mucosal injury, as seen in the COX-2. Therefore, the alleviated iNOS immunoreactivity increase seen in our study suggests that pre-TCE treatment protected against indomethacin-induced inflammatory gastric damage, in line with COX-2 immunoreactivity.

The empirical results reported herein should be considered in the light of some limitations. First, the study focused on the effects of venom that was extracted from a tarantula. Limited studies showed its beneficial effects in the treatment of cutaneous papillomatosis, mammary adenocarcinomas, as well as in traumatic tendon injuries in rats, in many inflammatory lesions and in particular in the healing processes of open wounds. According to studies about TCE, it was shown that TCE has antioxidant and anti-inflammatory properties, and can be used beneficially for its effects on open wound healing. Therefore, it is rational to think of possible protective effects of TCE on peptic ulcer pathology, which have similar pathophysiological regenerative mechanism [26].

In conclusion, to the best of our knowledge ours is the first study regarding the effects of pre-TCE treatment in the experimental gastric ulcer models. Our study demonstrated that pre-TCE treatment decreased oxidative stress and alleviated disruption of the mucosal integrity. Pre-administration of TCE also alleviated inflammatory response in the gastric tissue, via effecting COX-2, iNOS and PGE2 expression in the gastric tissue.

Financial disclosure: The authors declared that this study has received no financial support.

Conflict of interest: No conflict of interest was declared by the authors.

REFERENCES

1. Graham DY. History of *Helicobacter pylori*, duodenal ulcer, gastric ulcer and gastric cancer. *World J Gastroenterol* 2014; 20(18): 5191-5204. doi:10.3748/wjg.v20.i18.5191
2. Mabeku LBK, Nana BN, Bille BE, Tchuenguem RT, Nguépi E. Anti-helicobacter pylori and antilcerogenic activity of *Aframomum pruinosum* seeds on indomethacin-induced gastric ulcer in rats. *Pharm Biol* 2017; 55(1): 929-936. doi:10.1080/13880209.2017.1285326
3. Chen P, Shen Y, Shi H, et al. Gastroprotective effects of Kangfuxin-against etha-

- nol-induced gastric ulcer via attenuating oxidative stress and ER stress in mice. *Chem Biol Interact* 2016; 260: 75-83. doi:10.1016/j.cbi.2016.10.021
4. Kinoshita Y, Ishimura N, Ishihara S. Advantages and disadvantages of long-term proton pump inhibitor use. *J Neurogastroenterol Motil* 2018; 24(2): 182-196. doi:10.5056/jnm18001
 5. Repetto MG, Llesuy SF. Antioxidant properties of natural compounds used in popular medicine for gastric ulcers. *Brazilian J Med Biol Res* 2002; 35(5): 523-534. doi:10.1590/S0100-879X2002000500003
 6. Kuna L, Jakab J, Smolic R, Raguz-Lucic N, Vcev A, Smolic M. Peptic Ulcer Disease: A Brief Review of Conventional Therapy and Herbal Treatment Options. *J Clin Med* 2019; 8(2): 179. doi:10.3390/jcm8020179
 7. Duz E, Icen H, Arserim NB, Cakmak F, Bakir B, Uysal E. Comparison of classic, theranekron and classic-plus Theranekron treatment on the foot and mouth disease lesions in cattle in Van, Diyarbakir and Ankara regions in Turkey. *J Anim Vet Adv* 2012; 11(18): 3258-3261. doi:10.3923/javaa.2012.3258.3261
 8. Kizilay Z, Aktas S, Kahraman Cetin N, Kilic MA, Ozturk H. Effect of Tarantula cubensis extract (Theranekron) on peripheral nerve healing in an experimental sciatic nerve injury model in rats. *Turk Neurosurg* 2019; 29(5): 743-749. doi:10.5137/1019-5149.JTN.26162-19.2
 9. Gül Satar NY, Cangül IT, Topal A, Kurt H, Ipek V, Onel GI. The effects of Tarantula cubensis venom on open wound healing in rats. *J Wound Care* 2017; 26(2): 66-71. doi:10.12968/jowc.2017.26.2.66
 10. Oryan A, Moshiri A, Raayat AR. Novel application of Theranekron® enhanced the structural and functional performance of the tenotomized tendon in rabbits. *Cells Tissues Organs* 2012; 196(5): 442-455. doi:10.1159/000337860
 11. Oluwabunmi I, Abiola T. Gastroprotective effect of methanolic extract of Gomphrena celosioides on indomethacin induced gastric ulcer in Wistar albino rats. *Int J Appl Basic Med Res* 2015; 5(1): 41. doi:10.4103/2229-516x.149238
 12. LOWRY OH, ROSEBROUGH NJ, FARR AL, RANDALL RJ. Protein measurement with the Folin phenol reagent. *J Biol Chem* 1951; 193(1): 265-275. doi:10.1016/0922-338X(96)89160-4
 13. Erel O. A new automated colorimetric method for measuring total oxidant status. *Clin Biochem* 2005; 38(12): 1103-1111. doi:10.1016/j.clinbiochem.2005.08.008
 14. Lichtenberger LM. The Hydrophobic Barrier Properties of Gastrointestinal Mucus. *Annu Rev Physiol* 1995; 57(1): 565-583. doi:10.1146/annurev.ph.57.030195.003025
 15. Takeuchi K. Prostaglandin EP Receptors and Their Roles in Mucosal Protection and Ulcer Healing in the Gastrointestinal Tract. *Adv Clin Chem* 2010; 51(C): 121-144. doi:10.1016/S0065-2423(10)51005-9
 16. Utsumi H, Yasukawa K, Soeda T, et al. Noninvasive mapping of reactive oxygen species by in vivo electron spin resonance spectroscopy in indomethacin-induced gastric ulcers in rats. *J Pharmacol Exp Ther* 2006; 317(1): 228-235. doi:10.1124/jpet.105.095166
 17. Ghiselli A, Serafini M, Natella F, Scaccini C. Total antioxidant capacity as a tool to assess redox status: Critical view and experimental data. *Free Radic Biol Med* 2000; 29(11): 1106-1114. doi:10.1016/S0891-5849(00)00394-4
 18. Abdel-Raheem IT. Gastroprotective effect of rutin against indomethacin-induced ulcers in rats. *Basic Clin Pharmacol Toxicol* 2010; 107(3): 742-750. doi:10.1111/j.1742-7843.2010.00568.x
 19. Farzaei MH, Abdollahi M, Rahimi R. Role of dietary polyphenols in the management of peptic ulcer. *World J Gastroenterol* 2015; 21(21): 6499-6517. doi:10.3748/wjg.v21.i21.6499
 20. Chattopadhyay S, Adhikary B, Yadav SK, Roy K, Bandyopadhyay SK. Black tea and theaflavins assist healing of indomethacin-induced gastric ulceration in mice by antioxidative action. *Evidence-based Complement Altern Med* 2011; 546560. doi:10.1155/2011/546560
 21. Taira K, Watanabe T, Tanigawa T, et al. Roles of cyclooxygenase-2 and prostaglandin E receptors in gastric mucosal defense in Helicobacter pylori-infected mice. *Inflammopharmacology* 2007; 15(3): 132-138. doi:10.1007/s10787-006-1561-1
 22. Takeuchi K. Pathogenesis of NSAID-induced gastric damage: Importance of cyclooxygenase inhibition and gastric hypermotility. *World J Gastroenterol* 2012; 18(18): 2147-2160. doi:10.3748/wjg.v18.i18.2147
 23. Bertrand V, Guessous F, Le Roy AL, et al. Copper-indomethacinate associated with zwitterionic phospholipids prevents enteropathy in rats: Effect on inducible no synthase. *Dig Dis Sci* 1999; 44(5): 991-999. doi:10.1023/A:1026668816189
 24. Abood WN, Abdulla MA, Ismail S. Involvement of inflammatory mediators in the gastroprotective action of Phaleria macrocarpa against ethanol-induced gastric ulcer. *World Appl Sci J* 2014; 30(30 A): 344-350. doi:10.5829/idosi.wasj.2014.30.icmrp.48
 25. Wallace JL. Nitric oxide in the gastrointestinal tract: opportunities for drug development. *Br J Pharmacol* 2019; 176(2): 147-154. doi:10.1111/bph.14527
 26. El-Ela FIA, Farghali AA, Mahmoud RK, Mohamed NA, Moaty SAA. New Approach in Ulcer Prevention and Wound Healing Treatment using Doxycycline and Amoxicillin/LDH Nanocomposites. *Sci Rep* 2019; 9(1): 6418. doi:10.1038/s41598-019-42842-2