

## PAPER DETAILS

TITLE: Effect of miRs-17/20 on vasospasm in subarachnoid hemorrhage model of rats

AUTHORS: Basak BÜYÜK, Ümit Ali MALÇOK

PAGES: 256-262

ORIGINAL PDF URL: <https://dergipark.org.tr/tr/download/article-file/2569515>

## Effect of miRs-17/20 on vasospasm in subarachnoid hemorrhage model of rats

### miR-17/20'nin Sıçanların Subaraknoid Kanama Modelinde Gelişen Vazospazm Üzerine Etkisi

Başak Büyük<sup>1\*</sup>, Ümit Ali Malçok<sup>2</sup>

1.İzmir Democracy University, Faculty of Medicine, Department of Histology and Embryology, İzmir, Turkey

2.Çanakkale Onsekiz Mart University, Faculty of Medicine, Department of Neurosurgery, Çanakkale, Turkey

#### ABSTRACT

**Aim:** To investigate the effects of melatonin and miRNA-17/20 administration on vasospasm and vascular damage on the bacillary artery in the Subarachnoid hemorrhage (SAH) model of rats.

**Methods:** Rats were divided into 6 groups: Sham, SAH, SAH+NegmiRNA, SAH+MEL, SAH-miRs-17/20 group, SAH+MEL+miRs-17/20. For creating the SAH model the skin was cut with a vertical incision in the anterior region of the head. 120 µL of fresh non-heparinized autologous arterial blood collected from the tail artery was injected into the prechiasmatic cistern under aseptic conditions. All steps in the Sham were the same as in the SAH group, except for blood injection. In the SAH+NegmiRs-17/20, miRs-17/20 miRNA Mimic-Negative Control#1 was administered 1 hour after SAH operation. In the SAH+MEL, 10 mg/kg melatonin was administered intraperitoneally 1 hour after the SAH operation. In the SAH-miRs-17/20, mimic-miR-17 and mimic-miR-20 were given intranasally 1 hour after the SAH operation. In the SAH+MEL+miRs-17/20, intranasal mimic-miR-17 and intraperitoneal melatonin were administered 1 hour after the SAH operation. Brain samples, including the bacillary artery, were taken and subjected to routine tissue processing procedures. Vessel samples were evaluated and graded in histological sections stained with the H-E method in terms of vasospasm, edema in the tunica media, and folding of the lamina elastica interna.

**Results:** The co-administration of melatonin and miRs-17/20 reduced the vasospasm and edema formation in the vessel wall. It has also been demonstrated that the application of miRs-17/20 after SAH alone reduces the development of edema in the vessel wall and folding of the internal lamina elastica due to vasospasm.

**Conclusion:** It has been shown that miRs-17/20 can reduce vasospasm in the vessel wall and prevent vessel damage by reducing edema.

Keywords: Subarachnoid Hemorrhage, microRNAs, melatonin, rat

#### ÖZ

**Amaç:** Mevcut çalışmamızın amacı, ratlarda oluşturulan subaraknoid kanama (SAH) modelinde melatonin ve miRNA-17/20 uygulamasının basiller arterde gelişen vazospazm ve damar hasarı üzerine etkisinin araştırılmasıdır.

**Yöntemler:** Çalışmada kullanılan 36 adet sıçan 6 gruba ayrılmıştır; Sham, SAH, SAH+NegmiRNA, SAH+MEL, SAH-miRs-17/20 group, SAH+MEL+miRs-17/20. Sıçanlara anestezi altında SAH modeli uygulandı. Kafanın ön bölgesinden dikey bir kesi ile cilt açılarak kemiğe ulaşıldı. İnsizyondan sonra, kuyruk arterinden toplanan 120 µL heparinize olmayan taze otolog arteriyel kan aseptik koşullar altında 10 saniyede yavaşça prekişmatik sistemaya enjekte edildi. Sham grubunda kan enjeksiyonu dışında tüm basamaklar SAH grubuyla aynıydı. SAH+NegmiRs-17/20 grubunda, miRs-17/20 miRNA Mimic Negative Control#1 SAH operasyonundan 1 saat sonra uygulandı. SAH+MEL grubunda, SAH operasyonundan 1 saat sonra 10 mg/kg melatonin intraperitoneal olarak verildi. SAH-miRs-17/20 grubundaysa SAH operasyonundan 1 saat sonra intranasal olarak mimic-miR-17 ve mimic-miR-20 verildi. SAH+MEL+miRs-17/20 grubunda, SAH operasyonundan 1 saat sonra intranasal mimic-miR-17 ile intraperitoneal melatonin (10 mg/kg) uygulandı. Deney sonunda sıçanlardan basiller arteri de içeren beyin örnekleri alınıp rutin doku takip işlemlerine tabi tutuldu. Sonrasında H-E yöntemi ile boyanan histolojik kesitlerde damar örnekleri vazospazm, tunica mediada ödem ve lamina elastica internada kıvrımlanma kriterleri açısından değerlendirilip derecelendirildi.

**Bulgular:** SAH modeli oluşturulan sıçanlarda, SAH modeli sonrası melatonin ve miRs-17/20'nin birlikte uygulanmasının damar duvarında oluşan vazospazm ve ödem oluşmasını anlamlı şekilde azalttığı gösterilmiştir. SAH sonrası miRs-17/20 uygulamasının da tek başına damar duvarında ödem gelişmesini ve vazospazma bağlı lamina elastica internada kıvrımlanmayı azalttığı ortaya konmuştur.

**Sonuç:** Çalışmamızda, miRs-17/20'nin damar duvarında vazospazmı azaltabileceği, ödemi de azaltarak damar hasarını önleyebileceği gösterilmiştir.

Anahtar kelimeler: Subaraknoid kanama, microRNA, melatonin, sıçan

Received: 01.08.2022 Accepted: 29.10.2022 Published (Online): 31.12.2022

\*Corresponding Author: Başak Büyük, İzmir Democracy University, Faculty of Medicine, Department of Histology and Embryology, İzmir, Turkey, Phone:05052372701 drbasakbuyuk@hotmail.com

ORCID : 0000-0003-1817-2241

**To cited:** Büyük B., Malçok UA. Effect of miRs-17/20 on Vasospasm in Subarachnoid Hemorrhage Model of Rats. Acta Med. Alanya 2022;6(3):256-262 doi: 10.30565/medalanya.1152279

## INTRODUCTION

**S**ubarachnoid hemorrhage (SAH) is a neurological emergency caused by the extravasation of blood into the subarachnoid space [1]. It accounts for 5% of all stroke cases and a headache is the most common symptom in patients with SAH. In addition, these patients may have at least one more symptom or finding, such as nausea, vomiting, neck stiffness, photophobia, short-term loss of consciousness, or focal neurological deficit. 74% of patients with SAH have a headache, 77% have nausea and vomiting, 53% have a short-term loss of consciousness and 35% have neck stiffness [2]. While 10 to 15% of patients die before reaching the hospital, 30% of SAH patients who are able to apply to any health institution die within the following year [3].

The most significant complication after SAH is vasospasm [4]. The blood accumulating in the subarachnoid space after SAH causes some chemical changes, which result in smooth muscle contraction in the tunica media layer of the vessel wall and ultimately, pathological narrowing. This is called vasospasm and it develops within a few weeks after bleeding [5]. While vasospasm is concentrated near the bleeding site, it is seen in varying degrees in adjacent vascular structures [4]. Vasospasm is thought to be one of the most important causes of mortality and morbidity in SAH and while it is seen in 30 or 70% of patients after SAH, it can increase the risk of ischemia and infarction up to 36%. Vasospasm due to SAH also worsens the impaired blood flow, leading to ischemia [6].

Although the cause of vasospasm developing after SAH has not been fully understood yet, complex and multifactorial factors such as inflammation, altered vascular resistance, impaired autoregulation, micro thromboembolism and undeveloped collateral anatomy as well as genetic effects, are blamed in the etiology [7]. It is thought that spasmogens that occur with the destruction of thrombocytes and especially erythrocytes leaking out of the vein after SAH, cause vasospasm. These spasmogens include oxyhemoglobin, reactive oxygen species (ROS), thromboxane-A<sub>2</sub> (TxA<sub>2</sub>), endothelin-1 (ET-1), angiotensin and catecholamines [7, 8].

MicroRNAs (miRNAs) are a family of small non-coding RNAs that are important regulators of gene expression [9]. These molecules are composed of 21 to 22 nucleotides that regulate the stability or translational efficiency of targeted mRNAs [10]. Studies have shown its effects in many pathological conditions [11-12-13-14]. miRNA-17 and miRNA-20 are miRNAs belonging to the miRNAs-17-92 group [13]. miRNA-17 and miRNA-20 appear to play a role in many aspects of the central nervous system (CNS) [14].

Melatonin is a hormone produced by the pineal gland and its production occurs in the dark phase and is acutely suppressed by light [15]. Melatonin is known to have an antioxidant effect that reduces ROS production in cells. Many studies have benefited from this therapeutic effect of melatonin in many pathological conditions, including neurodegenerative diseases [16]. In addition, studies are showing that melatonin has antiapoptotic, anti-inflammatory and antioxidant effects in the treatment of SAH [17, 18].

Our study aimed to investigate the effects of melatonin and miRNA-17/20 administration on vasospasm and vascular damage on the basillary artery, in the SAH model created in rats.

## MATERIALS AND METHODS

### Trial design

The tissues used in this study are the tissues obtained from the study titled "Examination of the protective effects of melatonin and miR17/20 administration on acute brain damage in rats with experimental subarachnoid hemorrhage model", which was approved by the Animal Experiments Local Ethics Committee of Çanakkale Onsekiz Mart University, with the decision number 2019/03-05. Before the study started, an application was made to the Animal Experiments Local Ethics Committee of Çanakkale Onsekiz Mart University and approval was obtained with the number 38285931-604.02.04-E.2000074137 dated 12/06/2020. Animal procedures were performed according to the "Guide for the Care and Use of Laboratory Animals" principles [19].

All steps of the study were conducted at the Çanakkale Onsekiz Mart University Experimental

Animals Research Center, open for supervision. In this study, 36 Wistar albino male rats (aged 3-4 months, weight 250-350 grams) were used. The rats were obtained from the Çanakkale Onsekiz Mart University Experimental Research Center. All rats were housed in pairs in appropriate cages in an animal room maintained at a standard humidity (35%-50%) and temperature of  $24 \pm 1$  °C, with 12 hours of light and 12 hours of darkness, and were fed with standard food and water ad libitum.

#### Experimental Groups and Surgical Procedure

The thirty-six (36) rats used in the study were randomly divided into 6 groups.

Group 1: Sham (n=6)

Group 2: SAH (n=6)

Group 3: SAH+Negative control miRNA group (SAH+NegmiRNA) (n=6)

Group 4: SAH+Melatonin (SAH+MEL) group(n=6)

Group 5: SAH-miRs-17/20 group (n=6)

Group 6: SAH+MEL+miRs-17/20 group (n=6)

#### SAH Operation

In our study, the pre-chiasmatic SAH model was used as previously described in the literature [20]. In animals administered general anesthesia with intramuscular Ketamine hydrochloride (60 mg/kg) and xylazine hydrochloride (5 mg/kg), the skin was opened with a vertical incision in the anterior region of the head, and the bone was reached. A 1.5-mm diameter hole was drilled 7.5 mm forward from the bregma and 2 mm to the right of the sagittal line. By using a 30-degree posterior sagittal angle, the anterior bone base was reached 2-3 mm in front of the chiasm. After the incision, 120 µL of fresh non-heparinized autologous arterial blood collected from the tail artery was slowly injected into the pre-chiasmatic cistern for 10 seconds under aseptic conditions. Unlike the original model, arterial blood collected through an open incision from the tail artery was used instead of tail venous blood. A 30G injector is used for arterial blood injection: 0,5 mL of blood was injected. After the surgical procedure was completed, the hole was closed with bone wax. In the sham group, the pre-chiasmatic cistern was

entered using a 30G needle tip and after waiting 10 seconds (sec), the injector was removed without giving any fluid. The process was carried out at  $37^{\circ}\text{C} \pm 0.5^{\circ}\text{C}$  using a heating pad. In conclusion, all steps in the Sham group were the same as in the SAH group, except for blood injection.

In the SAH+NegmiRs-17/20 group, miRs-17/20 miRNA Mimic Negative Control#1 (200 pmol) was divided equally into both nostrils 1 hour after the SAH operation. During this application, the rats were anesthetized with 3% isoflurane. In the SAH+MEL group, 10 mg/kg melatonin was administered intraperitoneally 1 hour after the SAH operation. Mimic-miR-17 (200 pmol) and mimic-miR-20 (200 pmol) were administered intranasally to rats in the SAH-miRs-17/20 group 1 hour after the SAH operation. In the SAH+MEL+miRs-17/20 group, intranasal mimic-miR-17 (200 pmol) and mimic-miR-20 (200 pmol) and intraperitoneal melatonin (10 mg/kg) were administered 1 hour after the SAH operation.

#### Intranasal miRNA Administration

rho-miR-20b-5p mimic (miR-20) (miRBase Accession: MIMAT0003211/5 'C A A G U G C U C A U A G U G C A G G U A G / miRVana® miRNA mimic, Thermo Fisher Scientific, USA), rho-miR-17-1-3p mimic (miR-17) (miRBase Accession: MIMAT0004710/5 'ACUGCAGUGAAGGCACUUGUGG/miRVana® miRNA mimic, Thermo Fisher Scientific), and miRs-17/20 miRNA Mimic Negative Control #1 (Thermo Fisher Scientific) were dissolved in nuclease-free water and 200 pmol doses were prepared. A 10-µL liquid solution prepared for each miRNA was applied to the nostril via a soft pipette tip attached to a micropipette. The solution containing miR-17 was administered to the left nostril, and the solution containing miR-20 was administered to the right nostril. Both miRNAs were obtained and stored under cold chain conditions throughout the entire experimental procedure. To prevent nasal irritation and to obtain sufficient time for the given fluid to reach the brain, miRNA application was performed under 3% isoflurane anesthesia. The rats were kept in the supine position for 3 minutes after the application.

### Melatonin Preparation and Application

Melatonin (N-acetyl-5-methoxytryptamine; product code: M5250-1G; Sigma-Aldrich, St. Louis, MO, USA) was dissolved in absolute ethanol (Absolute GR for analysis, MERCK, Germany) and further diluted in saline to achieve a final concentration of 2.4% (v/v) ethanol. The final solution was injected IP (10 mg/kg) in rats 1 h after SAH.

### Histological Examination

Brain samples, including the bacillary artery, taken from the animals in the experimental groups were immediately placed in 10% neutral buffered formalin for fixation. At the end of the 48-hour fixation period, the tissues were embedded in paraffin blocks after routine dehydration and clearing procedures. Sections of 4 microns taken from the blocks were subjected to routine hematoxylin and eosin (H-E) staining. Afterward, H-E-stained sections were evaluated under a camera-attached light microscope (Olympus CX43) and photographs were taken. The evaluation of the sections was made according to the criteria of vasospasm, edema in the tunica media and folding of the lamina elastica interna, as previously described [21]. Post-assessment grading was also done as previously stated in the literature [22]:

no visible change=1,

minimal change=2,

moderate change=3, and

severe change=4 points.

### Statistical analysis

The data obtained from the evaluations were compared using the IBM SPSS Statistics package program version 25 and the values with  $p < 0.05$  were considered significant. The t-test was used for the independent variables in the comparison of the groups.

## RESULTS

Vessel sections taken from the rats were stained with H-E and light microscopic evaluation was performed on the criteria of vasospasm, edema in the tunica media, and folding of the lamina

elastica interna. According to the evaluation made for vasospasm criteria: a significant increase was observed in all groups compared to the Sham group (The p values for groups 2, 3, 4, 5, and 6 are 0.00, 0.001, 0.008, 0.016, 0.022, respectively). When the SAH group was compared with the SAH+NegmiRs group, vasospasm values were found to be similar ( $p=0.11$ ). Although the mean of the SAH+Mel and SAH+miRs-17/20 groups were lower than the SAH group, no statistically significant difference was found (p values of 0.111 and 0.065, respectively). A significant decrease in vasospasm values was observed in the SAH+Mel+miRs-17/20 group compared to the SAH group ( $p=0.001$ ). No significant difference was found in other group comparisons.

In the evaluation made for assessment of edema in the tunica media, which is the middle layer of the vessel wall: significant increases were observed in the SAH, SAH+NegmiRs, SAH+MEL, SAH-miRs-17/20 groups compared to the Sham group (p values were 0.00, 0.00, 0.00, 0.004, respectively). However, when the Sham group and the SAH+Mel+miRs-17/20 group were compared, these two groups were found to be similar ( $p=0.111$ ). Significant reductions were observed in the SAH+miRs-17/20 and SAH+Mel+miRs-17/20 groups compared to the SAH group (p values 0.002 and 0.006, respectively). It was observed that the amount of edema in the tunica media was significantly decreased in the SAH+miRs-17/20 and SAH+Mel+miRs-17/20 groups compared to the SAH+Mel group (p values 0.044 and 0.041, respectively). No significant difference was found in other group comparisons.

In the evaluation made according to the folding of lamina elastica interna (LEI) criteria in the vessel wall: LEI values were significantly increased in the SAH group ( $p=0.00$ ) and SAH+NegmiRs group ( $p=0.001$ ) compared to the Sham group. Results for the Sham group and the SAH+Mel and SAH+miRs-17/20 groups were similar (p values 0.296 and 0.096, respectively). A significant increase was found in the SAH+Mel+miRs-17/20 group compared to the Sham group ( $p=0.007$ ). LEI was significantly decreased in the SAH+Mel, SAH+miRs-17/20, and SAH+Mel+miRs-17/20 groups compared to the SAH group (p values 0.017, 0.049, and 0.03, respectively). When the



SAH+NegmiRs group was compared with the SAH+Mel and SAH+Mel+miRs-17/20 groups, a significant decrease was observed in these groups compared to the SAH+NegmiRs group (p values 0.025 and 0.049, respectively). No significant difference was observed in other group comparisons.

The light microscopic micrographs belong to experimental groups can be seen in Figure 1. Folding of lamina elastica interna of vessel section from SAH group can be seen in Figure 2. The mean and the standard deviations of the groups can be seen in Table 1.

Table 1: The mean values and the standard deviations of the groups

Groups	Vasospasm (Mean±SD)	Edema in the Tunica Media (Mean±SD)	Folding of the Lamina Elastica Interna (Mean±SD)
Sham (n=6)	0.16±0.40	0.00±0.00	0.33±0.51
SAH (n=6)	2.5±0.54	2.66±0.51	2.33±0.81
SAH+NegmiRNA (n=6)	1.83±0.71	1.83±0.75	2.16±0.75
SAH+MEL (n=6)	1.66±1.03	2.16±0.75	0.83±0.98
SAH-miRs-17/20 (n=6)	1.50±1.04	1.16±0.75	1.16±0.98
SAH+MEL+ miRs-17/20 (n=6)	1.00±0.63	0.83±1.16	1.33±0.51

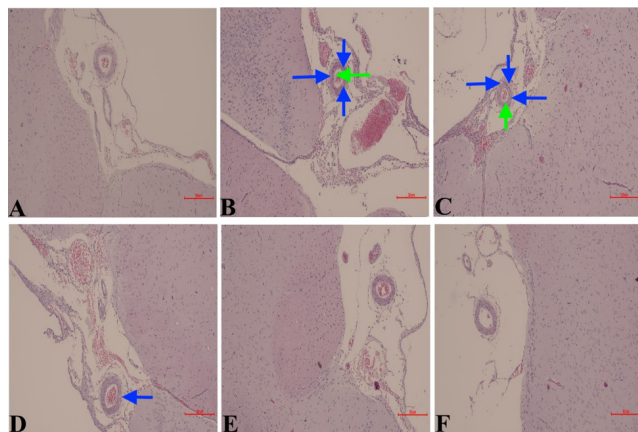


Figure 1. Light microscopic micrographs of H-E-stained sections of experimental groups. A, B, C, D, E, and F belong to Sham, SAH, SAH+NegmiRNA, SAH+MEL, SAH+miRs-17/20, and SAH+MEL+ miRs-17/20 groups, respectively. Green arrows mark the vasospasm areas and blue arrows mark the edema areas in tunica media (Magnification, x100).

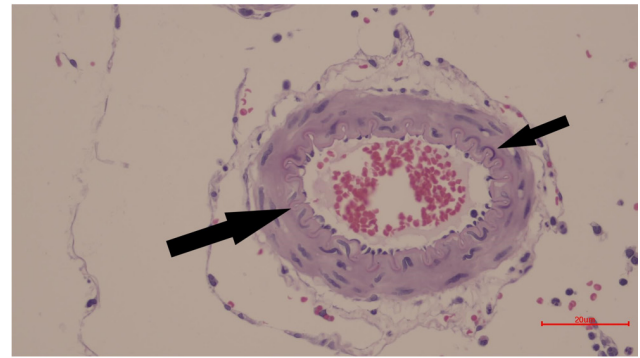


Figure 2: Light microscopic micrograph of H-E-stained section of SAH group. Black arrows mark the folding of lamina elastica interna of the vessel (Magnification, x400)

## DISCUSSION

In our study, histopathological evaluations were made in rats for which the SAH model was created, and it was shown that the co-administration of melatonin and miRs-17/20 after the SAH model, significantly reduced the vasospasm and related edema formation in the vessel wall. It was also demonstrated that the application of miRs-17/20 after SAH alone reduces the development of edema in the vessel wall and folding of the internal lamina elastica, due to vasospasm.

SAH is a neurological emergency caused by the extravasation of blood into the subarachnoid space [1]. Although mortality has decreased in recent years, its morbidity is still high [23]. Patients often face permanent disability, cognitive impairment and mental problems, such as depression and anxiety [24]. For these reasons, the correct planning of SAH treatment without delay may be a factor that increases the patients' quality of life.

The most important complication after SAH is vasospasm [4]. The blood accumulating in the subarachnoid space after SAH causes some chemical changes in this region. These changes result in smooth muscle contraction in the vessel wall and ultimately pathological narrowing. This is called vasospasm [6] and it develops within a few weeks after bleeding. While vasospasm is concentrated near the bleeding site, it is seen in varying degrees in adjacent vascular structures [4]. Vasospasm is thought to be one of the most important causes of mortality and morbidity in SAH. While it is encountered in 30 to 70% of patients after SAH, it can increase the risk of ischemia and infarction up to 36%. This vasospasm, which

develops because of SAH, worsens the impaired blood flow and leads to ischemia [6]. As a result, neuron damage and loss occurs and accordingly, various complications develop. For these reasons, the treatment of vasospasm after SAH may be important in improving the quality of life of patients with SAH.

Melatonin is a hormone produced by the pineal gland, its production occurs in the dark phase and it is acutely suppressed by light [15]. Positive effects have been shown in the treatment of many diseases, and studies are showing that melatonin has antiapoptotic, anti-inflammatory and antioxidant effects, especially in the treatment of SAH [25]. Melatonin, which is effective in the treatment of SAH in previous studies, was used alone and together with miR-17/20 in our current study. Accordingly, it was shown that while melatonin alone causes a decrease in the histopathological findings seen in SAH, its effect increases when used together with miR-17/20.

miRNAs are a family of small non-coding RNAs that are important regulators of gene expression [9]. 21 to 22 nucleotide molecules that regulate the stability or translational efficiency of targeted mRNAs [10]. Studies have shown their effects in many pathological conditions [11-12-13-14]. miRNA-17 and miRNA-20 are miRNAs belonging to the miRNAs-17-92 group [13]. miRNA-17 and miRNA-20 appear to play a role in many conditions involving the CNS, such as brain and spinal cord injury [14]. In this study, we investigated the effect of SAH treatment on reducing vasospasm in the basillary artery. It was observed that the mean vasospasm in the miR-17/20 group was decreased, compared to the SAH group. When melatonin was administered in addition to miRs-17/20, significant improvement was observed compared to the SAH group. Decreased vasospasm values may cause a decrease in ischemic brain damage and ultimately an increase in quality of life after SAH.

Edema in the tunica media, which contains the muscle layer in the vessel wall after SAH, is an indicator of vessel damage. In our study, it was shown that the application of miRs-17/20 reduces edema developing after SAH. This decrease was also found to be more significant than the decrease obtained with melatonin. This result

reveals that miRs-17/20 may have a protective effect against vascular damage after SAH. If the edema decreases, the blood flow will increase as the vessel diameter will be wider, and ischemia can be prevented.

The lamina elastica interna (LEI) is a thin elastic membrane located in the vessel wall between the tunica intima and the tunica media. In vasospasm, contraction occurs in the tunica media, the muscle layer in the vessel wall and as a result, folds are seen in the LEI. In our study, the LEI values in the group given miRs-17/20 after SAH were found to be similar to the Sham group. It was shown that miRs-17/20 can reduce the contraction of the vessel wall after SAH.

#### Limitations

In this study, we could only perform the histopathological evaluation but not so other methods, such as immunohistochemical and biochemical ones. In addition, if radiological evaluations, such as cerebral arterial angiography, could be performed, the study's results may be sturdier for demonstrating the protective effect of miR-17/20 on vasospasm. These are our study's limitations.

#### CONCLUSION

miR-17 and miR-20 are miRNAs whose therapeutic effect is focused on in brain injury models. In this study, the effects of miRs-17/20 and melatonin against vasospasm and vascular damage in the basilar artery in rats with the SAH model, were investigated. In conclusion, it was shown that miRs-17/20 can reduce vasospasm in the vessel wall and prevent vessel damage by reducing edema.

**Conflict of Interest:** The authors declare no conflict of interest related to this article.

**Funding sources:** The authors declare that this study has received no financial support

**Ethics Committee Approval:** This study was approved by Çanakkale Onsekiz Mart University Animal Studies Local Ethics Committee, 12.06.2020 and 38285931-604.02.04-E.2000074137 number

**ORCID and Author contribution:** B.B.(0000-0003-

**1817-2241) and U.A.M.(0000-0002-1272-9654):**  
**Concept and Design, Data collection, Literature**  
**search, Analysis and Interpretation, Manuscript**  
**Writing, Critical Review.**

**Peer-review:** Externally peer reviewed.

**Acknowledgement:** No acknowledgement

#### REFERENCES

1. Suarez JI, Bershad EM. Aneurysmal subarachnoid hemorrhage. *Stroke (Pathophysiology, Diagnosis, and Management)*. Editor: James C. Grotta, Gregory W. Albers, 6th edition. Science Direct. 2016;516-36. doi: 10.1016/B978-0-323-29544-4.00029-3.
2. Connolly ES, Rabinstein AA, Carhuapoma JR, Derdeyn CP, Dion J, Higashida RD, et al. Guideline for healthcare professionals from the American Heart Association/American Stroke Association. *Stroke*. 2012;43(6):1711-37. doi: 10.1161/STR.0b013e3182587839.
3. Lovelock CE, Rinkel GJ, Rothwell PM. Time trends in outcome of subarachnoid hemorrhage: Population-based study and systematic review. *Neurology*. 2010;74(19):1494-1501 doi: 10.1212/WNL.0b013e3181dd42b3.
4. Pluta RM, Hansen-Schwartz J, Dreier J, Vajkoczy P, Macdonald RL, Nishizawa Z, et al. Cerebral vasospasm following subarachnoid hemorrhage: time for a new world of thought. *Neurol Res*. 2009;31(2):151-8. doi: 10.1179/174313209X393564.
5. Barker FG, Heros RC. Clinical aspects of vasospasm. *Neurosurg Clin N Am*. 1990;1(2):277-288. PMID: 2136141
6. Wang Y, Liu Y, Li Y, Liu B, Wu P, Xu S, et al. Protective effects of astaxanthin on subarachnoid hemorrhage-induced early brain injury: Reduction of cerebral vasospasm and improvement of neuron survival and mitochondrial function. *Acta Histochem*. 2019;121(1):56-63. doi: 10.1016/j.acthis.2018.10.014.
7. Baggott CD, Aagaard-Kienitz B. Cerebral Vasospasm. *Neurosurg Clin N Am*. 2014;25(3):497-528. doi: 10.1016/j.nec.2014.04.008.
8. Pluta RM, Afshar JKB, Boock RJ, Oldfield EH. Temporal changes in perivascular concentrations of oxyhemoglobin, deoxyhemoglobin, and methemoglobin after subarachnoid hemorrhage. *J Neurosurg*. 1998;88(3):557-561. doi: 10.3171/jns.1998.88.3.0557.
9. Bartel DB. MicroRNAs: Genomics, biogenesis, mechanism, and function. *Cell*. 2004;116(2): 281-297. doi: 10.1016/S0092-8674(04)00045-5.
10. Yu Z, Wang C, Wang M, Li Z, Casimiro MC, Liu M, et al. A cyclin D1/microRNA 17/20 regulatory feedback loop in control of breast cancer cell proliferation. *J Cell Biol*. 2008;182(3):509-17. doi: 10.1083/jcb.200801079.
11. Sonkoly E, Pivarcsi A. microRNAs in inflammation. *Int Rev Immunol*. 2009;28(6):535-61. doi: 10.3109/08830180903208303.
12. Gupta P, Bhattacharjee S, Sharma AR, Sharma G, Lee SS, Chakraborty C. miRNAs in Alzheimer Disease. A Therapeutic Perspective. *Curr Alzheimer Res*. 2017;14(11):1198-1206. doi: 10.2174/1567205014666170829101016.
13. Mogilyansky E, Rigoutsos I. The miR-17/92 cluster: a comprehensive update on its genomics, genetics, functions and increasingly important and numerous roles in health and disease. *Cell Death Differ*. 2013;20:1603-14. doi: 10.1038/cdd.2013.125.
14. Liu NK, Wang XF, Lu QB, Xu XM: Altered microRNA expression following traumatic spinal cord injury. *Exp Neurol*. 2009;219(2):424-29. doi: 10.1016/j.expneurol.2009.06.015.
15. Pandi-Perumal SR, Trakht I, Srinivasan V, Spence DW, Maestroni GJ, Zisapel N, et al. Physiological effects of melatonin: role of melatonin receptors and signal transduction pathways. *Prog Neurobiol*. 2008;85(3):335-53. doi: 10.1016/j.pneurobio.2008.04.001.
16. Cardinali D. P. Melatonin: clinical perspectives in neurodegeneration. *Front Endocrinol (Lausanne)*. 2019;10:480. doi: 10.3389/fendo.2019.00480.
17. Ding K, Xu J, Wang H, Zhang L, Wu Y, Li T. Melatonin protects the brain from apoptosis by enhancement of autophagy after traumatic brain injury in mice. *Neurochem Int*. 2015;91:46-54. doi: 10.1016/j.neuint.2015.10.008.
18. Tsai MC, Chen WJ, Tsai MS, Ching CH, Chuang JI. Melatonin attenuates brain contusion-induced oxidative insult, inactivation of signal transducers and activators of transcription 1, and upregulation of suppressor of cytokine signaling-3 in rats. *J Pineal Res*. 2011;51(2):233-245. doi: 10.1111/j.1600-079X.2011.00885.x.
19. National Research Council (US) Committee for the Update of the Guide for the Care and Use of Laboratory Animals. *Guide for the Care and Use of Laboratory Animals*. 8th ed. Washington (DC): National Academies Press (US); 2011. doi:10.17226/12910.
20. Prunell GF, Mathiesen T, Svendgaard NA. A new experimental model in rats for study of the pathophysiology of subarachnoid hemorrhage. *Neuroreport*. 2002;13(18):2553-6. doi: 10.1097/00001756-200212200-00034.
21. Pekince A, Kuzeyli K, Çakır E, Usul H, Karaarslan G, Baykal S, et al. Biochemical and histopathological effects of H1 receptor blocker, papaverine and nimodipin in experimental cerebral vasospasm. *J Turkish Cereb Vasc Dis*. 2003;9(1):13-18.
22. Malçok ÜA, Şehitoğlu MH, Büyük B, Sancak EB, Taş Hİ. Protective effect of metformin against lithium-induced cerebral neurotoxicity in rats. *Med Science*. 2021;10(2):350-5 doi: 10.5455/medscience.2020.12.253.
23. Muehlschlegel S. Subarachnoid Hemorrhage. *Continuum (Minneapolis)*. 2018;24(6):1623-57. doi: 10.1212/CON.0000000000000679.
24. Al-Khindi T, Macdonald RL, Schweizer TA. Cognitive and functional outcome after aneurysmal subarachnoid hemorrhage. *Stroke*. 2010;41(8):e519-e536. doi: 10.1161/STROKEAHA.110.581975.
25. Li S, Yang S, Sun B, Hang C. Melatonin attenuates early brain injury after subarachnoid hemorrhage by the JAK-STAT signaling pathway. *Int J Clin Exp Pathol*. 2019;12(3):909-915. PMID: 31933900