

## PAPER DETAILS

TITLE: FLEXIBLE INTRAMEDULLARY NAIL FIXATION IN PEDIATRIC FEMORAL SHAFT FRACTURES

AUTHORS: Sahin ÇEPNI, Ali SAHİN, Özyay SUBAŞI

PAGES: 1-9

ORIGINAL PDF URL: <https://dergipark.org.tr/tr/download/article-file/1435961>



## **FLEXIBLE INTRAMEDULLARY NAIL FIXATION IN PEDIATRIC FEMORAL SHAFT FRACTURES**

**<sup>1</sup>Şahin ÇEPNİ, <sup>1</sup>Ali ŞAHİN, <sup>2</sup>İzzet Özay SUBAŞI**

<sup>1</sup>Ankara City Hospital, Orthopedics and Traumatology, Ankara, Türkiye

<sup>2</sup>Erzincan Binali Yıldırım University, Orthopedics and Traumatology, Erzincan, Türkiye

---

### **Research Article**

Received: 08.12.2020, Accepted: 28.07.2022

\*Corresponding author: ortdrsahin@yahoo.com

---

### **Abstract**

In this study, our aim was to evaluate the functional and radiological results of femoral fractures in children between the ages of 4 and 12 years with intramedullary fixation with an elastic titanium nail in children with femoral shaft fractures. We retrospectively evaluated 26 patients who were treated with intramedullary elastic nail in the orthopedics and traumatology clinic of Erzurum Regional Training and Research Hospital between 2016 and 2018. The mean age of the patients was  $8.4 \pm 2.21$  (4-12 years). Twelve (46.1%) of the fractures were oblique, 9 (34.6%) were transverse and 5 (19.2%) were spiral. The mean follow-up period was  $19.24 \pm 3.84$  (12-32) months. Complete fracture union was found at an average of  $8.20 \pm 2.06$  (5-13) weeks. In the first postoperative year, all patients had full range of hip and knee range of motion, and no angular deformity was detected. Inequality was seen in 4 patients (15.3%) with a leg length of less than 2 cm and in 1 patient (3.8%) more than 2 cm. In our patients, mean varus-valgus angulation of  $7.14 \pm 5.18$  degrees ( $0^\circ - 16^\circ$ ) and sagittal plane angulation of  $3.47 \pm 2.86$  degrees ( $0^\circ - 14^\circ$ ) were observed. Although there are different treatment options for femoral shaft fractures in children between the ages of 4 and 12, we think that fixation with titanium elastic nail should be the first treatment option.

**Key Words:** Femur, Fracture, Pediatric, Titanium Elastic Nails

---

## Özet

Bu çalışmamızda amacımız 4 ile 12 yaş arasındaki femur cisim kırıklı çocuk hastalarda elastik titanyum çivi ile intramedüller tespit uygulanan femur kırıklarının fonksiyonel ve radyolojik sonuçlarını değerlendirmektir. 2016 ile 2018 yılları arasında, femur diafiz kırığı nedeniyle intramedüller elastik çivi ile tedavi edilen 26 hasta incelendi. Hastaların ortalama yaşı  $8,4 \pm 2,21$  (4-12 yaş) olarak tespit edildi. Bütün kırıklar femur diyafizinde idi ve hepsi kapalı kırıktı. Kırıkların 12'si (%46,1) oblik, 9'u (%34,6) transvers, 5'i (%19,2) spiraldi. Ortalama ameliyat süresi  $48,54 \pm 11,24$  (35-80 dk) dakika olarak bulundu. Hastaların ortalama takip süresi  $19,24 \pm 3,84$  (12-32) ay idi. Ortalama  $8,20 \pm 2,06$  (5-13) haftada tam kaynama saptandı. Ortalama  $8,87 \pm 1,7$  (6-13) ayda implantlar çıkartıldı. Ameliyat sonrası birinci yılda tüm hastaların kalça ve diz hareket genişlikleri tamdı ve klinik olarak rotasyonel veya açısal deformite saptanmadı. 5 hastada (%19,2) bacak uzunluğunda 2 cm'den az eşitsizlik görüldü. Hastalarımızda ortalama  $9,14 \pm 5,18$  derecelik ( $0^\circ$ - $18^\circ$ ) varus-valgus açılanması, sagittal plandada ortalama  $3,47 \pm 2,86$  derecelik ( $0^\circ$ - $14^\circ$ ) açılanma görüldü. 4 ile 12 yaş arasındaki çocuklarda femur cisim kırıklarında farklı tedavi seçenekleri olsada titanyum elastik çiviyle tespitin ilk düşünülmesi gereken tedavi seçeneği olması gerektiği görüşündeyiz.

**Anahtar Kelimeler:** Femur, Kırık, Pediatrik, Titanyum Elastik Çiviler

---

## 1. Introduction

Femur diaphyseal fractures are the second leading fractures affecting lower extremities in children and constitute 1.6% of all pediatric fractures (Imam et al., 2018; Hedström et al., 2010). Management of pediatric femoral shaft fractures remains controversial. Age, weight, and fracture pattern are prominent in determining the management approach (Reynolds et al., 2012). The Pavlik harness and hip spica casting are good options for patients aged  $\leq 6$  months. Hip spica casting is superior to other methods for fractures in children below 5 years of age. After 5 years of age, rather than hip spica casting, options like external fixation, open reduction with screw and plate fixation, or internal fixation with flexible nails should be considered (Flynn et al., 2004).

Elastic intramedullary nails have become popular due to being applied with a closed or minimally invasive approach (Uçar et al., 2013; Flinck et al., 2015). In our study, we evaluated the results from patients aged 4-12 years with femoral shaft fractures who were treated with elastic intramedullary nailing.

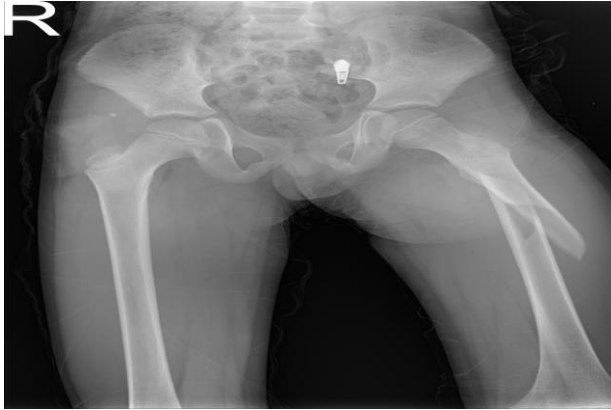## 2. Material and Methods

Approval for the study was granted by the Local Ethics Committee and informed consent was obtained from the patients (Erzurum Training and Research Hospital Ethics Committee, ethics committee number-37732058-514.10). This retrospective study included patients who were admitted to the orthopedics and traumatology clinic of Erzurum Regional Training and Research Hospital between 2016 and 2018 with closed and unstable femoral diaphysis fractures and no other injuries who were treated with intramedullary elastic nailing.

### 2.1. Characteristics of Patients

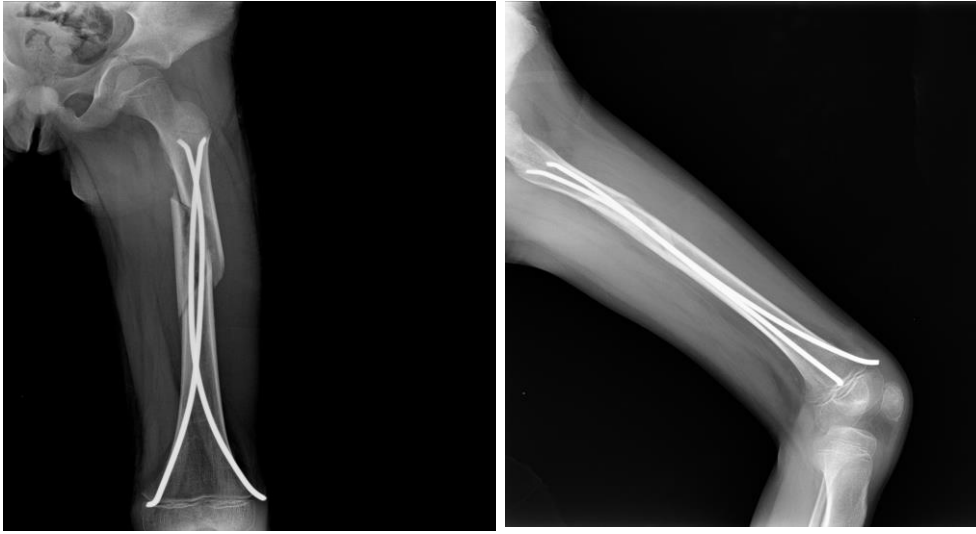
Among the patients, 20 were male and 6 were female. The average age of the patients was 8.4 years (range: 4-12) and the femoral physis was open in all patients. Fourteen patients (54%) had right and 12 (46%) had left femoral fractures. The mechanism of injury was a fall from a height in 9 patients, a traffic accident in 7 patients, and sports activities in 10 patients. Twelve patients (46.1%) had oblique fractures, 9 (34.6%) had transverse, and 5 (19.2%) had spiral. None of the patients had vascular or nerve lesions resulting from femoral shaft fractures.

When the patients were admitted to the emergency department, anteroposterior and lateral radiographs were taken to visualize the fracture line (Figure 1). Immediate hip spica casts were placed in all cases to manage pain and deformities. Skeletal traction was not used for any patients.



**Figure 1.** Radiograph of an 8-year-old male patient who was admitted to our clinic with left femoral shaft fracture after falling from a height

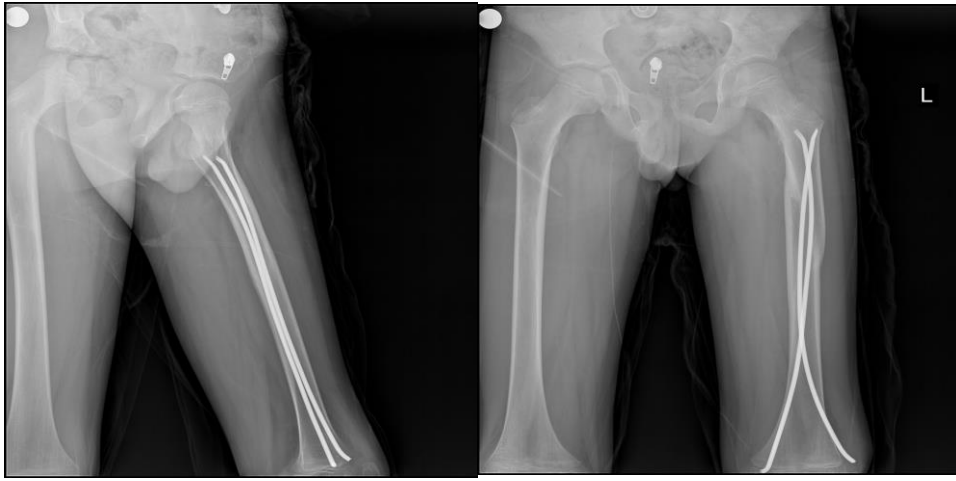
All patients were operated on under general anesthesia in a supine position. A mini-longitudinal incision was made from the medial and lateral sides of the distal femur, 3-3.5 cm proximal to the physis. The bone was reached by blunt dissection. After the entry site was determined under fluoroscopy, a hole was drilled into the bone approximately 2.5-3 cm proximal to the distal physis. The hole was expanded with a scalpel. The femoral medulla was measured pre- and intraoperatively, and nail width was selected to fill at least 2/3 of the femoral medulla. The nails were advanced retrogradely up to the fracture line. In patients for whom closed reduction was not possible, the nails were inserted through a mini-incision and advanced proximal to the fracture line using the blind hand technique. The nails were placed so as not to pass to the proximal side of the epiphyseal plate. After bending, the nails were cut so that a 1-2 cm portion of the distal ends would remain outside the bone, and the operation was concluded (Figure 2). A traction table or tourniquet was not required for any patient. Reduction was achieved in a closed manner in 17 patients (65.4%) and using the blind hand technique in a mini-open manner in 9 (34.6%). Additional external fixation was not performed after the operation, and free movement of the extremity was allowed.



**Figure 2.** Postoperative AP and Lateral radiographs of the patient after closed reduction

After the operation, the extremity was elevated and iced for the first 24-48 hours. Hip and knee range of motion exercises were started on the first day after the operation, and ambulation without weight-bearing was allowed. Partial weight-bearing was allowed at an average of 5.2 weeks (range: 3-8) and full weight-bearing at an average of 7.2 weeks (range: 4-12).

Final follow-ups evaluated fracture healing, functional status, and complications such as malunion or angular deformities, length discrepancy, and infection. Fracture union was determined by the patient's ability to give full weight-bearing to the leg without pain and the appearance of callus formation in at least three cortices on X-ray images (Figure 3). Functional examination included the assessment of muscle strength and range of motion. Sagittal and coronal angles were determined on anteroposterior and lateral follow-up X-rays. Leg length discrepancy was assessed using comparative femoral X-rays taken after fracture union.



**Figure 3.** Anteroposterior and lateral radiographs taken 4 months after the operation

### 3. Results and Discussion

The results were excellent in 18 fractures (69.2%), satisfactory in 7 fractures (26.9%), and poor in one fracture (3.8%) as evaluated using the scoring criteria described by Flynn et al. (Flynn JM et al.,2004)

The mean follow-up period was 19 months (range: 12-32). Fracture union was achieved at an average of  $8.20 \pm 2.06$  weeks (range: 5-13). Implants were removed at an average of  $8.87 \pm 1.7$  months (range: 6-13). Two patients (7.6%) developed infection at the nail insertion site and were

treated with wound debridement and antibiotic therapy. In the first postoperative year, all patients had full range of motion in the hips and knees, and there were no clinical rotational deformities. Five patients (19.2%) had leg length discrepancy of an average of 0.8 cm (range: 0.4-2.2). The discrepancy was due to shortening in 3 patients and lengthening in 2 patients. Only one patient (3.8%) had shortening of more than 2 cm. In our patients, mean varus-valgus angulation was  $7.14^{\circ} \pm 5.18^{\circ}$  (range:  $0^{\circ}$ - $16^{\circ}$ ) and mean sagittal angulation was  $3.47^{\circ} \pm 2.86^{\circ}$  (range:  $0^{\circ}$ - $14^{\circ}$ ). None of the patients developed complications such as trochanteric apophyseal growth disorder, nonunion, or myositis ossificans.

The choice of treatment for pediatric femoral fractures varies depending on the patient's age, fracture type, type of trauma, and the child's weight (Buckley, 1997). Treatment options include the Pavlik harness, hip spica casting, intramedullary fixation, plate and screw fixation, and external fixation (Buckley et al., 2006). The disadvantages of conservative treatment include prolonged immobilization and difficulties in maintaining fracture reduction. Surgical options have recently become prominent as surgical fixation allows early mobilization and joint movement. A study by Symanovsky et al. did not find complications such as loss of reduction or nonunion in pediatric femoral shaft fractures that were treated with titanium intramedullary nails (Simanovsky et al., 2006). In our study, we similarly found that all fractures healed without union-related complications.

The most common complication after pediatric femoral shaft fractures is leg length discrepancy. This is commonly due to lengthening and is mostly observed in patients aged 2-10 years (Ozturkmen et al., 2002). Heinrich et al. reported that 22% of patients had a lengthening of more than 5 mm and 11% had a shortening of less than 5 mm (Heinrich et al., 1994). In our study, 4 patients (15.3%) had leg length discrepancy of less than 2 cm and 1 patient (3.8%) more than 2 cm.

Another common complication in femoral shaft fractures in children is malunion. Herndon et al. reported that 7 of 24 patients treated with traction and none of 21 patients treated with intramedullary nails developed malunion (Herndon et al., 1989). In their study of antegrade and retrograde titanium intramedullary nail fixation, Galpin et al. also reported excellent angular deformity results in 35 of 37 patients (Galpin et al., 1994). In our study, only 2 (7.6%) femurs had more than  $10^{\circ}$  of varus/valgus or anterior/posterior angulation.

In their review of 79 elastic nailing patients, Narayanan et al. reported discomfort and pain at the nail insertion site in 41 patients, radiological malunion in 8, refracture in 2, transient nerve injury in 2, and superficial wound infection in 2 patients (Narayanan et al., 2004). Multiple studies recommend leaving only a small portion of the nail outside the distal metaphyseal cortex and not bending the nails towards the soft tissue in order to prevent soft tissue irritation (Ligier et al., 1998; Luhmann et al., 2003). In our study, the most common complication was pain and discomfort due to the portion of the nail that was left outside the bone. Two patients (7.6%) treated using thick nails developed infection at the nail insertion site and were treated with wound debridement and antibiotic therapy. The literature also presents studies comparing treatment with plates and treatment with nails (Park et al., 2012; Caglar et al., 2006). Fyodorov et al. reported that internal fixation of femoral diaphyseal fractures with plates among 8- to 12-year-olds had advantages such as anatomical reduction and greater rotational stability compared to intramedullary nails, and disadvantages such as requiring a larger incision and greater soft tissue damage (Fyodorov et al., 1999). In their 1-year follow-up study of 45 patients (22 intramedullary elastic nailing patients, 23 plate fixation patients), Park et al. reported satisfactory results in all patients but stated that nailing was advantageous due to being easier to apply, requiring fewer fluoroscopy images, and allowing early weight-bearing (Park et al., 2012). Çağlar et al. compared plate and nail applications in 40 patients and found earlier union and shorter operative time among patients treated with nailing (Caglar et al., 2006).

#### **4. Conclusion**

We conclude that, although there are different treatment options for femoral shaft fractures in children aged 4-12, we believe that titanium elastic nail fixation should be the first treatment option.

#### **Acknowledgement**

None.

#### **Conflicts of interest**

The authors declare that there are no potential conflicts of interest relevant to this article.



## References

- Buckley SL. Current trends in the treatment of femoral shaft fractures in children and adolescents. *Clin Orthop Relat Res*. 1997;(338):60-73.
- Çaglar O, Aksoy MC, Yazici M, Surat A. Comparison of compression plate and flexible intramedullary nail fixation in pediatric femoral shaft fractures. *J Pediatr Orthop B* 2006;15:210-214.
- Flinck M, von Heideken J, Janarv PM, et al. Biomechanical comparison of semi-rigid pediatric locking nail versus titanium elastic nails in a femur fracture model. *J Child Orthop* 2015;9:77-84
- Flynn JM, Hresko T, Reynolds RA, Blasier RD, Davidson R, Kasser J. Titanium elastic nails for pediatric femur fractures: a multicenter study of early results with analysis of complications. *J Pediatr Orthop* 2001;21:4-8.
- Flynn JM, Schwend RM. Management of pediatric femoral shaft fractures. *J Am Acad Orthop Surg* 2004;12:347-359
- Fyodorov I, Sturm PF, Robertson WW Jr. Compression-plate fixation of femoral shaft fractures in children aged 8 to 12 years. *J Pediatr Orthop* 1999; 19: 578-81
- Galpin RD, Willis RB, Sabano N. Intramedullary nailing of pediatric femoral fractures. *J Pediatr Orthop* 1994;14:184-9.
- Hedström EM, Svensson O, Bergström U, Michno P. Epidemiology of fractures in children and adolescents. *Acta Orthop* 2010;81:148-153.
- Heinrich SD, Drvaric DM, Darr K, MacEwen GD. The operative stabilization of pediatric diaphyseal femur fractures with flexible intramedullary nails: a prospective analysis. *J Pediatr Orthop* 1994;14:501-7.
- Herndon WA, Mahnken RF, Yngve DA, Sullivan JA. Management of femoral shaft fractures in the adolescent. *J Pediatr Orthop* 1989;9:29-32.
- Narayanan UG, Hyman JE, Wainwright AM, Rang M, Alman BA. Complications of elastic stable intramedullary nail fixation of pediatric femoral fractures, and how to avoid them. *J Pediatr Orthop* 2004;24:363-9.
- Ligier JN, Metaizeau JP, Prevot J, Lascombes P. Elastic stable intramedullary nailing of femoral shaft fractures in children. *J Bone Joint Surg [Br]* 1988;70:74-7.
- Luhmann SJ, Schootman M, Schoenecker PL, Dobbs MB, Gordon JE. Complications of titanium 2 elastic nails for pediatric femoral shaft fractures. *J Pediatr Orthop* 2003;23:443-7.
- Imam MA, Negida AS, Elgebaly A, et al.(2018) Titanium Elastic Nails Versus Spica Cast in Pediatric Femoral Shaft Fractures: A Systematic Review and Meta-analysis of 1012 Patients. *Arch Bone Jt Surg*,6(3):176-188.
- Ozturkmen Y, Dogrul C, Balioglu MB, Karli M. Intramedullary stabilization of pediatric diaphyseal femur fractures with elastic Ender nails. [Article in Turkish] *Acta Orthop Traumatol Turc* 2002;36:220-7.

- Park KC, Oh CW, Byun YS, et al. Intramedullary nailing versus submuscular plating in adolescent femoral fracture. *Injury* 2012;43:870-875.
- Poolman RW, Kocher MS, Bhandari M. Pediatric femoral fractures: A systematic review of 2422 cases. *J Orthop Trauma* 2006; 20: 648-54.
- Reynolds RA, Legakis JE, Thomas R, et al. Intramedullary nails for pediatric diaphyseal femur fractures in older, heavier children: early results. *Child Orthop* 2012;6:181- 188.
- Simanovsky N, Porat S, Simanovsky N, Eylon S. Close reduction and intramedullary flexible titanium nails fixation of femoral shaft fractures in children under 5 years of age. *J Pediatr Orthop B*. 2006;15(4):293-7
- Uçar BY, Gem M, Bulut M, et al. Titanium elastic intramedullary nailing: closed or mini-open reduction? *Acta Orthop Belg* 2013;79:406-410.