

PAPER DETAILS

TITLE: Do Choroidal Melanocytes Affect Choroidal Thickness in Patients with Newly Diagnosed Vitiligo?

AUTHORS: Göktug DEMIRCI,Gülsen TÜKENMEZ DEMIRCI,Sevil KARAMAN ERDUR,Cafer TANRIVERDI

PAGES: 404-409

ORIGINAL PDF URL: <https://dergipark.org.tr/tr/download/article-file/2450223>

Do Choroidal Melanocytes Affect Choroidal Thickness in Patients with Newly Diagnosed Vitiligo?

Vitiligo Tanısı Yeni Konulan Hastalarda Koroid Melanositleri Koroid Kalınlıklarının Etkiler mi?

Goktug DEMIRCI¹ , Gulsen TUKENMEZ DEMIRCI² , Sevil KARAMAN ERDUR¹ ,
Cafer TANRIVERDI¹ 

¹Istanbul Medipol University Faculty of Medicine, Department of Ophthalmology, Istanbul, Türkiye

²Istanbul Aydın University Faculty of Medicine, Department of Dermatology, Istanbul, Türkiye

ORCID ID: Goktug Demirci 0000-0002-5079-4713, Gulsen Tukenmez Demirci 0000-0002-9646-0719, Sevil Karaman Erdur 0000-0001-9829-7268, Cafer Tanriverdi 0000-0003-2445-6339

Cite this article as: Demirci G et al. Do choroidal melanocytes affect choroidal thickness in patients with newly diagnosed vitiligo? Med J West Black Sea. 2022;6(3):404-409.

This paper has been presented as a poster at Turkish Ophthalmological Association 52th National Congress Antalya/Turkey.

Corresponding Author

Göktuğ Demirci

E-mail

gdemirci@medipol.edu.tr

Received

28.05.2022

Revision

22.12.2022

Accepted

23.12.2022

ABSTRACT

Aim: Vitiligo is a chronic skin disease and considered to be an autoimmune, neural, and autocytoxic pathophysiology in which mainly the melanocytes in the epidermis are focused and destroyed. Therefore, alterations in the choroid and retinal pigment epithelium are expected, and there are very few publications using modern technology in research of this subject.

This study aimed to examine the optic disc, retinal nerve fiber layer (RNFL), and choroidal thickness in patients with vitiligo by spectral-domain optical coherence tomography (SD-OCT) as a prospective observational study.

Material and Methods: This single-center prospective cross-sectional study included 40 eyes of 40 patients with vitiligo and 42 eyes of 42 healthy individuals. The RNFL thickness, choroidal thickness, and optic disc parameters (rim area, disc area, and cup volume) were compared between the two groups.

Results: The study consisted of 21 female and 19 male in the vitiligo group, and 21 female and 21 male in controls; no difference was found in gender distribution between two groups ($p=0.836$). Vitiligo and control groups had similar optic disc parameters, and RNFL and choroidal thicknesses; so the differences in the mentioned parameters did not differ statistically ($p>0.05$ for all).

Conclusion: Vitiligo patients' optic disc parameters, and RNFL and choroidal thicknesses did not differ from those in healthy individuals. Based on unknown pathogenesis, the melanocytes at the choroidal region may have compensatory mechanisms in vitiligo.

Keywords: Choroid, OCT, Retina, Vitiligo

ÖZ

Amaç: Vitiligo, kronik bir deri hastalığıdır ve esas olarak epidermisteki melanositlerin hedef alındığı ve yok edildiği otoimmün, nöral ve otositotoksik bir patofizyoloji olarak kabul edilir. Bu nedenle koroidde ve retina pigment epitelinde değişiklikler beklenir ve bu konuda modern teknolojiyi kullanan çok az yayın mevcuttur.

Bu çalışmada, prospektif - gözlemsel bir çalışma olarak vitiligolu hastalarda optik disk, retina sinir lifi tabakası (RSLT) ve koroid kalınlığının spektral alan optik koherens tomografi (SD-OCT) ile incelenmesi amaçlandı.



This work is licensed by
Creative Commons Attribution-
NonCommercial 4.0 International (CC)

Gereç ve Yöntemler: Bu çalışmada vitiligolu hastalarda optik disk, retina sinir lifi tabakası (RSLT) ve koroid kalınlığının spektral alan optik koherens tomografi (SD-OCT) ile incelenmesi prospektif gözlemsel bu çalışma amaçlandı. Bu tek merkezli prospektif kesitsel çalışmaya vitiligolu 40 hastanın 40 gözü ve 42 sağlıklı bireyin 42 gözü dahil edildi. RSLT kalınlığı, koroid kalınlığı ve optik disk parametreleri (rim alanı, disk alanı ve cup hacmi) iki grup arasında karşılaştırıldı.

Bulgular: Çalışmaya vitiligo grubunda 21 kadın ve 19 erkek, kontrol grubunda 21 kadın ve 21 erkek; iki grup arasında cinsiyet dağılımı açısından fark bulunmadı ($p=0,836$). Vitiligo ve kontrol gruplarında benzer optik disk parametreleri, RSLT ve koroid kalınlıkları; yani bahsedilen parametrelerdeki farklılıklar istatistiksel olarak farklı değildi (tümü için $p>0.05$).

Sonuç: Vitiligo hastalarının optik disk parametreleri, RSLT ve koroid kalınlıkları sağlıklı bireylerden farklı değildi. Bilinmeyen bir patogeneze bağlı olarak, koroid bölgesindeki melanositlerin vitiligoda kendini telafi edici mekanizmaları olabilir.

Anahtar Sözcükler: Koroid, OCT, Retina, Vitiligo

INTRODUCTION

Vitiligo is a chronic skin disease and considered to be an autoimmune, neural, and autocytoxic pathophysiology in which mainly the melanocytes in the epidermis are focused and destroyed. Both genders are equally affected. It could arise at any age, but 70% of patients are under 30 years of age (1).

Many studies have proven that the loss of melanocytes in vitiligo patients is not restricted to the skin (2-4). In 1983, as first time Albert et al. showed the vitiligo disease also affects retina with hypopigmentation since then eyebrows, eyelashes, iris, ciliary body, and choroid is even thought to be affected (2). Hypopigmentation of iris, lens changes, hypopigmentation in retinal pigment epithelium (RPE), uveitis can also be seen in vitiligo patients (3,4). The stroma layer of the choroid is very rich in melanocytes (5). Therefore, alterations in the choroid and retinal pigment epithelium are expected, and there are very few publications using modern technology in research of this subject (2,6,7).

This study aimed to examine the optic disc, retinal nerve fiber layer (RNFL), and choroidal thickness in patients with vitiligo by spectral-domain optical coherence tomography (SD-OCT).

MATERIAL and METHODS

The study approved by the Istanbul Medipol University Ethics Committee with the protocol number 10840098-604.01.01.E5435- 14.04.2016. The study was conducted by the tenets of the Declaration of Helsinki and written informed consent was obtained from all the participants prior to study initiation. Forty eyes of 40 patients with vitiligo (group 1) and 42 eyes of 42 healthy individuals (group 2) were included in this single-center, cross-sectional observational study. All SD-OCT measurements were performed in both eyes. Because no statistical difference was detected between the two eyes, data of 1 eye were selected randomly. Patients in group 1 were newly diagnosed with vitiligo by a dermatology specialist. Vitiligo was diagnosed by the dermatologist based on depigmentation of skin and enhanced

fluorescence in skin lesions underneath Wood light. The patients were not classified as periorbital, all the patients with vitiligo are included in the study. Subjects with a history of smoking, current or recent use of drugs that could affect choroidal thickness, active ocular infection or allergy, ocular surface scarring, previous ocular surgery, hypertension, known atherosclerotic disease, pregnancy, macular degenerations, choroidal pathology, glaucoma, high refractive error (patients with more than + 6 and -6 diopters), best-corrected visual acuity below 20/25, or patients with a systemic other disease were excluded. Healthy control subjects were routine checkup patients.

They were also examined by a dermatology specialist to exclude vitiligo or any other dermatological disorders.

The Cirrus HD-OCT was used in all subjects' examination. The optic disc cube 200x200 algorithm was used after pupil dilatation. Both eyes of each subject were scanned three times. All scans were obtained in the same session, and the time interval among the scans was within 5 to 10 seconds. The following optic disc parameters were analyzed: Rim area (RA), disc area (DA), and cup volume (CV).

The RNFL measurements were obtained by the RNFL algorithm within the three-dimensional data cube. The optic disc center was found by plotting the central dark point in the RPE. The 512 A-scans of 2-dimensional data were obtained by processing a circle of data with a radius of 1.73 mm from the central dark point via bilinear interpolation and smoothing. The RNFL thickness map was created by measuring the average of these A-scans. The following parameters were analyzed: Thickness central subfield (TCB), volume cube (VC), and thickness average cube (TAC).

From this HD raster scan, two independent graders (G.D., C.T.) manually measured choroidal thickness using software calipers (Figure 1). The foveal center was confirmed by comparing the orientation of the HD scan to the 5-line raster OCT scan. The subfoveal choroidal thickness (SFCT) was defined as the vertical perpendicular distance from the hyper-reflective line of Bruch's membrane to the innermost hyper-reflective line of the choroido-scleral interface. The

measurements were obtained at the fovea and 500 μm nasal and temporal to the fovea. The mean SFCT was calculated by taking the average of these three values.

The exclusion criteria for the HD-OCT scans were: The signal strength lower than six, saccades in the enface image, scans in which the line-scanning laser ophthalmoscope image did not have sharp uniform focus nor had poor centration, non-uniform illumination, or vitreous or media artifacts.

Statistical analysis was performed using SPSS 22.0 software package. The normality of the distribution of each of the parameters was checked using the Kolmogorov-Smirnov normality test. The variables were normally distributed. The student t-test was used to compare the parameters between the two groups. Categorical variables (such as gender dis-

tribution) were compared by Chi-square test. The statistical significance value was accepted as $p < 0.05$.

RESULTS

This study included 40 eyes of 40 patients with vitiligo and 42 eyes of 42 controls. The mean age was 39 ± 15 years in the vitiligo group and 32 ± 14 years in the control group ($p=0.167$). There were 21 females and 19 males in the vitiligo group, and 21 females and 21 males in the control group; no difference was found in gender distribution between the two groups ($p=0.836$). There was no statistical difference between the study and control groups in terms of intraocular pressure, axial length, visual acuity, and refraction error measurement. Table 1 presents the demographic and clinical data of the participants.

Vitiligo and control groups had also similar optic nerve head parameters, and RNFL measurements (Figures 2-4). The optic disc parameters (rim area, cup volume, and disc area) were $1.3 \pm 0.2 \text{ mm}^2$ and $1.3 \pm 0.2 \text{ mm}^2$ ($p=0.491$); $0.1 \pm 0.1 \text{ mm}^3$ and $0.1 \pm 0.1 \text{ mm}^3$ ($p=0.370$); $1.6 \pm 0.1 \text{ mm}^2$ and $1.7 \pm 0.2 \text{ mm}^2$ ($p=0.457$) in the vitiligo group and control group, respectively. The average RNFL thickness ($92 \pm 8 \mu\text{m}$ vs $97 \pm 9 \mu\text{m}$), the central subfield thickness ($252 \pm 22 \mu\text{m}$ vs $254 \pm 13 \mu\text{m}$), the volume cube ($10.2 \pm 0.5 \text{ mm}^3$ vs $10.3 \pm 0.4 \text{ mm}^3$), and the average cube thickness ($282 \pm 14 \text{ mm}^3$ vs $286 \pm 12 \text{ mm}^3$) were similar between the vitiligo and control groups ($p=0.146$,

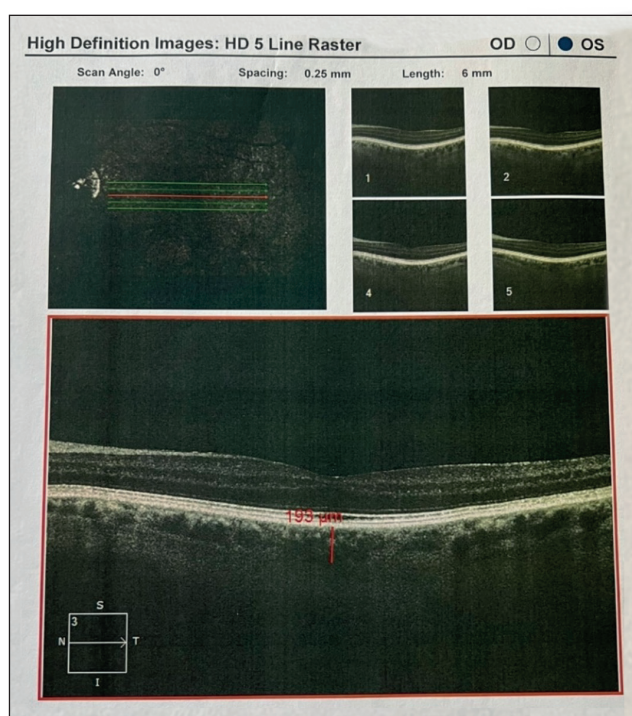


Figure 1: Choroidal thickness OCT image measurement method.

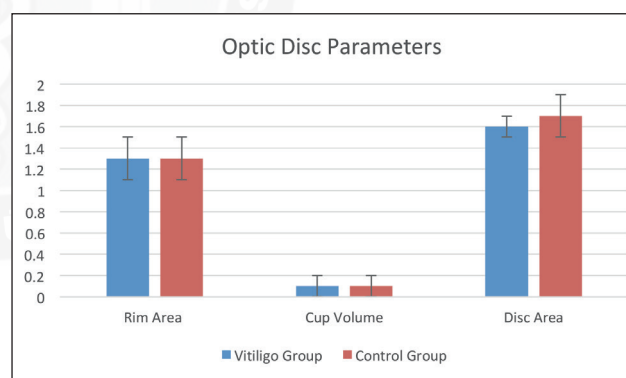


Figure 2: Comparison of rim area, cup volume, disc area.

Table 1: The demographic and clinical data of the study and control groups.

	Study Group (n=40 eyes)	Control Group (n=42 eyes)	p-value
Age (years)	39 ± 15	32 ± 14	0.167*
Gender (F/M)	21/19	21/21	0.836 ^a
IOP (mmHg)	16.52 ± 2.83	16.76 ± 2.07	0.562*
Axial length (mm)	23.47 ± 1.04	23.38 ± 1.12	0.321*
BCVA (Log MAR)	0.08 ± 0.22	0.06 ± 0.40	0.845*
Refractive error (D) (SE)	-0.37 ± 1.00	-0.25 ± 0.92	0.702*

F/M: Female/male, **IOP:** Intraocular Pressure, **BCVA:** Best-corrected visual acuity, **D:** Diopter, **SE:** Spheric equivalent

*Student t-test. ^aChi-square test

$p=0.682$, $p=0.499$, and $p=0.488$; respectively). There was also no significant difference in choroidal thickness between the two groups ($290\pm 67\ \mu\text{m}$ in vitiligo group, $290\pm 25\ \mu\text{m}$ in control group; $p=0.994$). Table 2 shows the outcome measurements.

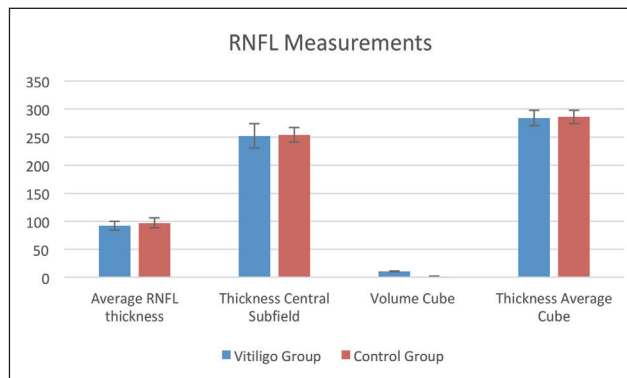


Figure 3: Comparison of average RNFL, thickness center subfield, volume cube, thickness average cube.

DISCUSSION

The most common ocular pathology seen in approximately 30 to 40 percent of vitiligo patients is in the retinal pigment epithelium (RPE) and choroidal layer. Albert et al. showed

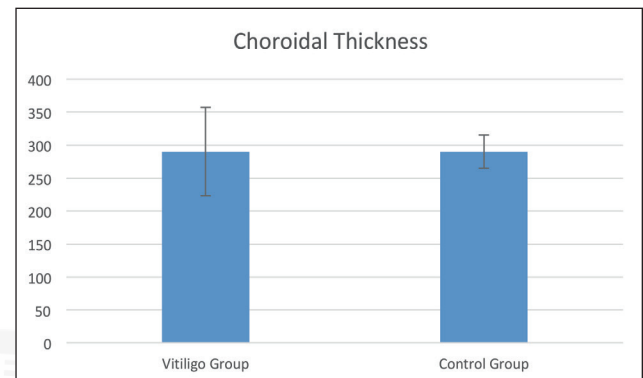


Figure 4: Comparison of vitiligo and study groups choroidal thickness.

Table 2: Optic nerve and RNFL parameters, and choroid thicknesses between two groups.

Parameters	Vitiligo Group (n=40 eyes)	Control Group (n=42 eyes)	p-value*
Optic Disc			
Rim Area (mm ²)			
Mean ± SD	1.3±0.2	1.3±0.2	0.491
Range	(1-1.9)	(0.9-2.1)	
Cup Volume (mm ³)			
Mean ± SD	0.1±0.1	0.1±0.1	0.370
Range	(0-0.3)	(0-0.6)	
Disc Area (mm ²)			
Mean ± SD	1.6±0.1	1.7±0.2	0.457
Range	(1.4-2)	(1.4-2.5)	
RNFL			
Average RNFL thickness (μm)			
Mean ± SD	92±8	97±9	0.146
Range	(79-109)	(81-114)	
Thickness Central Subfield (μm)			
Mean ± SD	252±22	254±13	0.682
Range	(214-292)	(232-276)	
Volume Cube (mm ³)			
Mean ± SD	10.2±0.5	10.3±0.4	0.499
Range	(9.3-11)	(9.5-11)	
Thickness Average Cube (mm ³)			
Mean ± SD	284±14	286±12	0.488
Range	(256-306)	(264-305)	
Choroid			
Choroidal Thickness (μm)			
Mean ± SD	290±67	290±25	0.994
Range	(128-390)	(240-327)	

RNFL: Retinal nerve fiber layer

* Student-t test

that 27% of vitiligo patients had RPE hypopigmentation, and one patient had advanced retinitis pigmentosa-like pattern (2). Conversely, İlhan et al. showed that RPE was not affected (6). Wagoner et al. demonstrated a strong presence of vitiligo with uveitis (8). Nordlund et al. showed that vitiligo and uveitis co-occurrence were more than presumed and suggested that the same immunological mechanism in the skin and skin destroyed pigment cells (9).

Albert et al. showed %5 uveitis cases in vitiligo patients (10). In the SD-OCT and mfERG study, Aydın et al. showed that photoreceptor segments were preserved in SD-OCT and central retinal function loss detected in mfERG (11).

The function of extracutaneous melanocytes has been an exciting topic for researchers. Currently, we know melanocytes produce melanin pigments and store them in melanosomes, so the skin is protected from ultraviolet radiation damage. The primary question is what melanocyte does at extracutaneous locations, such as the inner ear, heart, and leptomeninges, which are self sun-protective areas (12). This situation leads us to think if the melanocytes have other functions besides avoiding the intraocular reflections of the light (5).

In human beings, melanocytes originate from the optic cup and the neural crest. The choroidal stroma contains a large number of melanocytes, which are neural crest-derived cells that migrate during eye development (13). The choroid, the most vascularized eye structure, has approximately seventy percent of the total eye blood flow (14). Melanocytes surround the choroidal blood vessels. Shibuya et al. reported melanocytes play an essential role at morphogenesis and/or upkeep of the normal choroidal vasculature (15). They observed normal RPE but a thinner choroidal layer secondary to lack of melanocytes in melanocyte-deficient *Mitf^{mi-bw}/Mitf^{mi-bw}* mutant mice. Also, they found *Mitf^{mi-bw}/Mitf^{mi-bw}* mice eye had narrower vascular layers than those of wild-type mice eyes. Interestingly, when they performed an animal model using albino mice, they reported larger blood vessels than the control group in choroidal vasculature. Adini et al. found high amounts of fibromodulin and monocyte chemoattractant protein-1 in albino mice (16). Those two factors play a vital role in choroidal angiogenesis. Shibuya et al. concluded the presence or absence of melanocytes might have different effects on choroidal vasculature (15).

When the lesional skin of a vitiligo patient examined histologically and immunohistochemically, mostly no melanocytes are observed, however infrequently melanocytes might be seen (17). The underlying pathology of melanocytes destruction in vitiligo remains unclear, although several theories are suggested (18,19). When it comes to vitiligo classification, we see the term 'vitiligo' is an umbrella, including different pathogenic mechanisms causing the same clinical presentation. There are also unanswered questions about vitiligo assessment and treatment interventions (20).

In the literature, many papers are published about choroidal thickening in several systemic diseases affecting the eye vasculature, but the effect of vitiligo on choroid has not been investigated sufficiently. Ornek N et al. have investigated possible alterations in RNFL thickness in vitiligo patients and found no effect in RNFL thickness in vitiligo patients (21). On the other hand Aydın et al. found a potential loss of central retinal function with multifocal ERG in vitiligo patients but observed that the photoreceptor segment was preserved in OCT (11). They mentioned that patients with vitiligo may have potential changes in central retinal functions even if they have normal OCT findings and fundus appearance. Demirkan et al. showed that in vitiligo patients, the choroidal thickness of the optic nerve and surrounding area was significantly thinner in all regions except the optic nerve and its surrounding area compared to those in healthy subjects (7). Similar to that Öncül H. et al. have shown that the choroidal thickness of vitiligo patients was found out to be thinner compared to the control group (22).

Conversely, we did not find any difference in RNFL thickness, choroidal thickness, and optic disc parameters (rim area, disc area, and cup volume) between the vitiligo group and the control group. We hypothesize the controversies between the studies by Demirkan et al., Öncül H. et al. and our study might depend on the heterogeneity of vitiligo disease itself (7,22). Also, we included patients with vitiligo who were newly diagnosed. It's possible by the time melanocyte loss progress and vitiligo affects choroidal melanocytes. Another possibility is that even if the choroidal melanocytes were affected, some vitiligo patients might have compensated mechanisms to increase fibromodulin and monocyte chemoattractant protein-1 to maintain the normal choroidal vasculature. One of the limitations of this study may be the sample size because sample size calculation was not done but according to our previous studies the sample size is enough to have opinion about the real world effect of vitiligo on choroidal melanocytes. The other limitation of this study may be the patients were not classified as periorbital, all the patients with vitiligo are included in the study. However, because vitiligo is a systemic disease involving all of the body we do not think that this limitation has an effect on the results.

In this study vitiligo patients' optic disc parameters, RNFL and choroidal thicknesses did not differ from those in healthy individuals. Based on unknown pathogenesis, the melanocytes at the choroidal region may have compensatory mechanisms in vitiligo. Longitudinal studies with more distinct methodology may also show whether the results hold true for distributions of the dependent and explanatory variables other than the ones explored here, especially genome-based selections, might be more informative about the relation between vitiligo disease and choroidal structure.

Acknowledgment

None

Author Contributions

Author's contributions are equal.

Conflicts of Interest

The authors have no potential conflicts of interest to the research, authorship and/or publication of this article.

Financial Support

The authors received no financial support for the research, authorship, and/or publication of this article

Ethical Approval

The study approved by the Istanbul Medipol University Ethics Committee with the protocol number 10840098-604.01.01.E5435-14.04.2016. The study was conducted by the tenets of the Declaration of Helsinki and written informed consent was obtained from all the participants prior to study initiation

Review Process

Extremely peer-reviewed.

REFERENCES

1. Alikhan A, Felsten LM, Daly M, Petronic-Rosic V. Vitiligo: a comprehensive overview part I. Introduction, epidemiology, quality of life, diagnosis, differential diagnosis, associations, histopathology, etiology, and work-up. *J Am Acad Dermatol* 2011;65:473-491.
2. Albert DM, Wagoner MD, Pruett RC, Nordlund JJ, Lerner AB. Vitiligo and disorders of the RPE. *Br J Ophthalmol* 1983;67:153-156.
3. Biswas G, Barbhuiya JN, Biswas MC, Islam MN, Dutta S. Clinical pattern of ocular manifestations in vitiligo. *J Indian Med Assoc* 2003;101:478-480.
4. Karadag R, Esmer O, Karadag AS, Bilgili SG, Cakici O, Demircan YT, Bayramlar H. Evaluation of ocular findings in patients with vitiligo. *Int J Dermatol* 2016;55:351-355.
5. Nickla DL, Wallman J. The multifunctional choroid. *Prog Retin Eye Res* 2010;29:144-168.
6. Ilhan N, Rifaioglu EN, Ilhan O, Coskun M, Mutlu Cihan Daglioglu MC, Tuzcu EA, Kahraman H. Retinal Pigment Epithelium Thickness Analysis with Optical Coherence Tomography in Patients with Vitiligo. *Med Sci* 2015;31:587-591.
7. Demirkan S, Onaran Z, Samav G, Özkal F, Yumuşak E, Gündüz Ö, Karabulut A.. Decreased choroidal thickness in vitiligo patients. *BMC Ophthalmol* 2018;18:126.
8. Wagoner MD, Albert DM, Lerner AB. Ocular abnormalities occurring with vitiligo. *Ophthalmol* 1978; 86:1145-1160.
9. Nordlund JJ, Taylor NT, Albert DM, Wagoner MD, Lerner AB. The prevalence of vitiligo and poliosis in patients with uveitis. *J Am Acad Dermatol* 1981;4:528-536.
10. Albert DM. Melanoma, vitiligo, and uveitis. *Ophthalmology* 2010;117:643-644.
11. Aydin R, Ozsutcu M, Erdur SK, Dikkaya F, Balevi A, Ozbek M, Senturk F. The assessment of macular electrophysiology and macular morphology in patients with vitiligo. *Int Ophthalmol* 2018;38:233-239.
12. Plonka PM, Passeron T, Brenner M, Tobin DJ, Shibahara S, Thomas A, Slominski A, Kadekaro AL, Herschkovitz D, Peters E, Nordlund JJ, Abdel-Malek Z, Takeda K, Paus R, Ortonne JP, Hearing VJ, Schallreuter KU. What are melanocytes really doing all day long...? *Exp Dermatol* 2009;18:799-819.
13. Cook CS, Ozanis V, Jakobiec FA. Prenatal development of the eye and its adnexa. In: Tasman W, editor. *Duane's Ophthalmology*. Philadelphia: Lippincott-Raven Publishers, Inc, 1991:1-93.
14. Mrejen S, Spaide RF. Optical coherence tomography: imaging of the choroid and beyond. *Surv Ophthalmol* 2013;58:387-429.
15. Shibuya H, Watanabe R, Maeno A, Ichimura K, Tamura M, Wakana S, Shiroishi T, Ohba K, Takeda K, Tomita H, Shibahara S, Yamamoto H. Melanocytes contribute to the vasculature of the choroid. *Genes Genet Syst* 2018;15:93:51-58.
16. Adini I, Adini A, Bazinet L, Watnick RS, Bielenberg DR, D'Amato RJ. Melanocyte pigmentation inversely correlates with MCP-1 production and angiogenesis-inducing potential. *FASEB J* 2015;29:662-670.
17. Le Poole IC, Das PK, van den Wijngaard RM, Bos JD, Westerhof W. Review of the etiopathomechanism of vitiligo: a convergence theory. *Exp Dermatol* 1993;2:145-153.
18. Sandoval-Cruz M, García-Carrasco M, Sánchez-Porras R, Mendoza-Pinto C, Jiménez-Hernández M, Munguía-Realpozo P, Ruiz-Argüelles A. Immunopathogenesis of vitiligo. *Autoimmun Rev* 2011;10:762-765.
19. Richmond JM, Frisoli ML, Harris JE. Innate immune mechanisms in vitiligo: danger from within. *Curr Opin Immunol* 2013;25:676-682.
20. Whitton ME, Pinart M, Batchelor J, Lushey C, Leonardi-Bee J, González U. Interventions for vitiligo. *Cochrane Database Syst Rev* 2010;1:CD003263.
21. Ornek N, Onaran Z, Koçak M, Ornek K. Retinal nerve fiber layer thickness in vitiligo patients. *J Res Med Sci* 2013;18:405-407.
22. Oncul H, Ayhan E. Retinal nerve fiber layer, retinal pigment epithelium, and choroidal thickness in vitiligo patients. *J Cosmet Dermatol*. 2020;00:1-6.